

Non- Surgical Retreatment

Mostafa El Kholy

Senior Lecturer, School of Dentistry, UWA

- Etiology
- Microbiology
- Diagnosis
- Treatment Plan
- Outcomes

Etiology



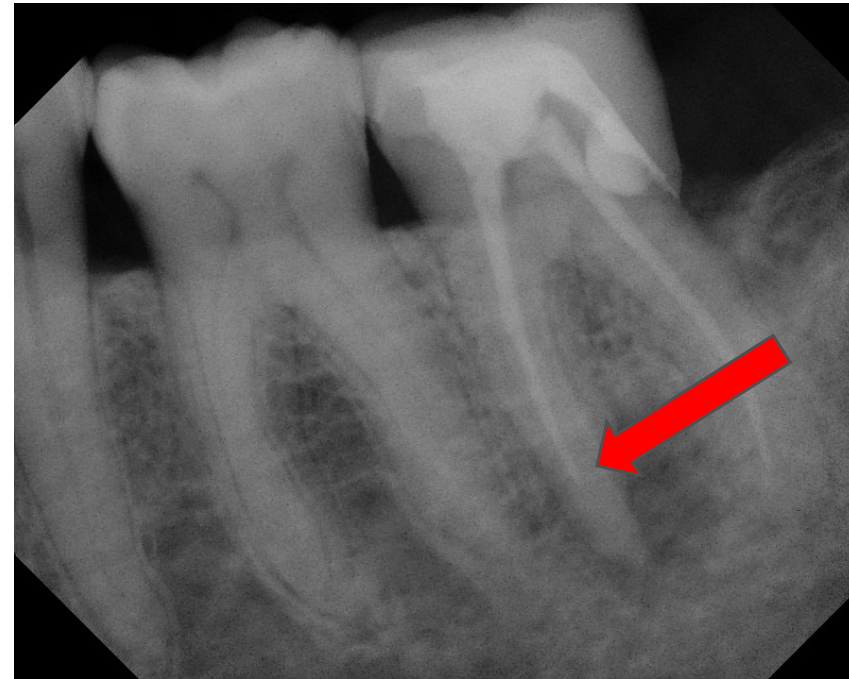
Etiology

Causes of “Failure”

- Poor access cavity design
- Untreated canals
- Canals that are poorly cleaned and obturated
- Complications of instrumentation (ledges, perforations, or separated instruments)
- overextensions of root-filling materials
- Coronal leakage

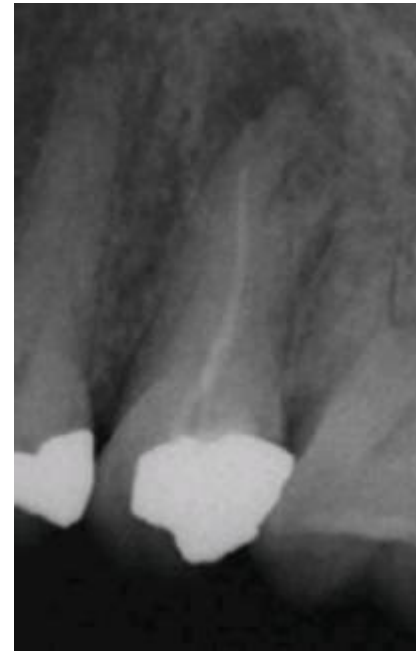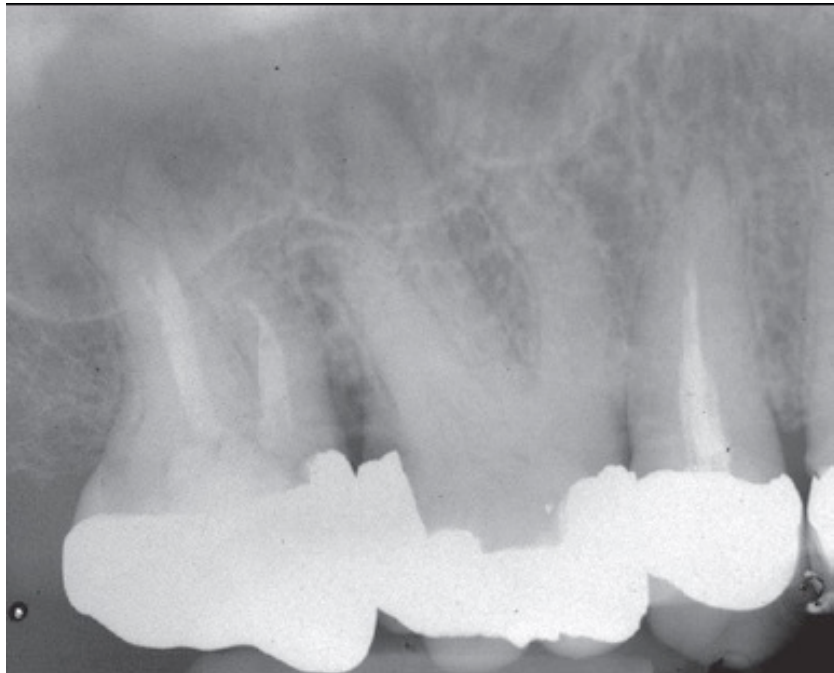
Etiology

Poor Access and untreated canals



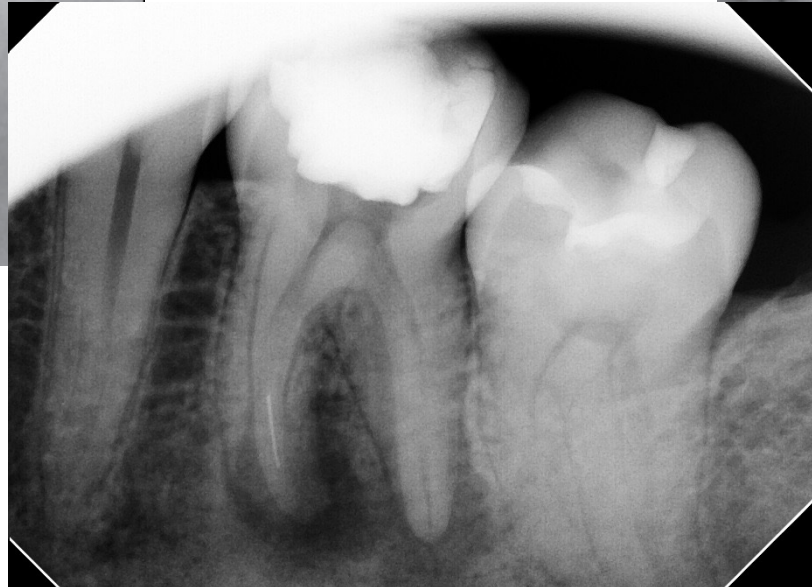
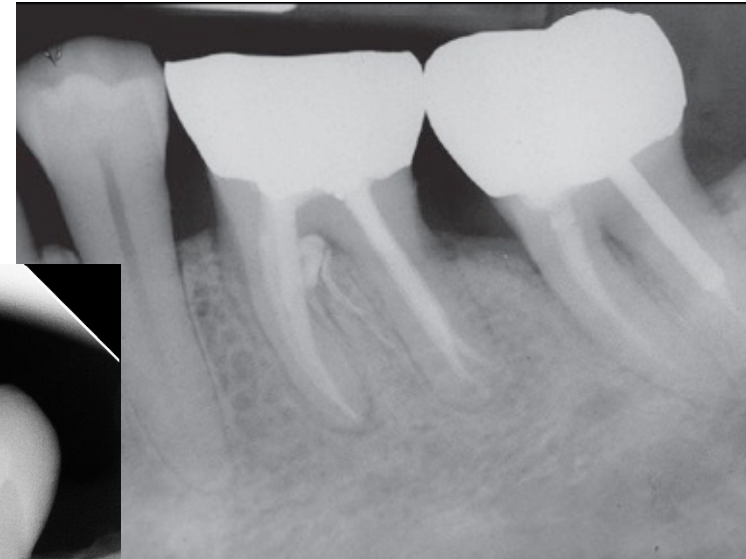
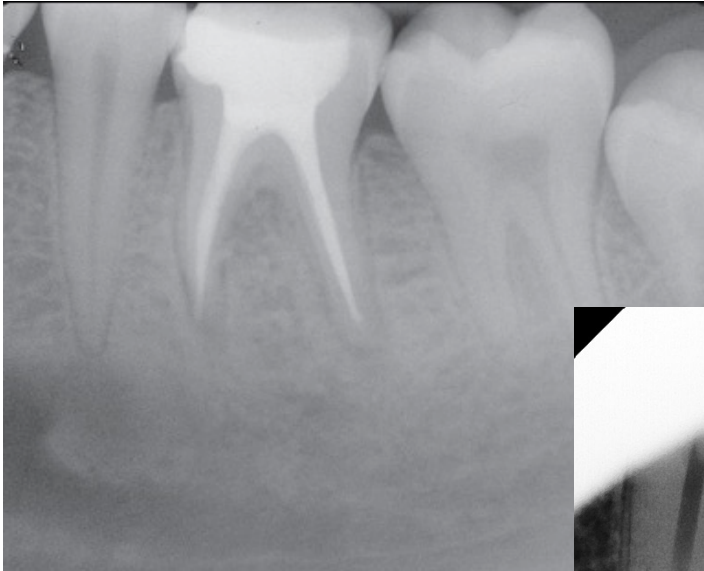
Etiology

Poorly Cleaned and Obturated Canals



Etiology

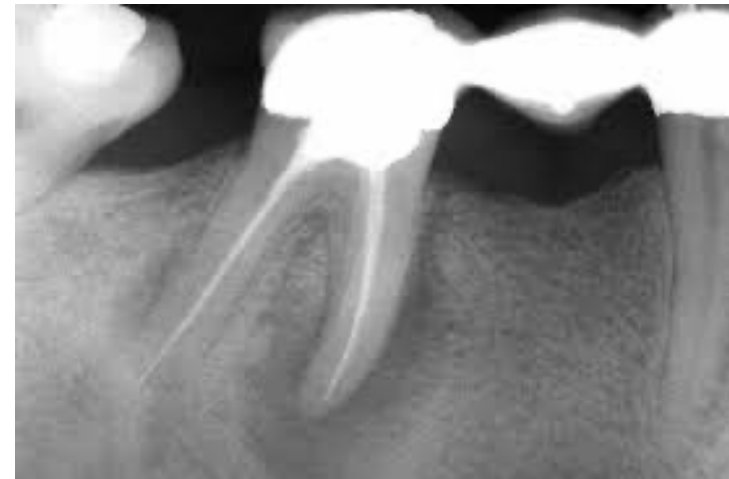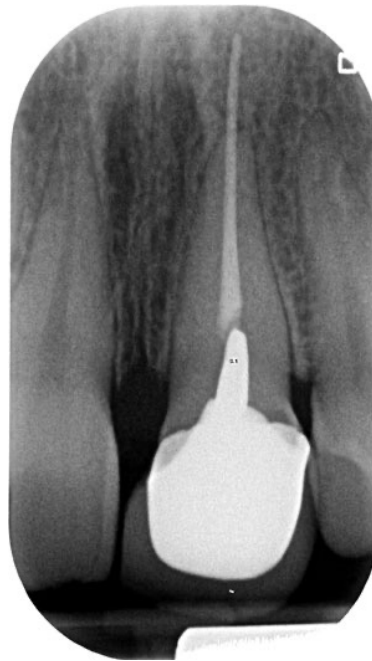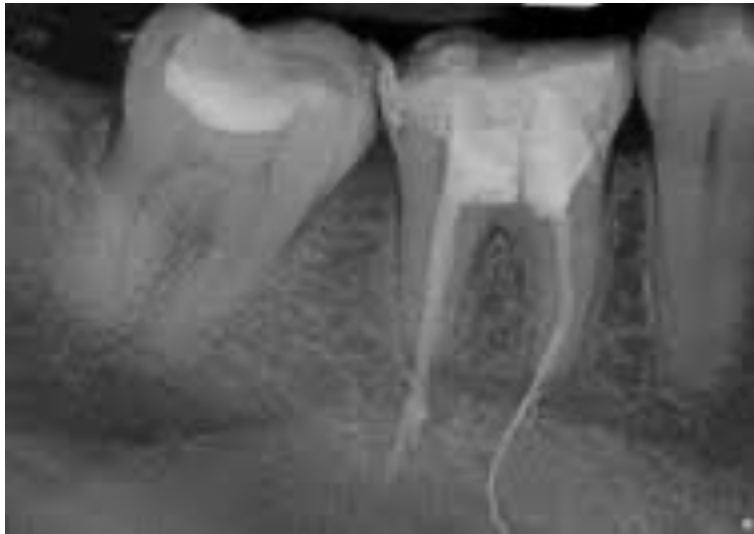Complication of Instrumentation



Sundqvist et al, *Essential endodontology: prevention and treatment of apical periodontitis*, London, 1998, Blackwell Science, p 242.

Etiology

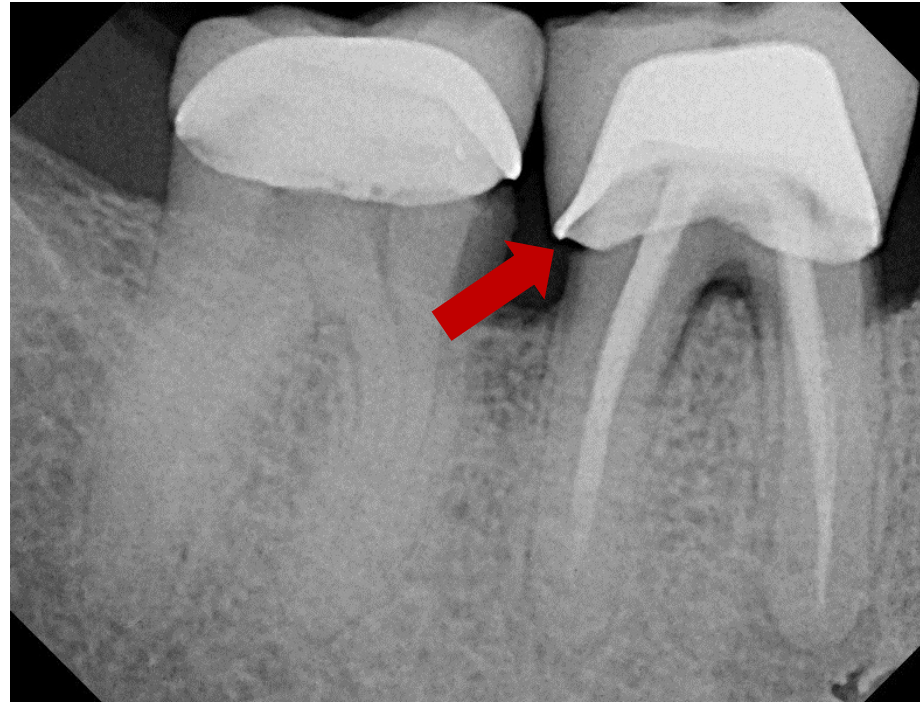
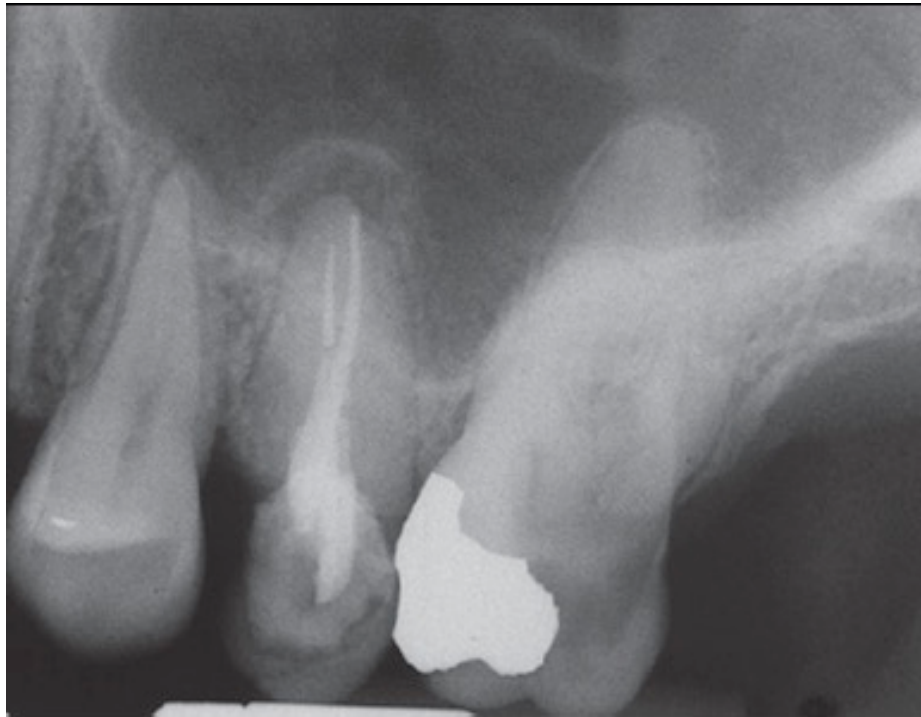
Over-extended Root Canal Filling



Nair et al, J Endod; 1990, 16:589-95

Etiology

Coronal Leakage



- Lazarski et al. J Endod 2001; 27:791-6
- Saunders et al. Endod Dent Traumatol 1994; 10:105-108
- Ray and Trope Int Endod J 1995; 28: 12-18

Table 2. Periradicular status for various combinations of treatment quality

Group	Endo	Coronal	No. teeth	PPI	API	%API
1	Good (GE)	Good (GR)	330.5	28.5	302.0	91.4
2	Good (GE)	Poor (PR)	164.5	92.0	72.5	44.1
3	Poor (PE)	Good (GR)	302.5	98.0	204.5	67.6
4	Poor (PE)	Poor (PR)	188.0	154.0	34.0	18.1

PPI, presence of periradicular inflammation.

API, absence of periradicular inflammation.

Etiology

1. Persistent or reintroduced intraradicular microorganisms
2. Extraradicular infection
3. Foreign body reaction
4. True cysts

Sundqvist G, Figdor D: Endodontic treatment of apical periodontitis. In Orstavik D, Pitt-Ford TR, editors: *Essential endodontology: prevention and treatment of apical periodontitis*, London, 1998, Blackwell Science, p 242

Etiology

Persistent or reintroduced intraradicular microorganisms

- The major cause of posttreatment disease.
- The major cause of posttreatment disease polymicrobial, predominantly anaerobic flora.

Etiology

Extraradicular Infection

- Direct spread of infection from the root canal space via contaminated periodontal pockets that communicate with the apical area.
- Extrusion of infected dentin chips
- Contamination with overextended, infected endodontic instruments.
- By producing an extracellular matrix or protective plaque.

- Weiger *et al*; Endod Dent Traumatol 11:15, 1995
- Holland *et al*; Oral Surg Oral Med Oral Pathol 49:366, 1980
- Tronstad *et al*; Endod Dent Traumatol 6:73, 1990.

Etiology

Foreign Body Reaction

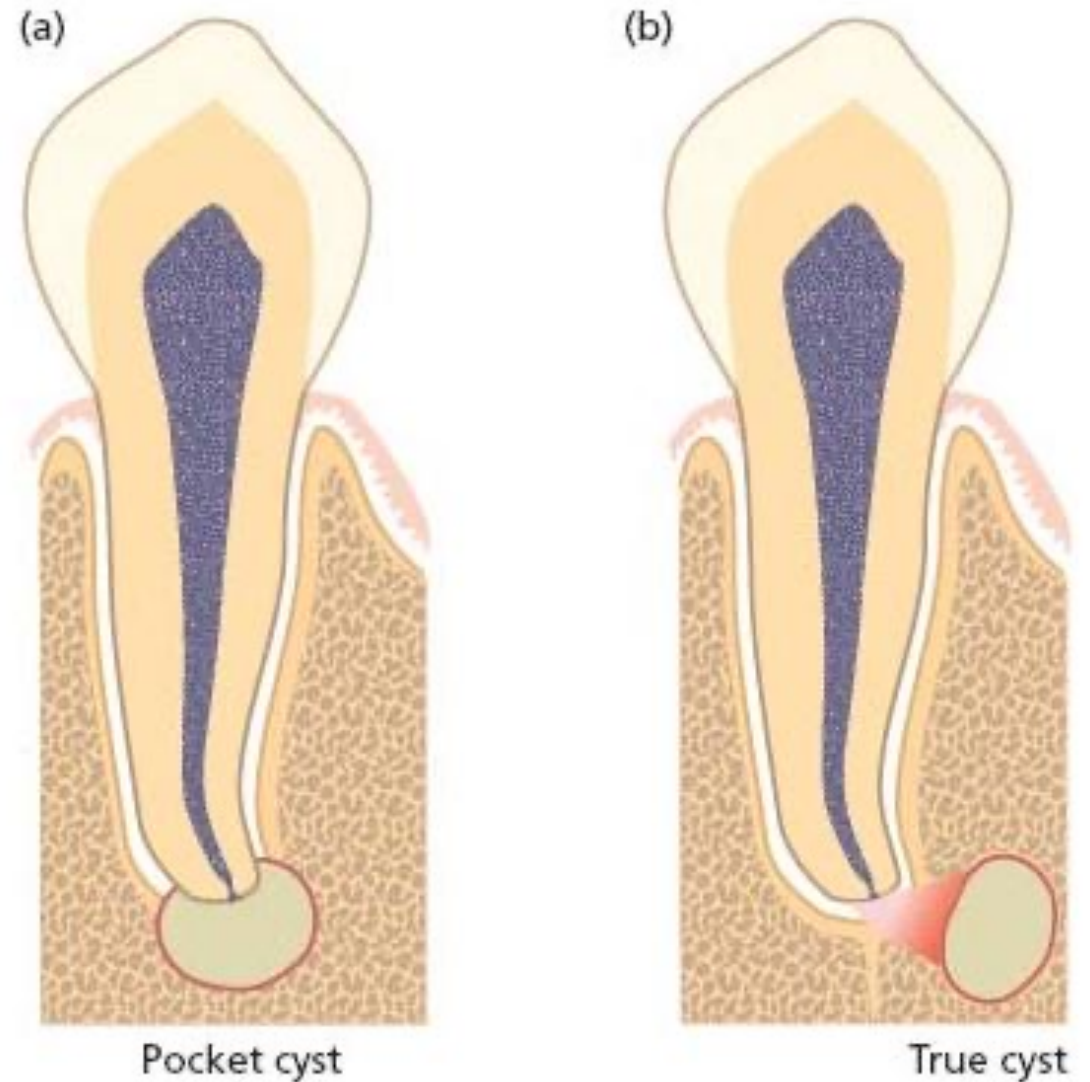
- Oral Pulse Granuloma
- Cellulose Granuloma
- Filling material extrusion leads to a lower incidence of healing

- Simon et al, *J Endod* 8:116, 1982
- Koppang et al, *J Endod* 15:369, 1989
- Sjogren et al, *J Endod* 16:498, 1990

Etiology

True Cyst

- The incidence of periapical cysts has been reported to be 15% to 42% of all periapical lesions.
- There are two types of periapical cysts: the periapical true cyst and the periapical pocket cyst.



Nair : *Int Endod J* 31:155, 1998

Microbiology

- *Enterococcus faecalis*, the root canal survivor and ‘star’ in posttreatment disease.
- *Candida albicans*, are found frequently in persistent endodontic infections and may be responsible for the recalcitrant lesion.
- *Actinomyces israelii* and *Propionibacterium propionicum*, are present in the periapical tissues and may prevent healing after root canal therapy

•Fukushima *et al*, J Endod 1990; 534-8

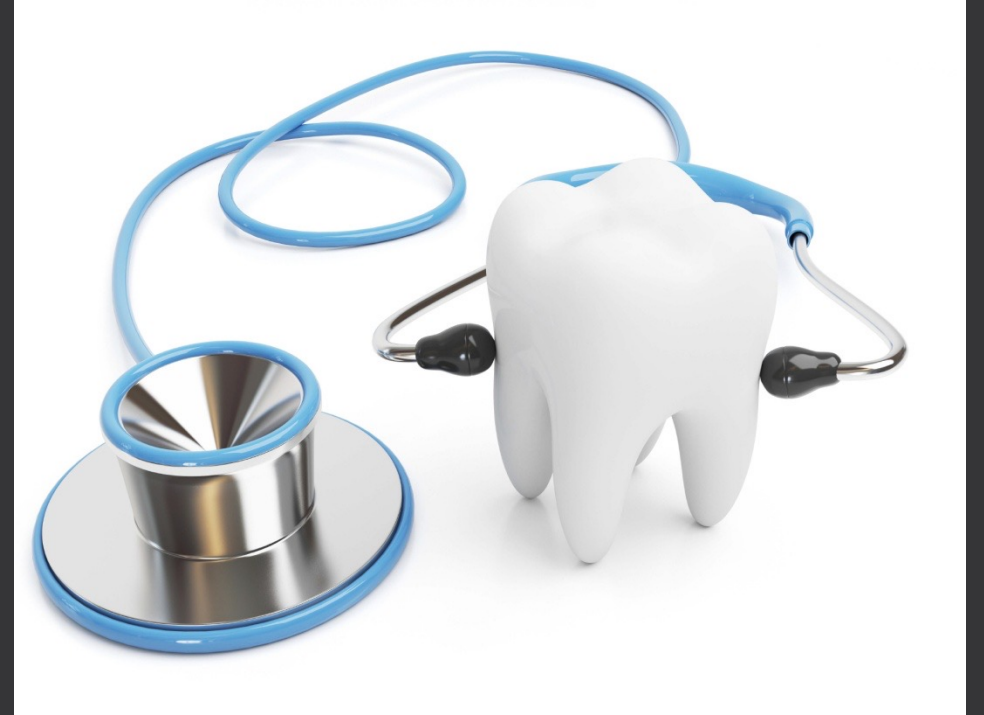•Rôças *et al*, J Endod 2004; 315-320

•Siquera *et al*, Oral Surg Oral Med Oral Pathol Oral Radiol Endod 2004;97:632-41

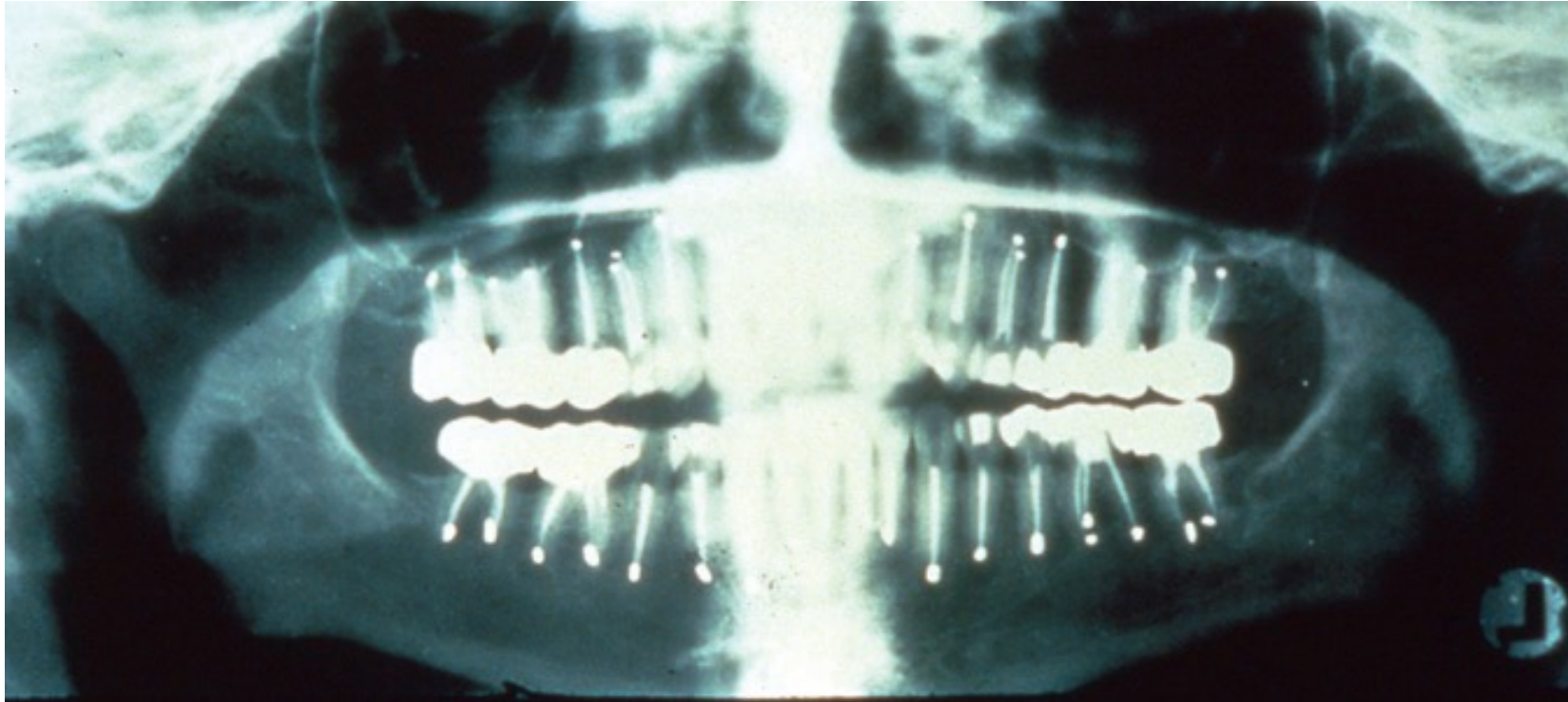•Sjogren *et al*, Int Endod J 1988; 21:277.

•Sundqvist, J Endod 1980; 6: 602-606.

Diagnosis




Diagnosis



The clinician must rule out non-odontogenic etiology, perform all of the appropriate tests, properly interpret the patient's responses to these tests, derive at a definitive diagnosis, and decide on treatment options.

Diagnosis

- In cases of persistent disease, the diagnosis may not be as straightforward as the clinician may be dealing with



Diagnosis

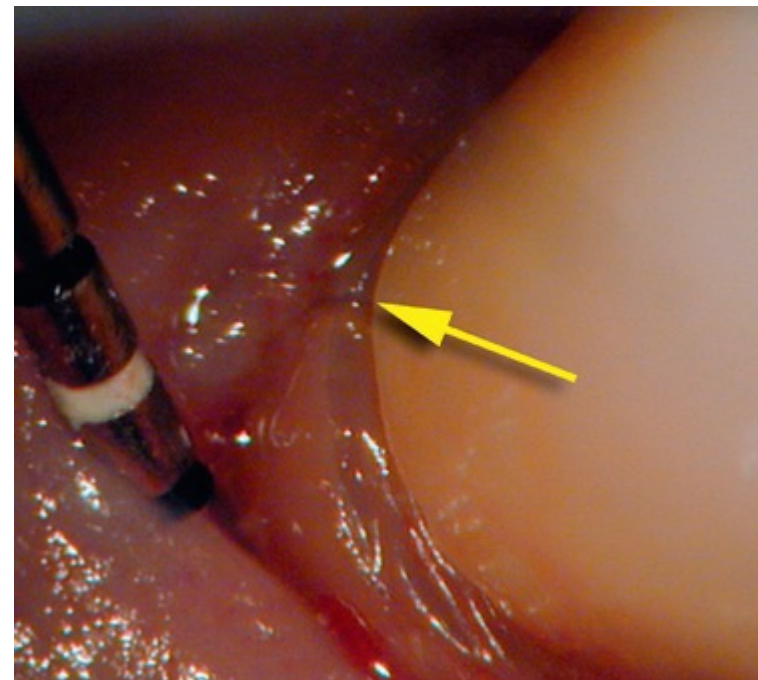
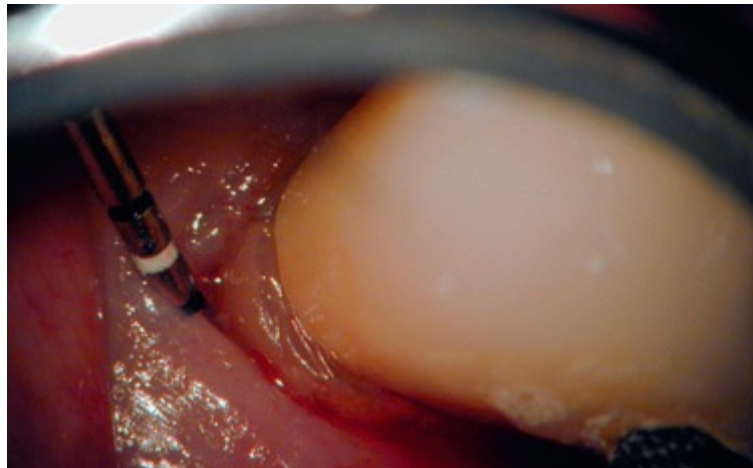
The diagnostic method requires collecting subjective information, developing objective findings, and using these to arrive at a diagnosis and plan of treatment.



Diagnosis

Clinical Examination

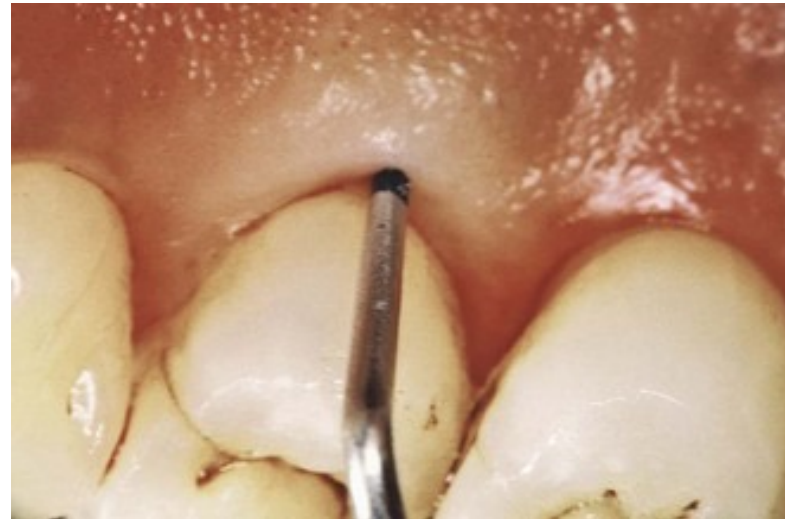Visual examination (intra-oral and extra-oral) aided by magnification and illumination, which can allow the clinician to identify significant conditions invisible to the naked eye, such as fine fractures on root surfaces



Diagnosis

Clinical Examination

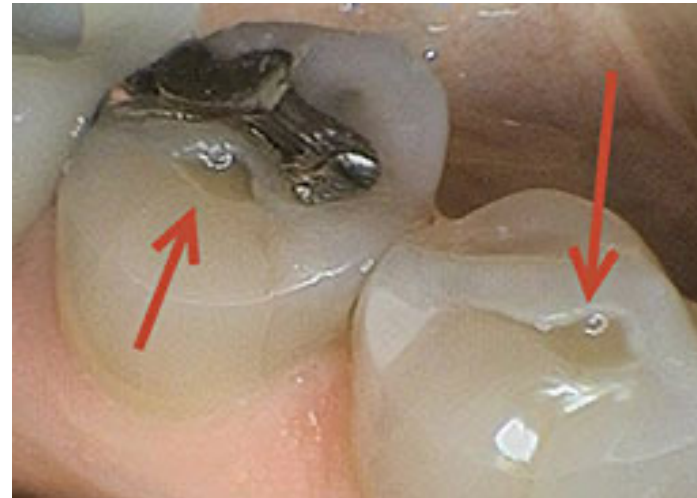- Exposed dentin from recession and narrow based probing defects may be the result of an endodontic infection draining through the sulcus; however, they sometimes indicate vertical root fracture.



Diagnosis

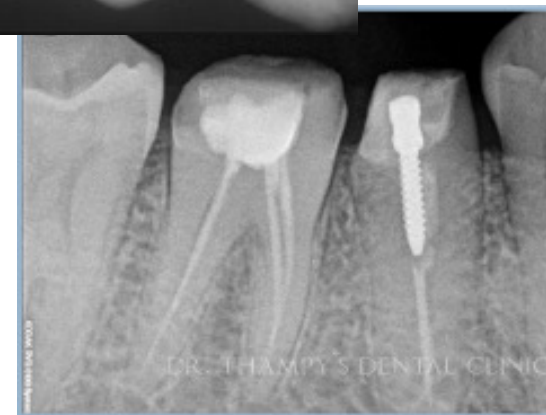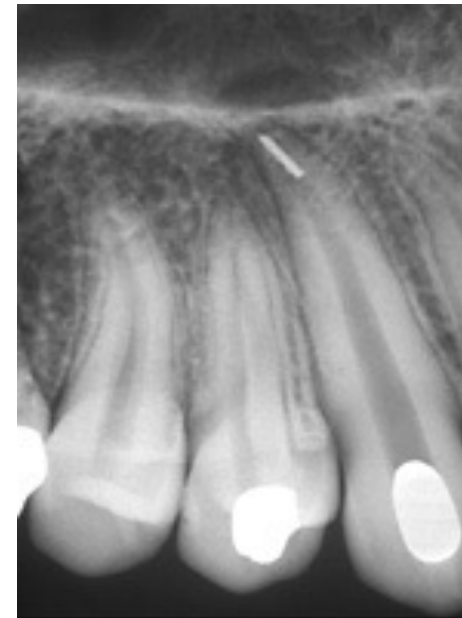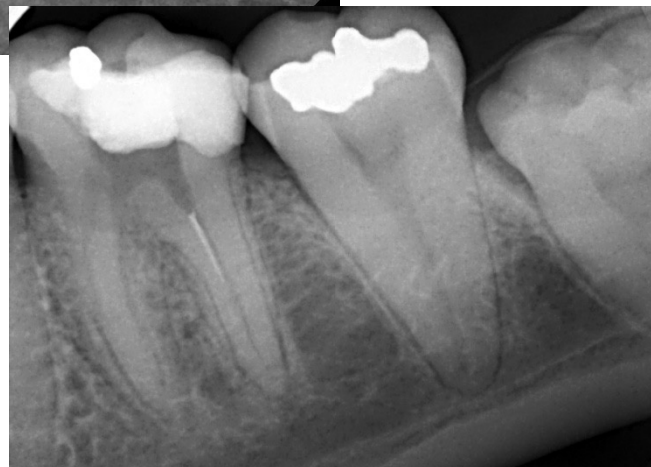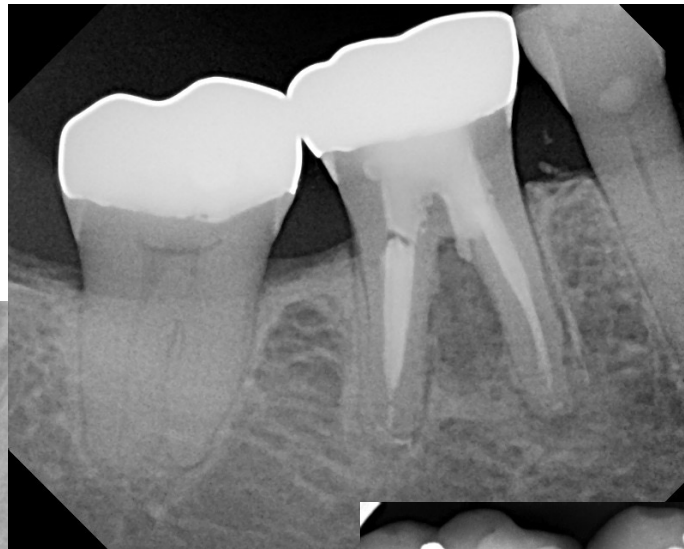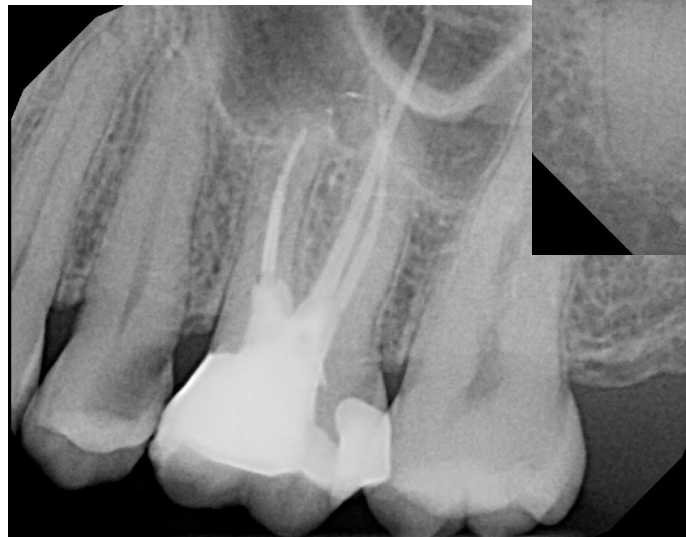Clinical Examination

- The presence of occlusal wear facets indicates the presence of occlusal trauma that may complicate diagnosis and treatment outcome by predisposing the tooth to fracture, and it has been associated with posttreatment disease.



Diagnosis

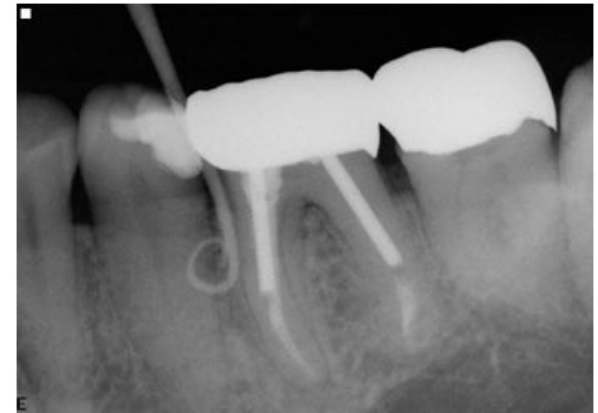
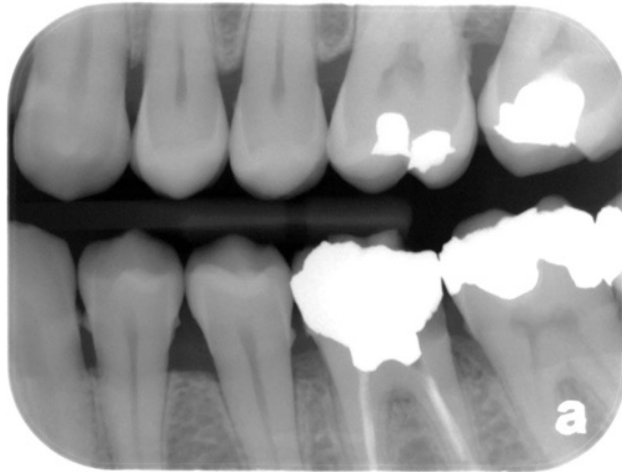
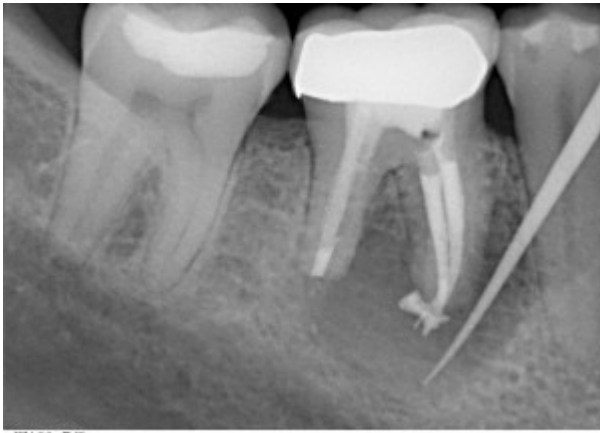
Radiographic Examination



Diagnosis

Radiographic Examination

Bitewing radiographs are useful for determining periodontal bone height and looking for caries or fractures.

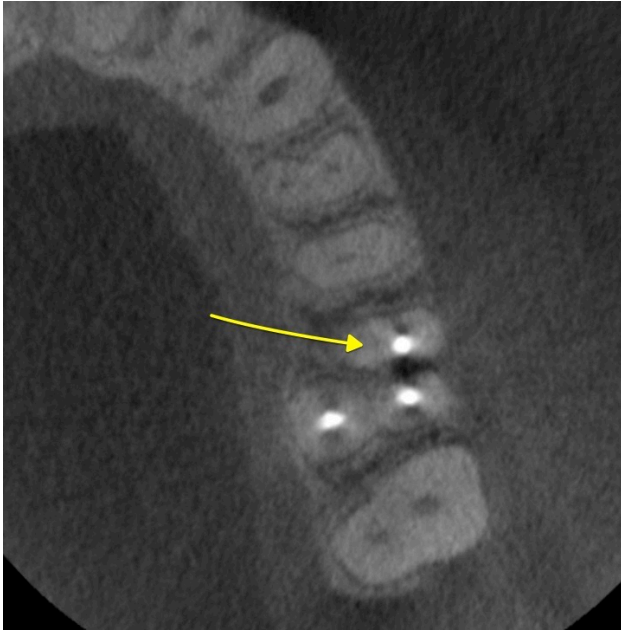


All sinus tracts should be traced with a cone of gutta-percha followed by a radiograph to localize their origin

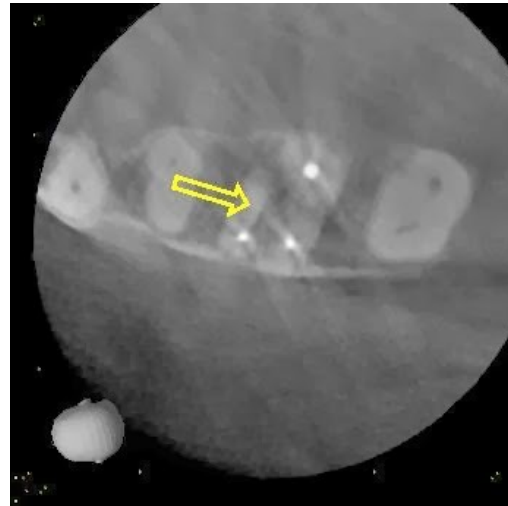
Diagnosis

CBCT

The CBCT allows the clinician to determine the true size, extent, and position of periapical and resorptive lesions and gives added information about tooth fractures, missed canals, root canal anatomy, and the nature of the alveolar bone topography around teeth.



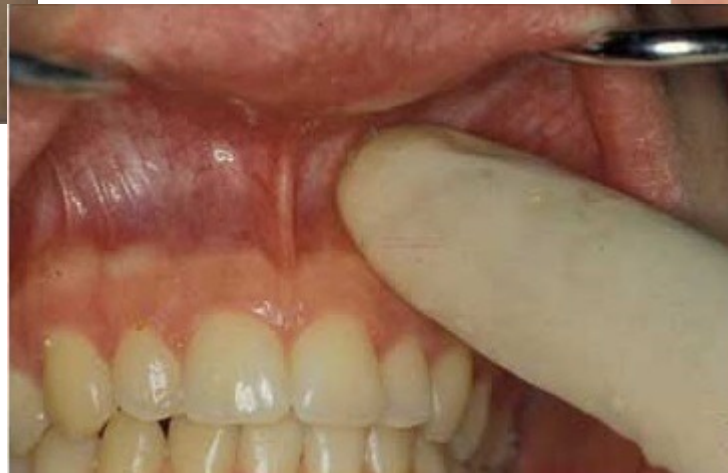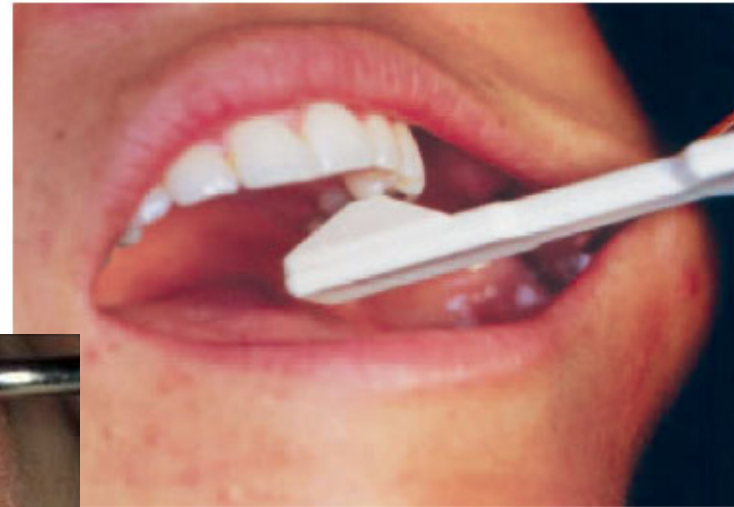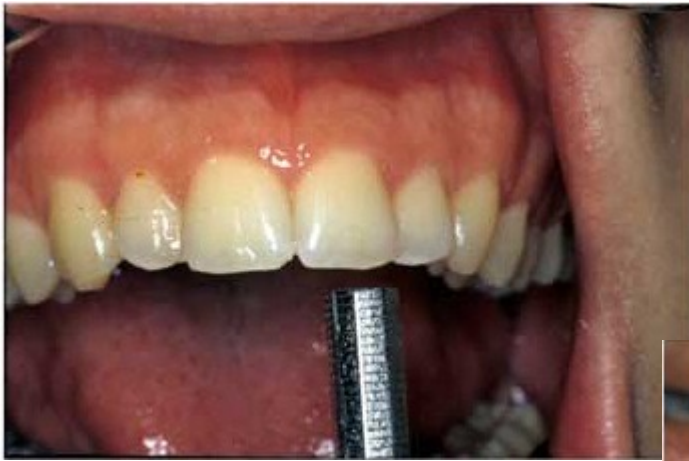Patel *et al*, Int Endod J 2015; 3–15.



Diagnosis

Comparative Testing

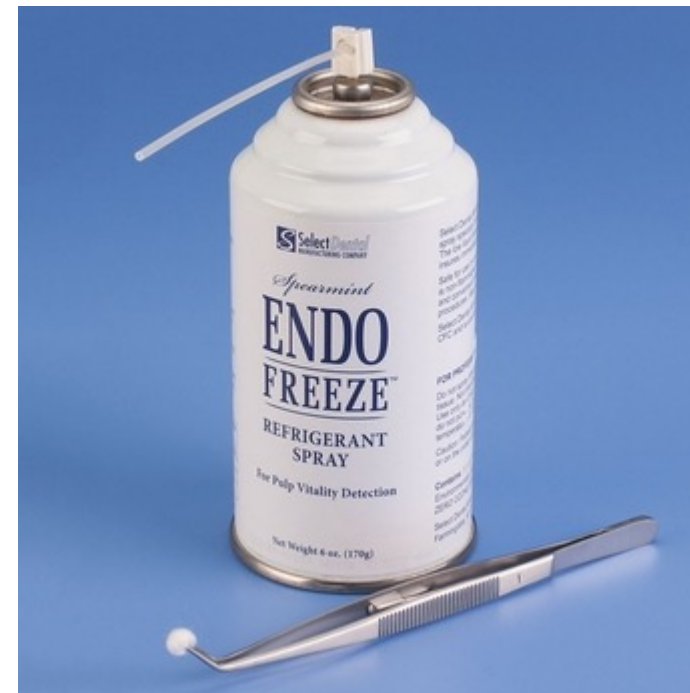Percussion, bite, and palpation to evaluate the status of the periradicular tissues.



Diagnosis

Comparative Testing

Pulp vitality tests are often of little value when examining teeth with previous endodontic therapy. However, if the patient's chief complaint reveals the need for these tests, they must be performed because it is possible that the pain may be referred from a nearby vital tooth and not from the root canal– treated tooth.





Treatment Planning

Treatment Planning



If the cause of the post-treatment condition remains unknown despite thorough diagnostic workup, then any decision results in an empirical “trial and error” type of treatment. This approach should be avoided if possible.

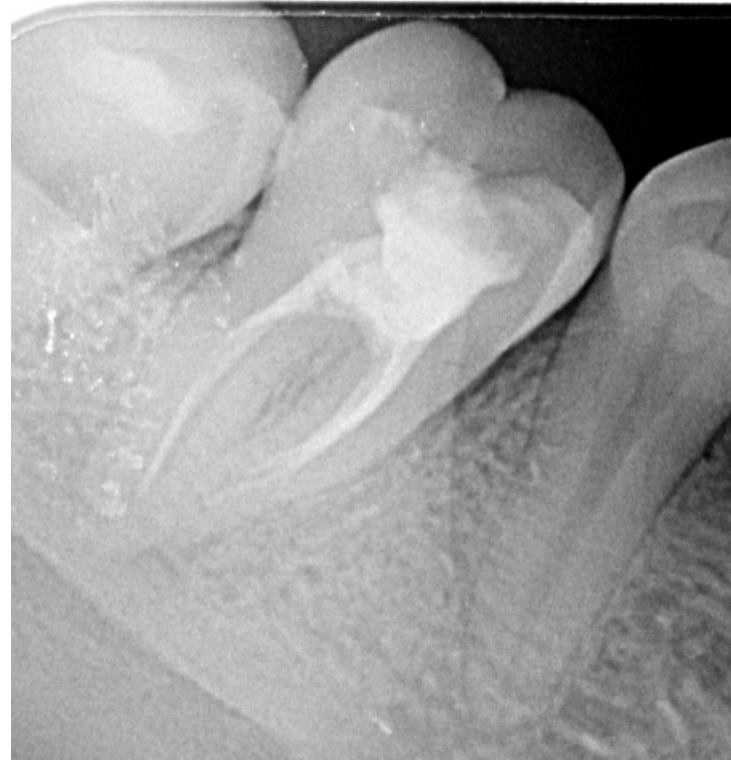The patient is then allowed to make a decision based on his or her own perceptions of the options, not by the clinician’s opinion as to what is “best” for the patient.

Removal of Obturator Materials

Obturation Materials

- Gutta Percha
- Solid core obturators.
- Paste
- Resilon
- Silver points.





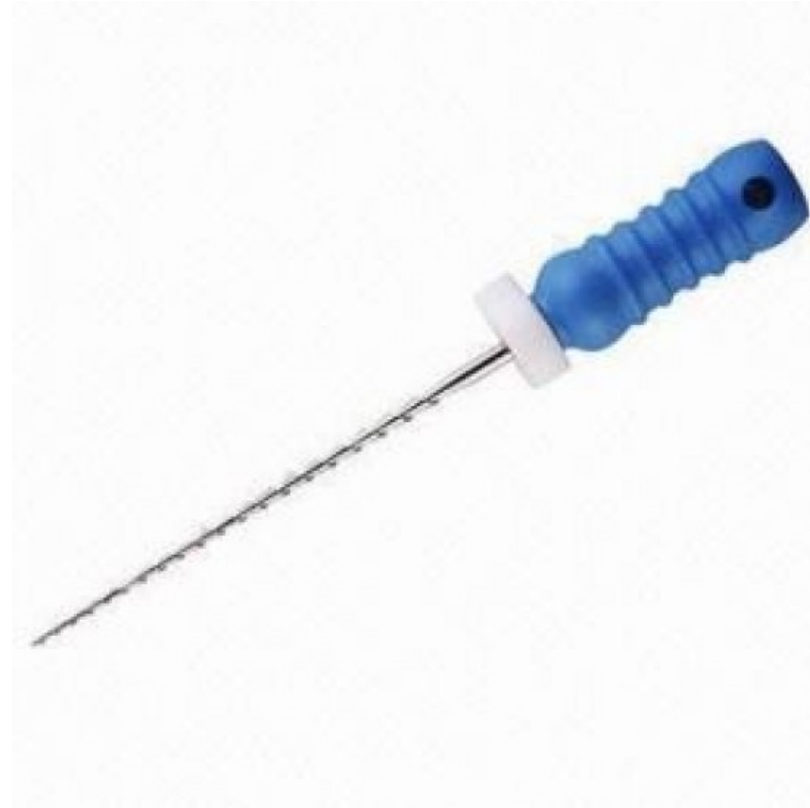Removal of Gutta Percha

Removal of Gutta Percha

- Single cone GP
- Condensed GP

Removal of Gutta Percha

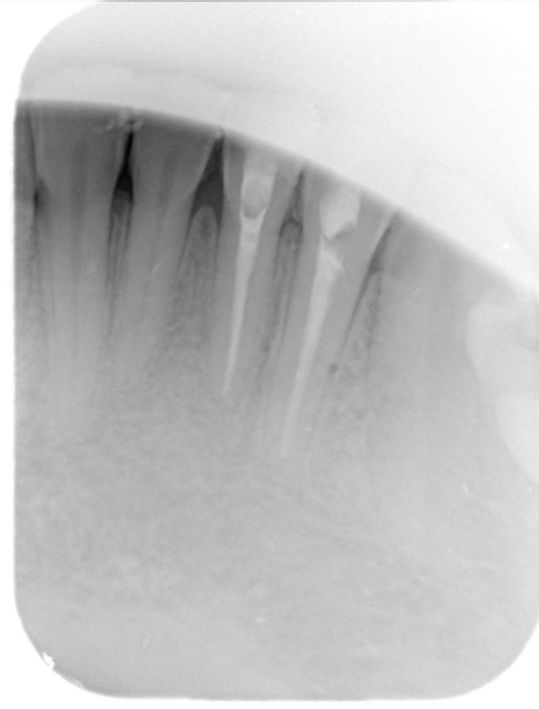
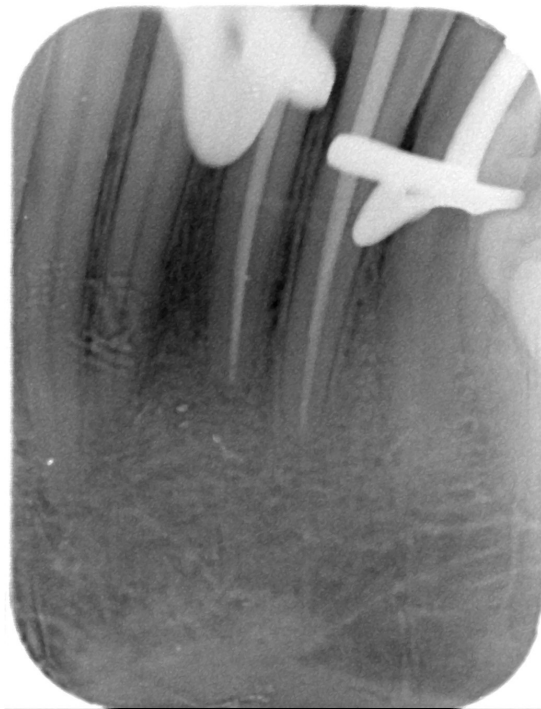
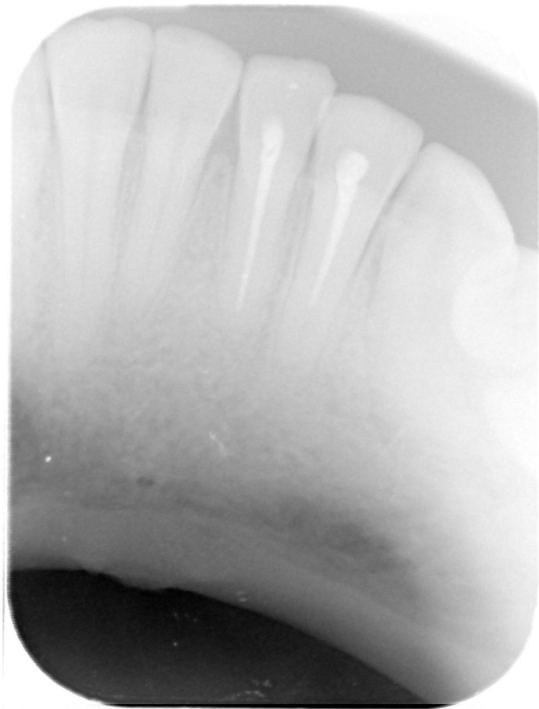
- *Removal of gutta percha manually*
- *Removal of gutta percha using rotary system*
- *Removal of gutta percha using LASER*



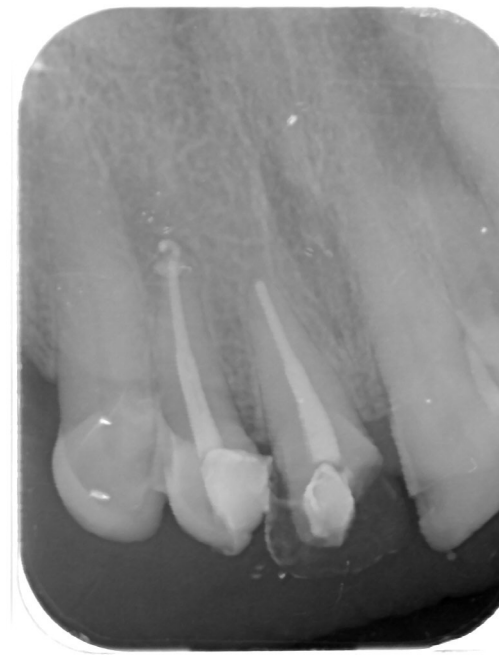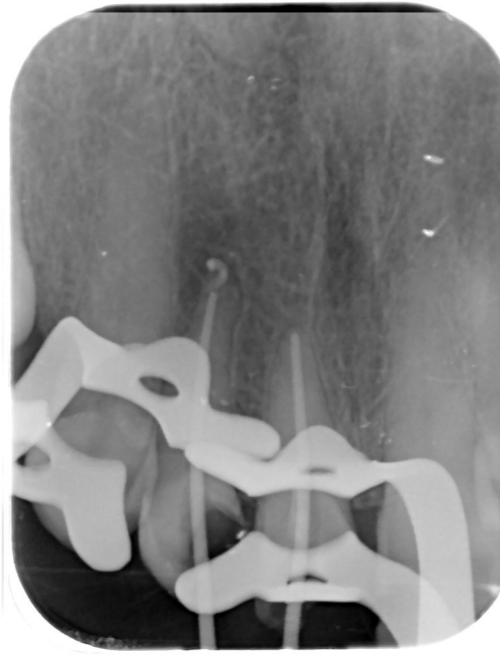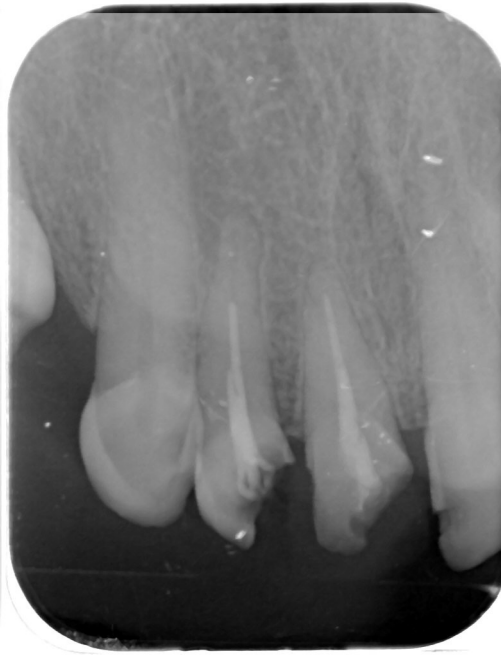Removal of gutta percha manually



Removal of gutta percha manually




Removal of gutta percha manually



Removal of gutta percha manually

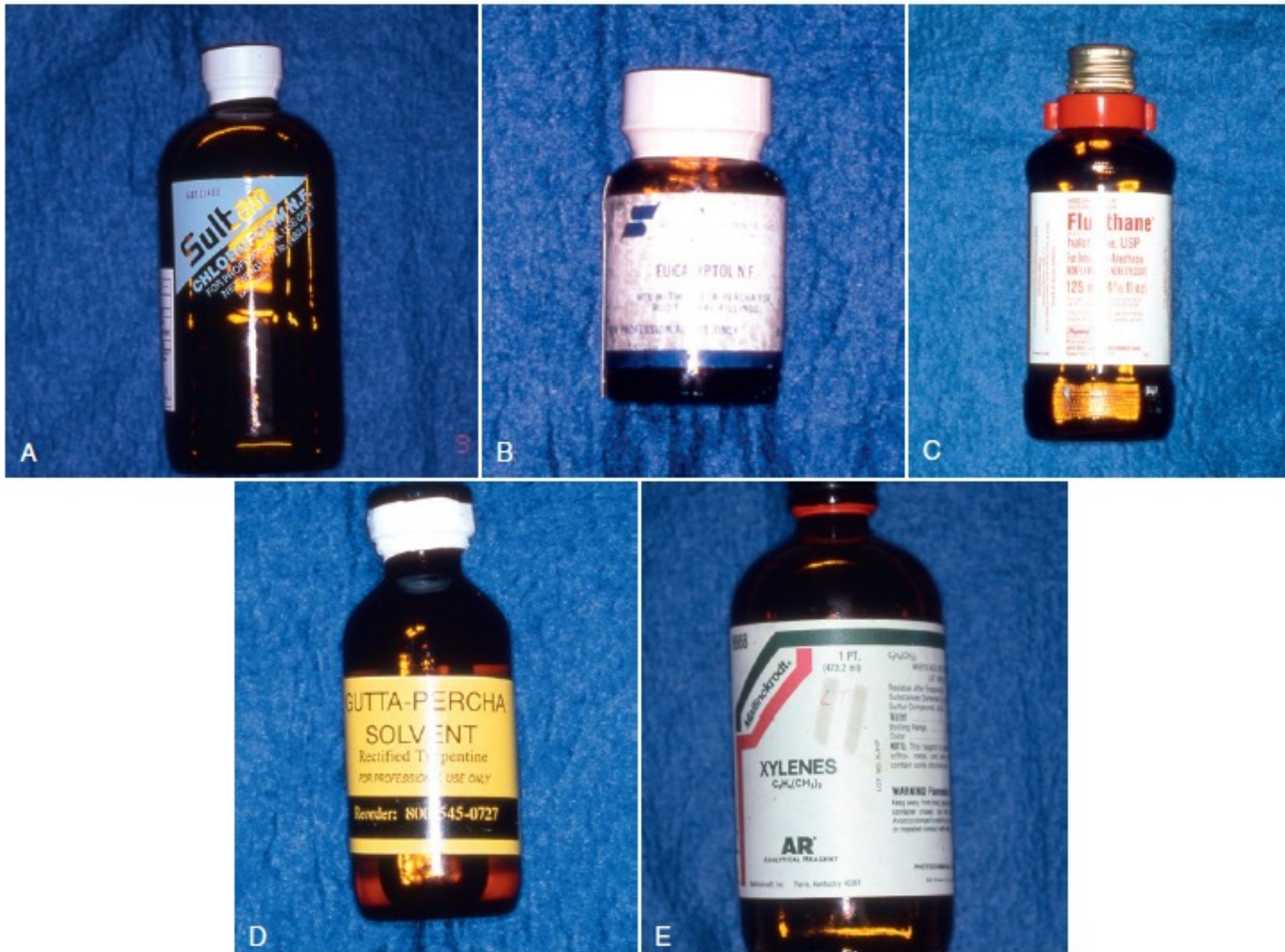

FIG. 8-31 A, Chloroform. B, Eucalyptol. C, Halothane. D, Rectified turpentine. E, Xylenes.



Removal of Gutta Percha with Rotary Instruments



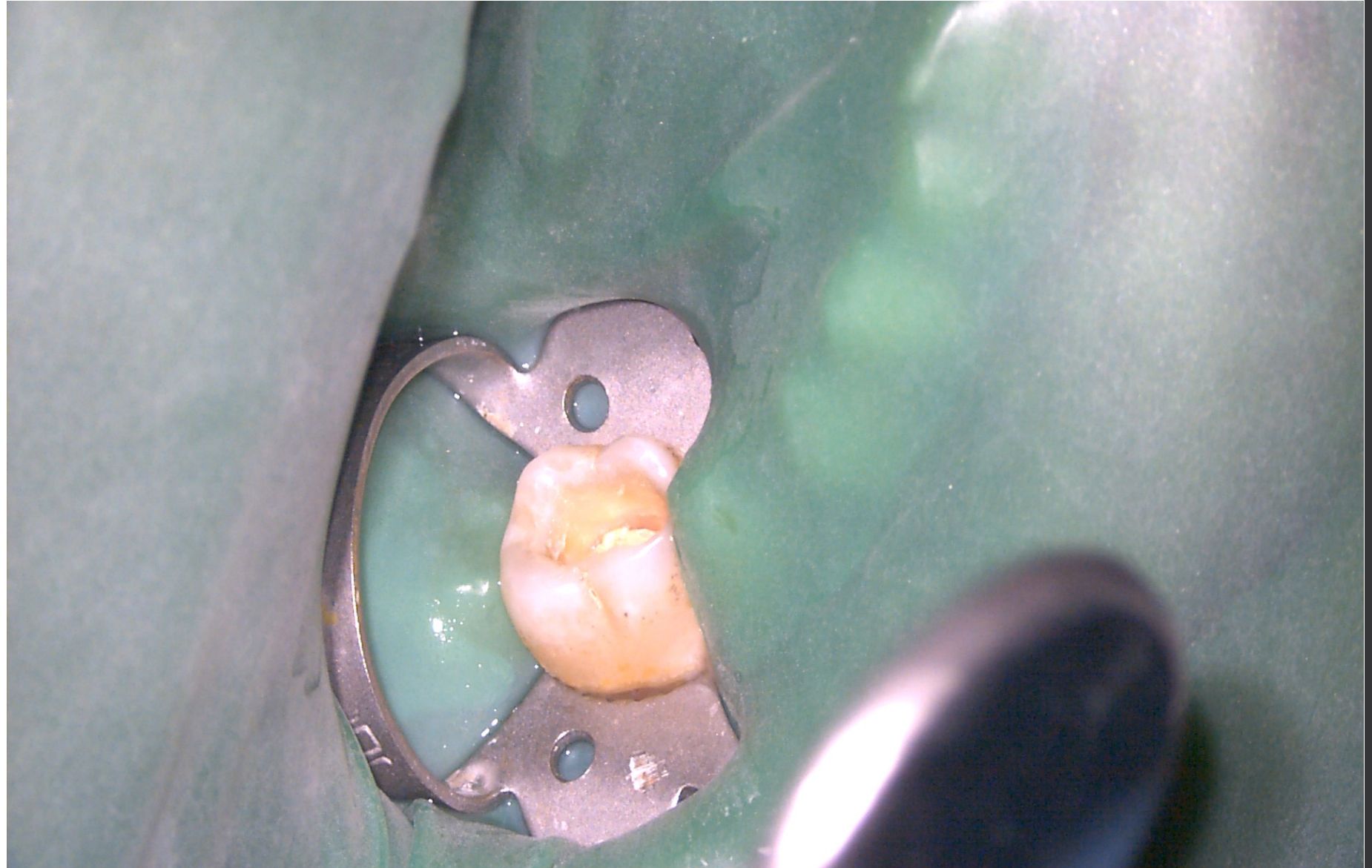12%

8%

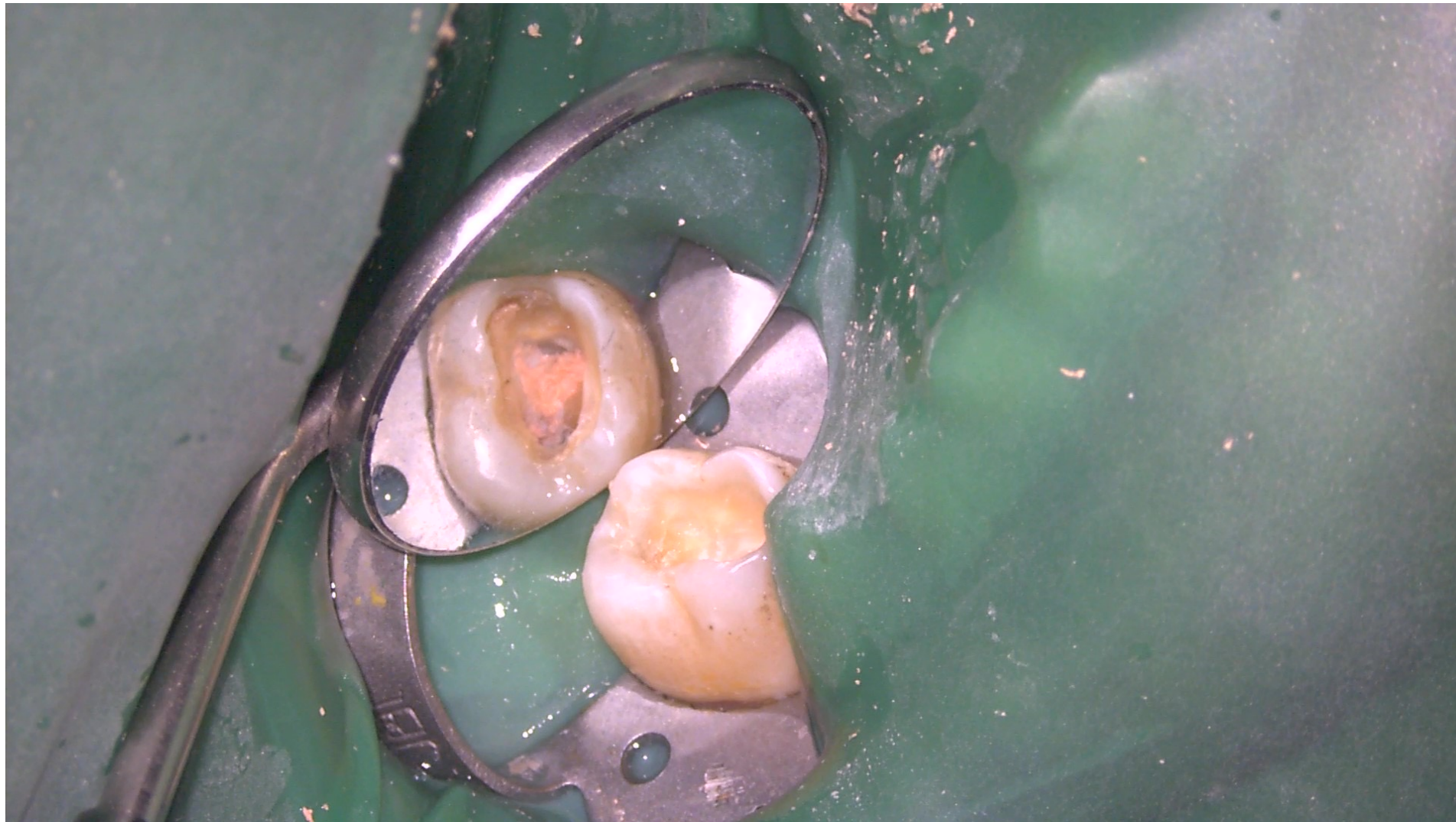
6%

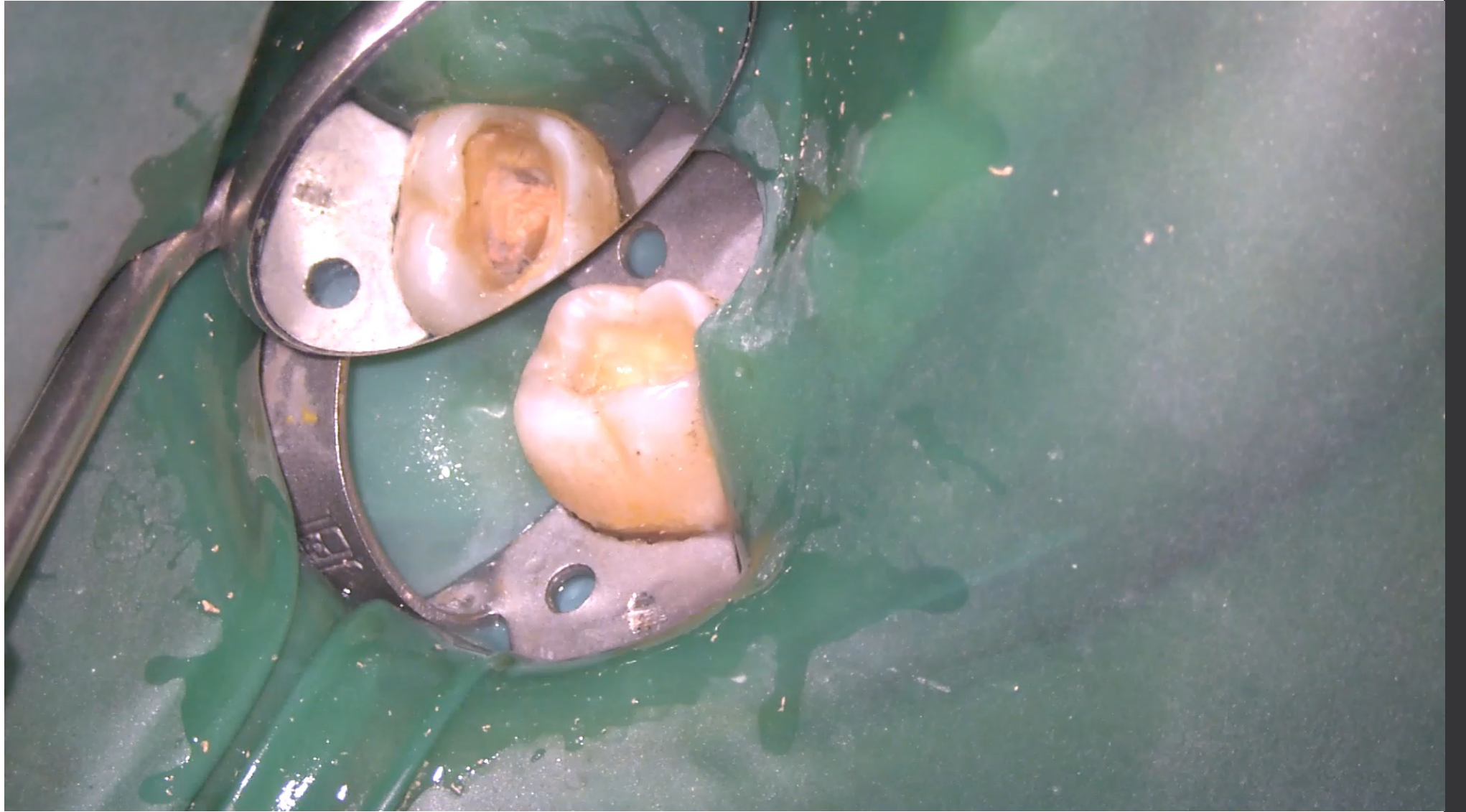
4%

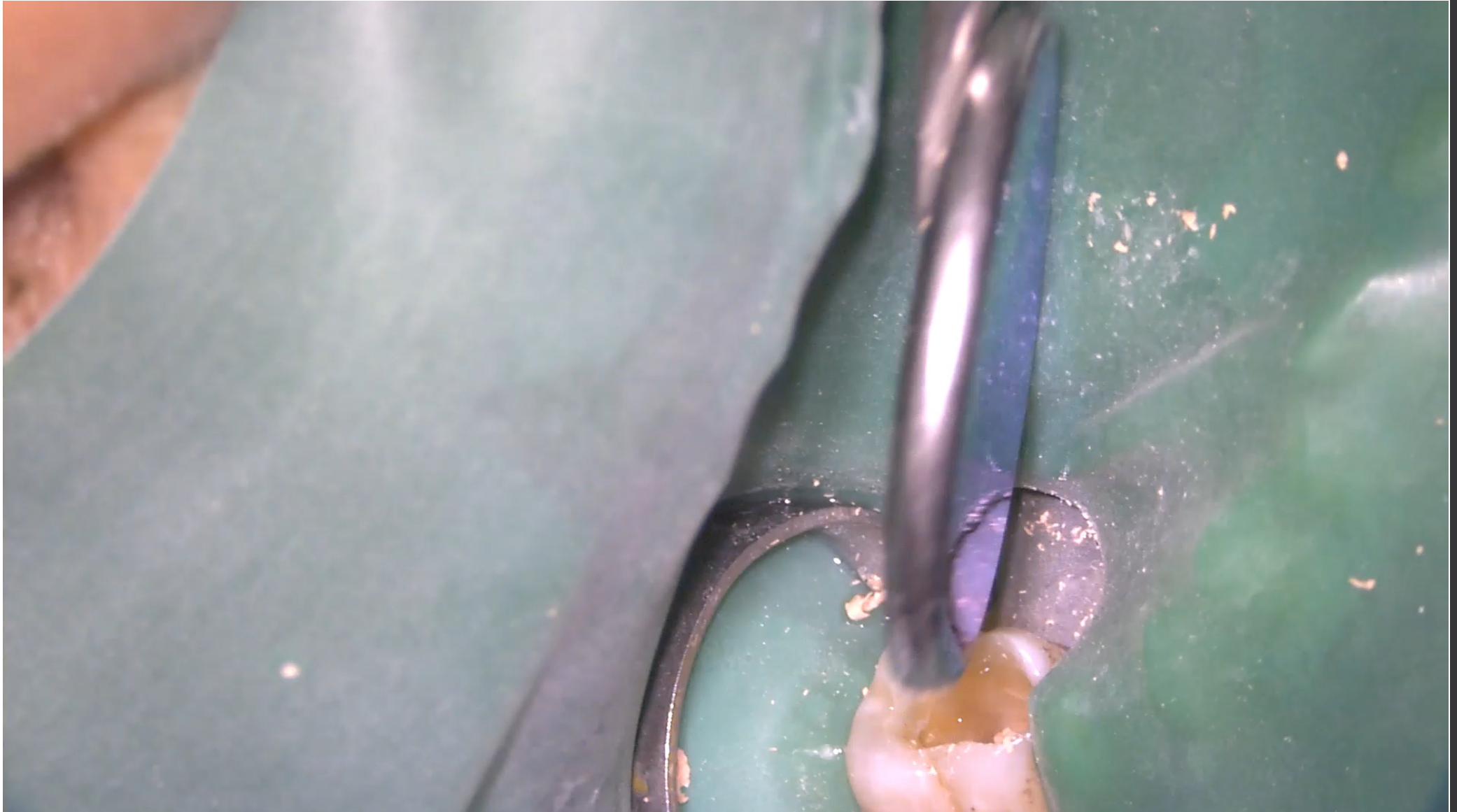Removal
of GP



Removal
of GP



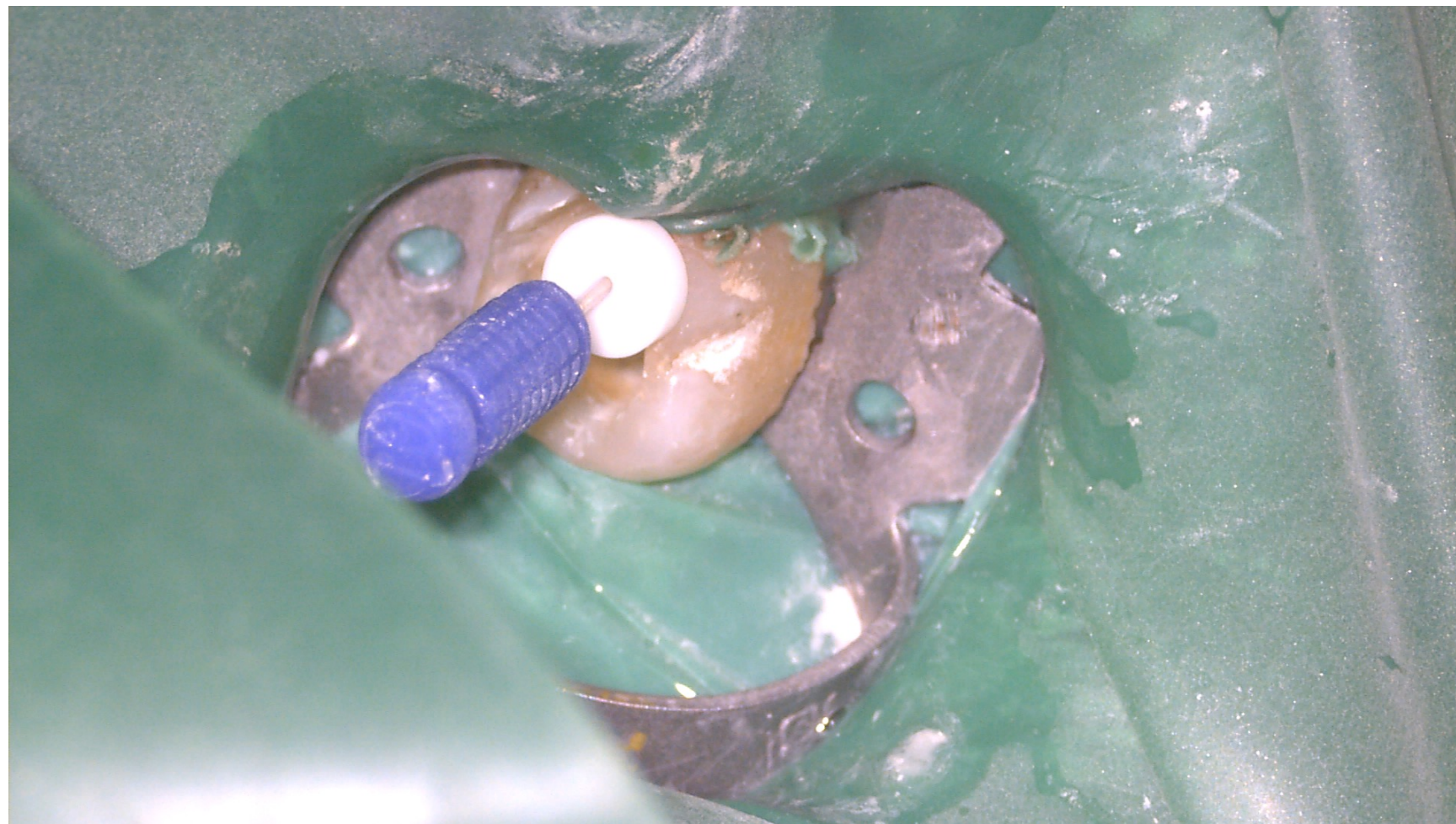




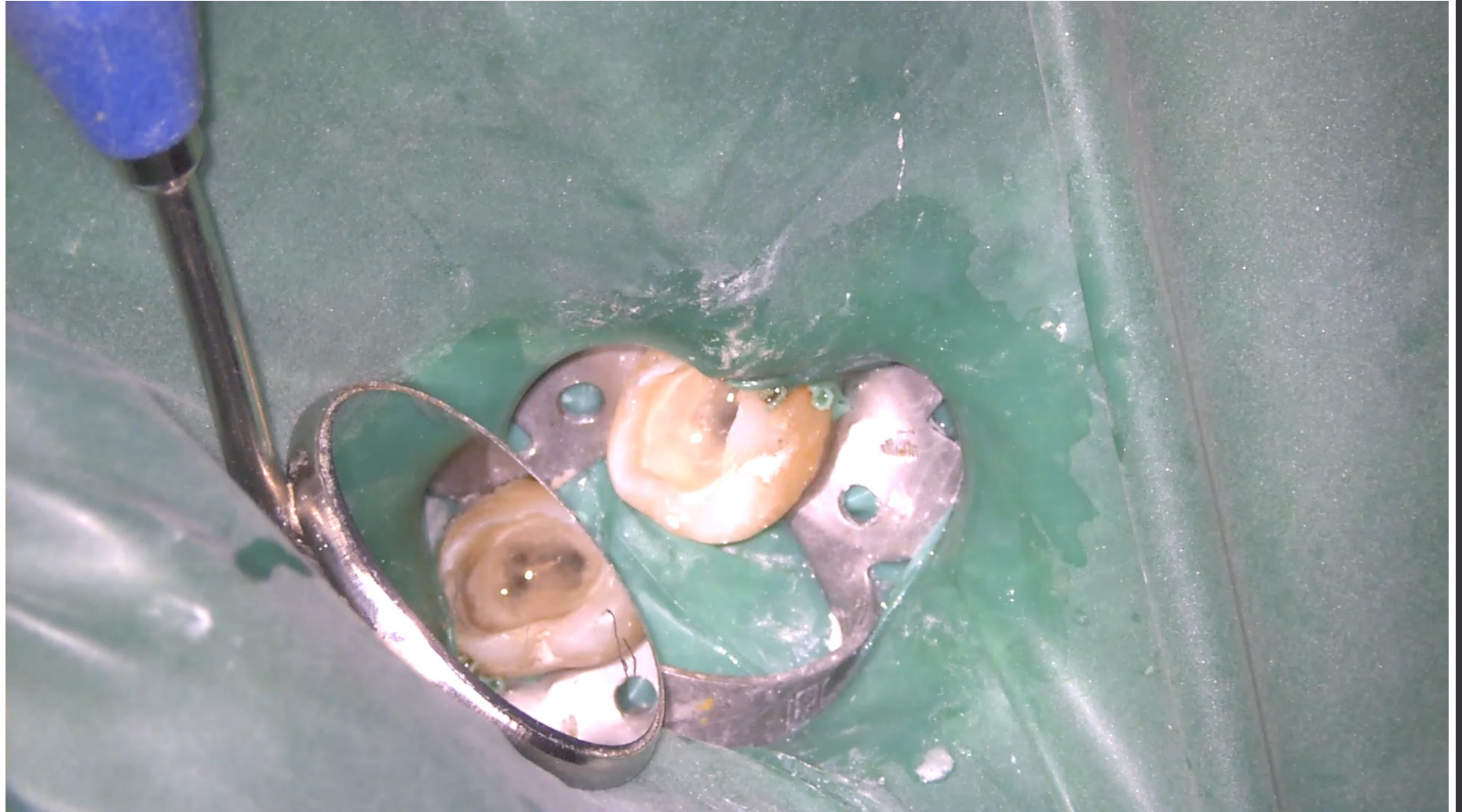

Canal
negotiation

W.L.
determination



Finishing the
preparation





Just remember

- Irrigate

- Irrigate

- irrigate






Remove solid core obturators

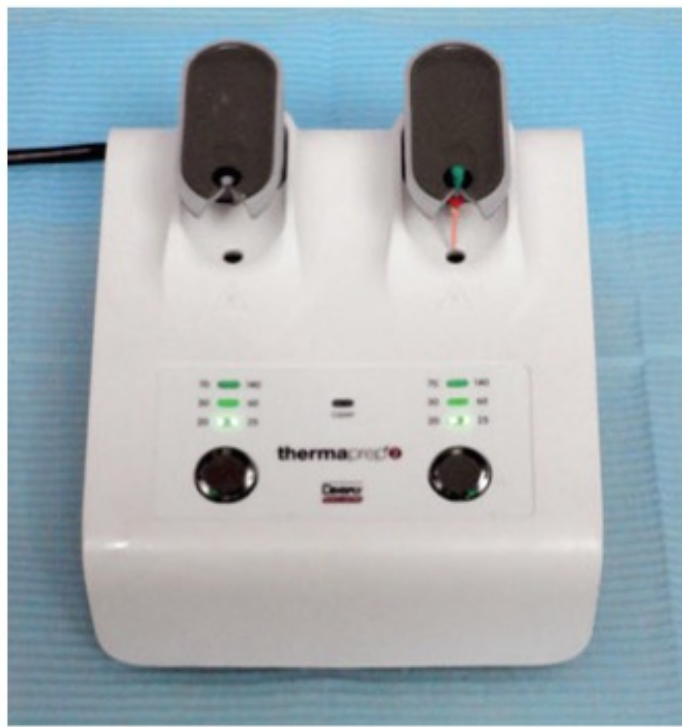

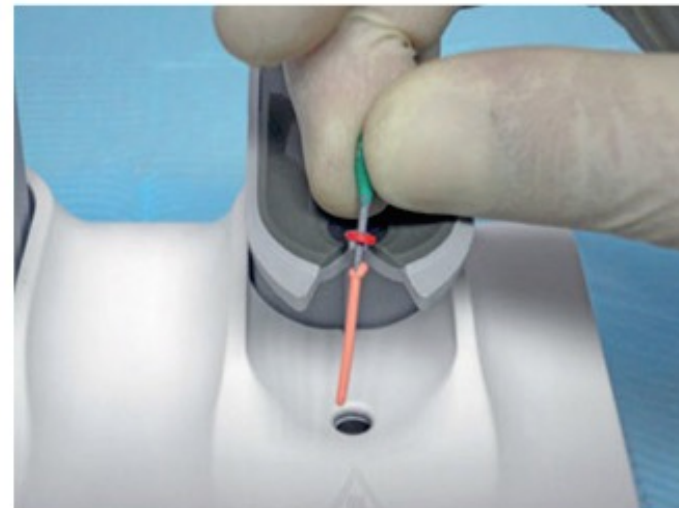Figure 10



Figures 11-13: Heating an obturator in a ThermoPrep 2 oven

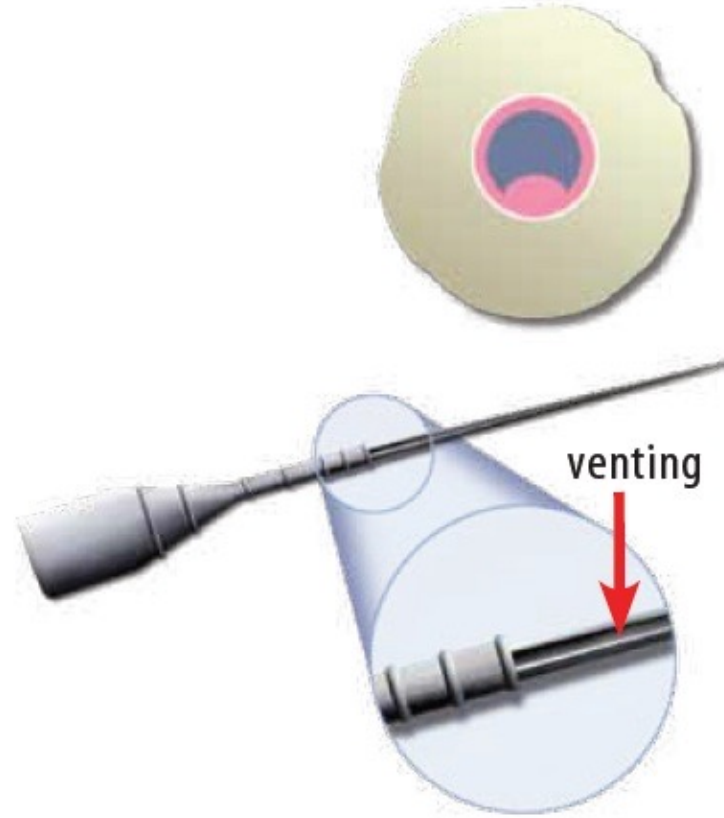


Figures 12

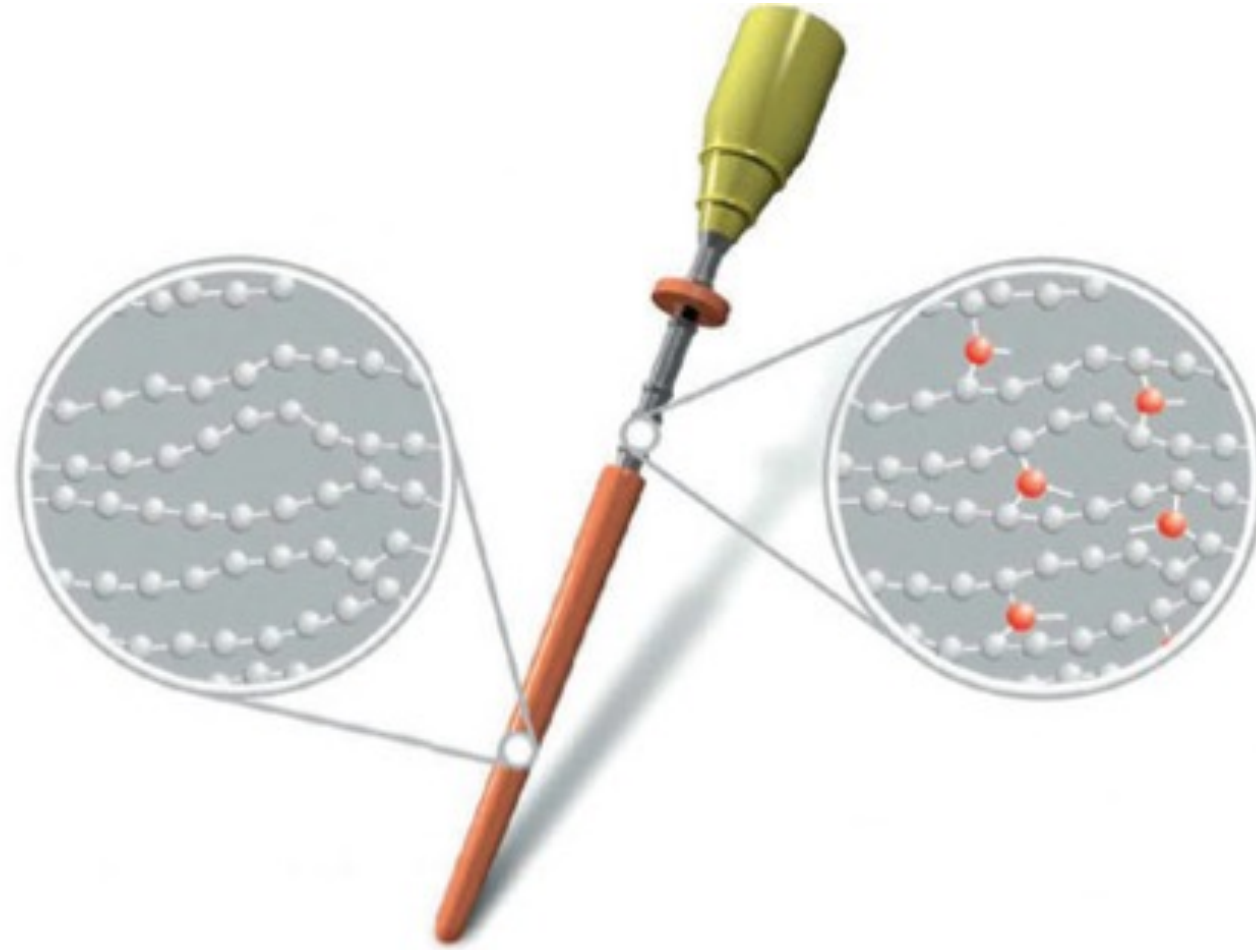


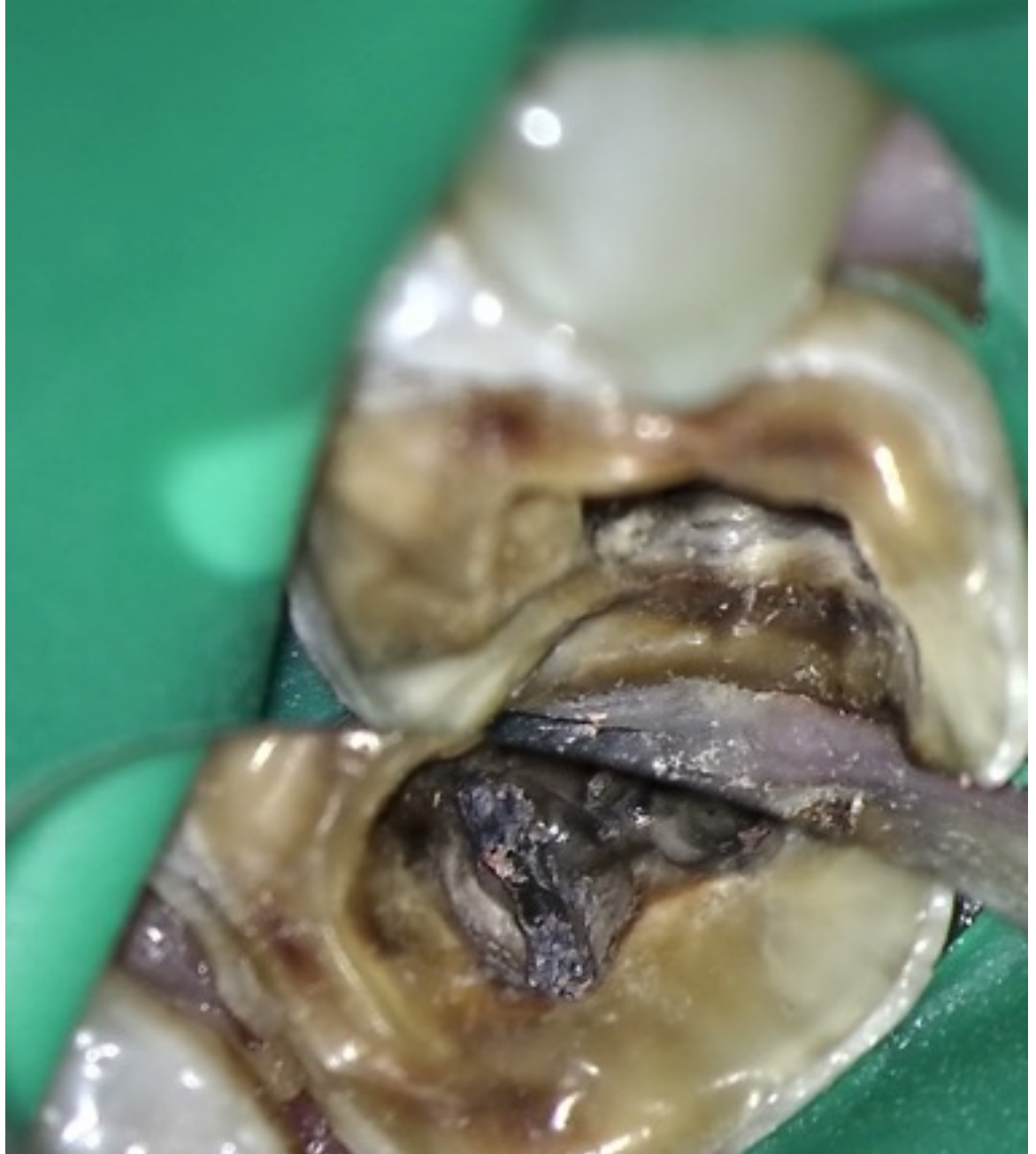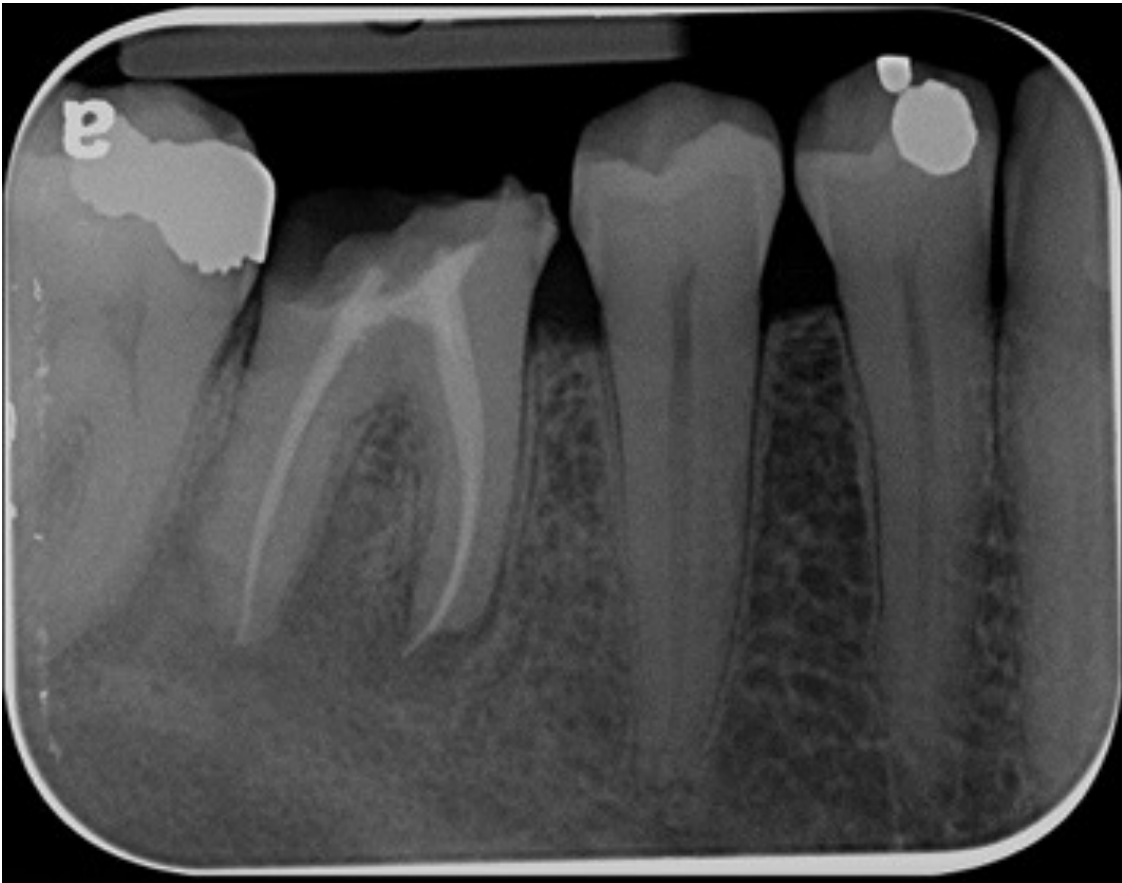Figures 13

Therma fill plus with vent

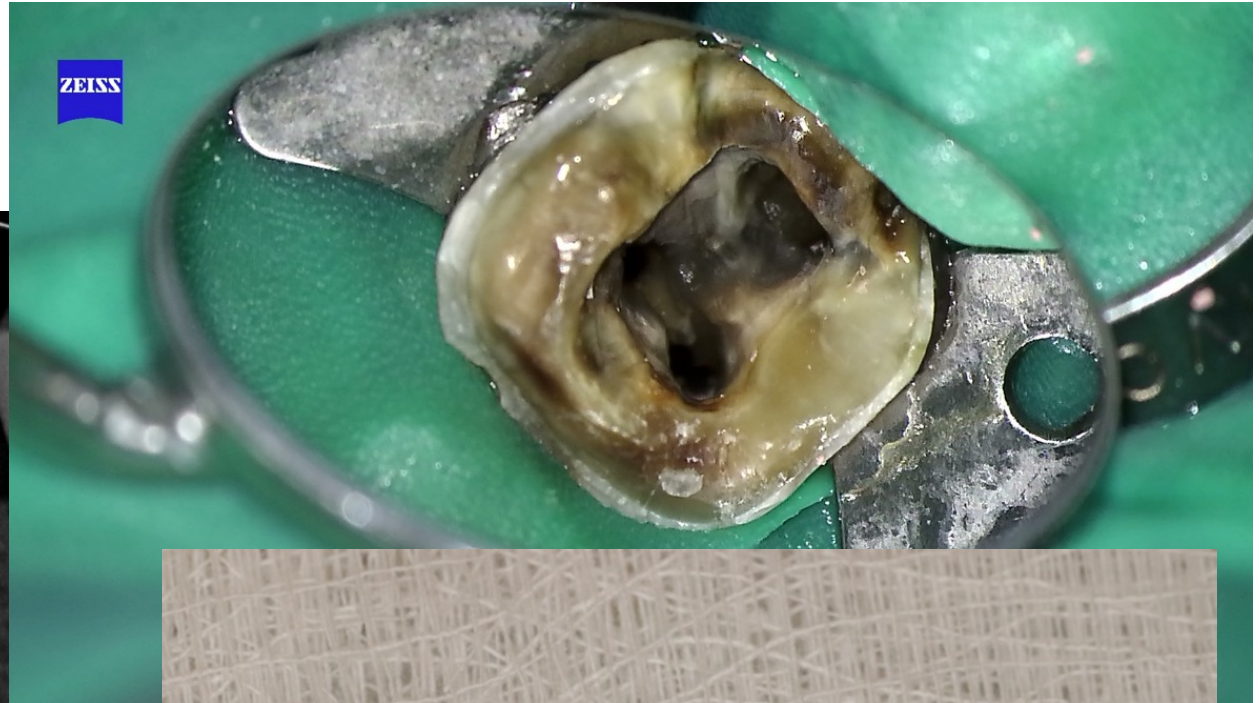
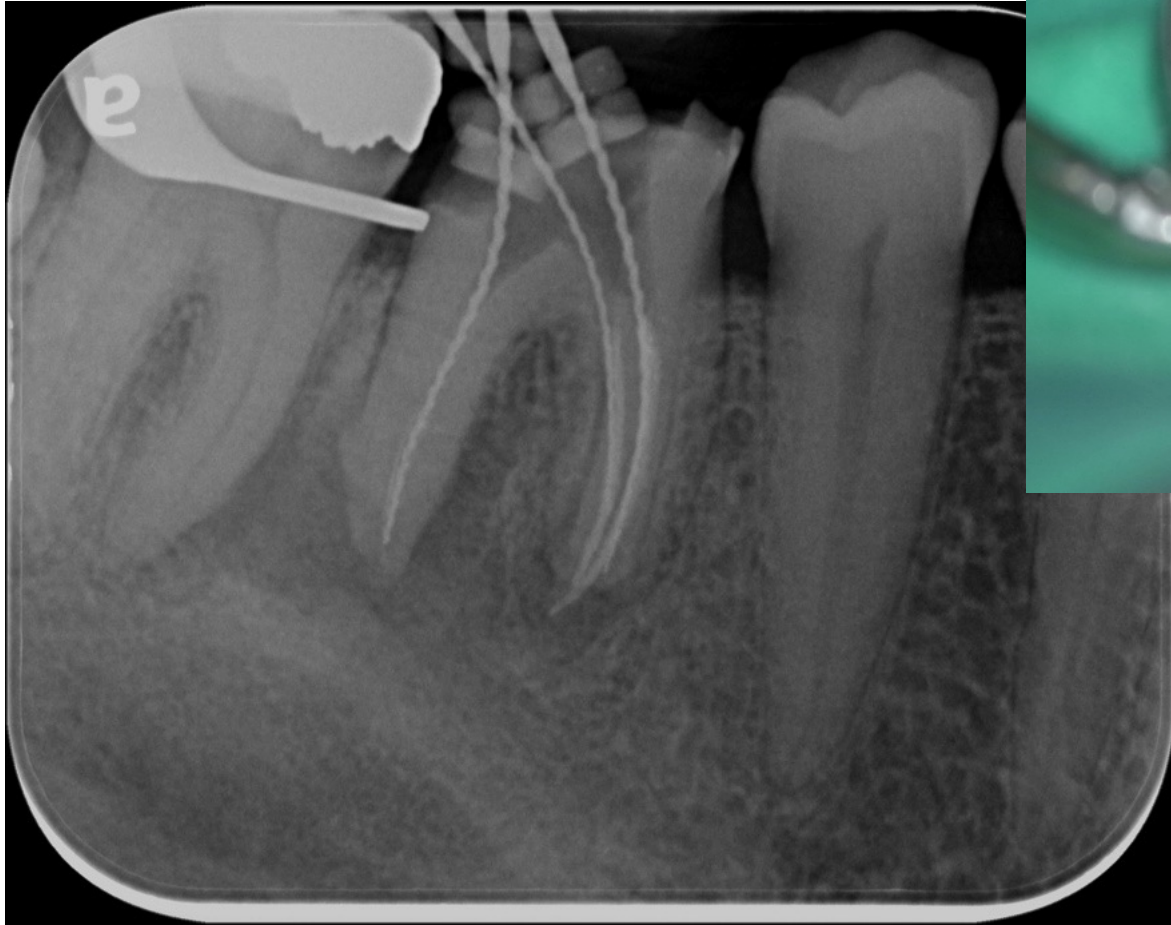

GuttaCore (Dentsply)

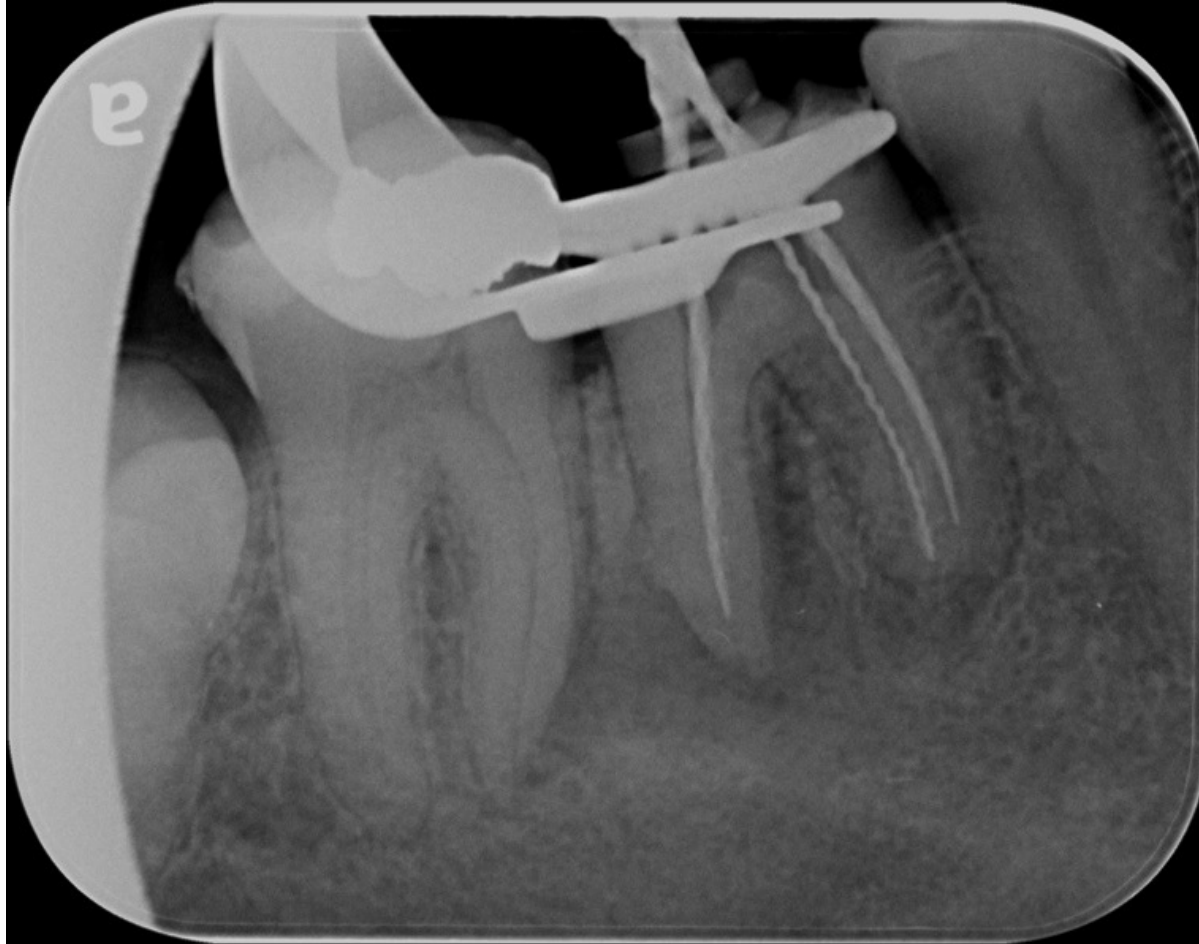




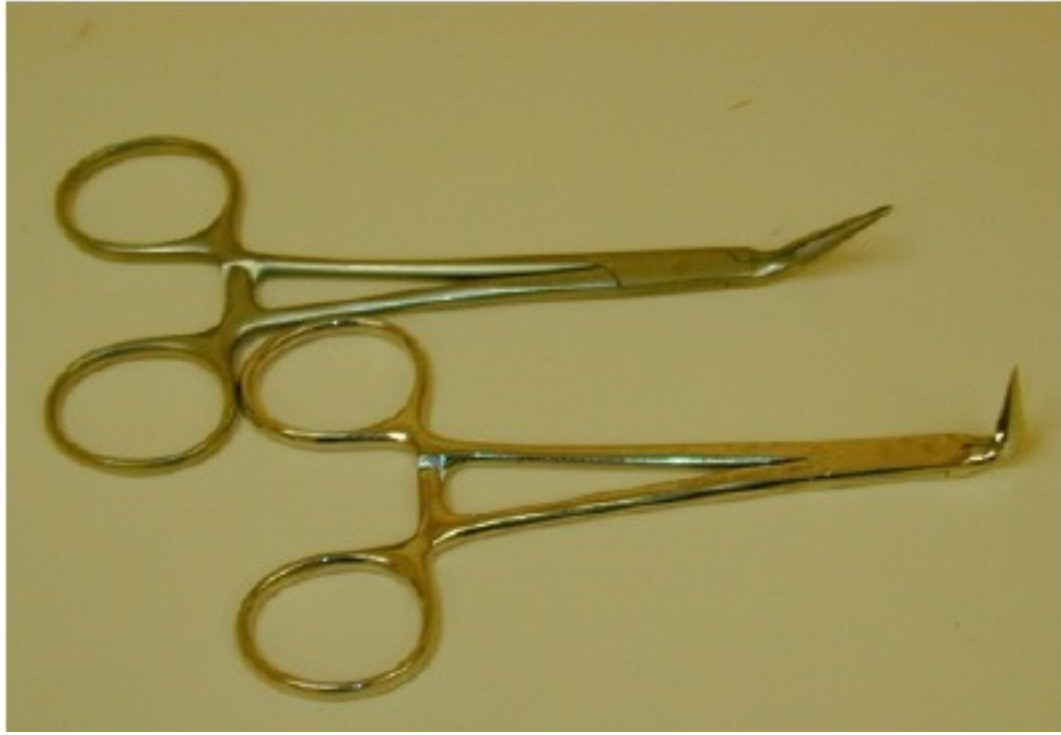• Dr. Adreani

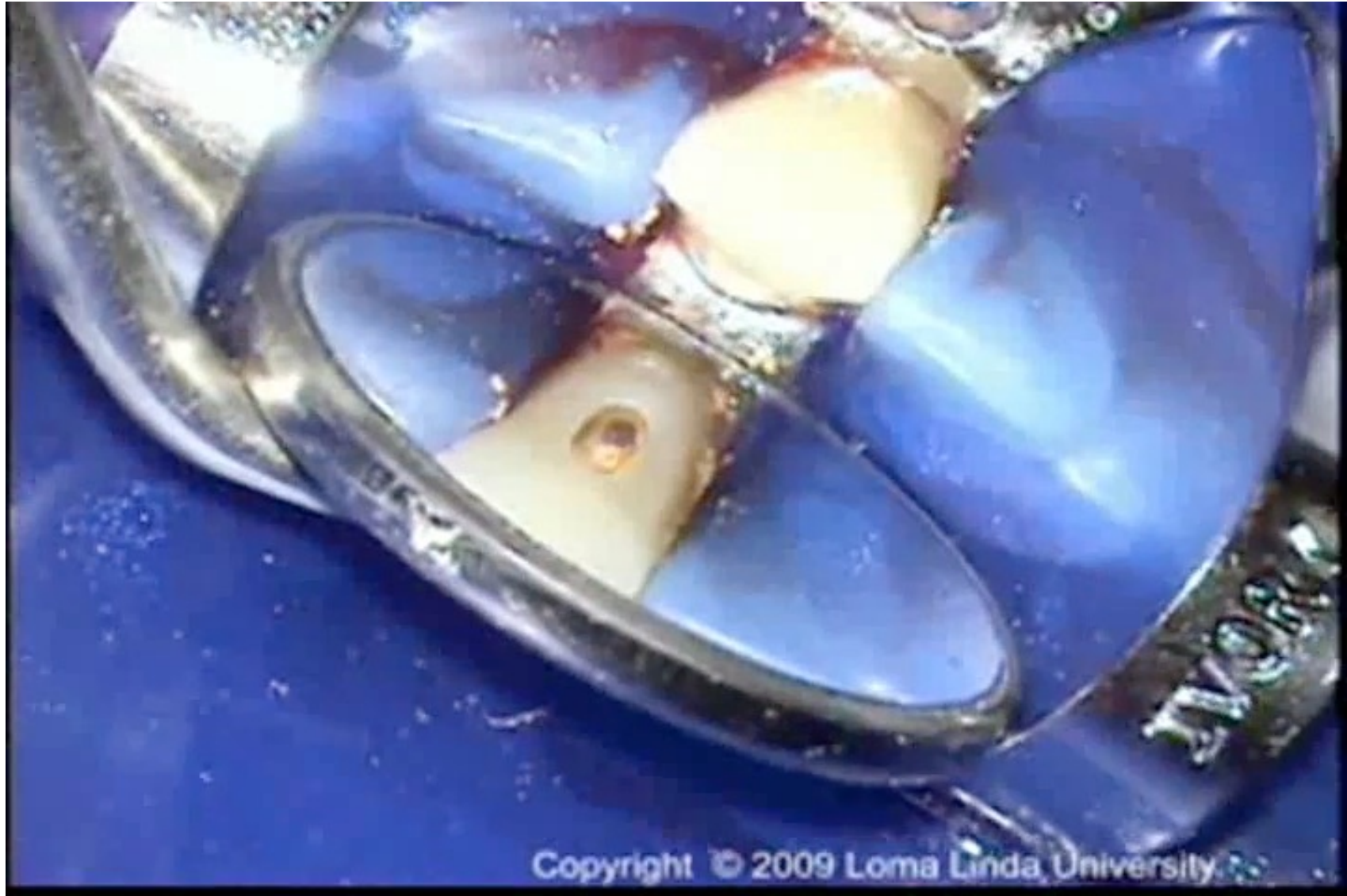

• Dr. Adreani

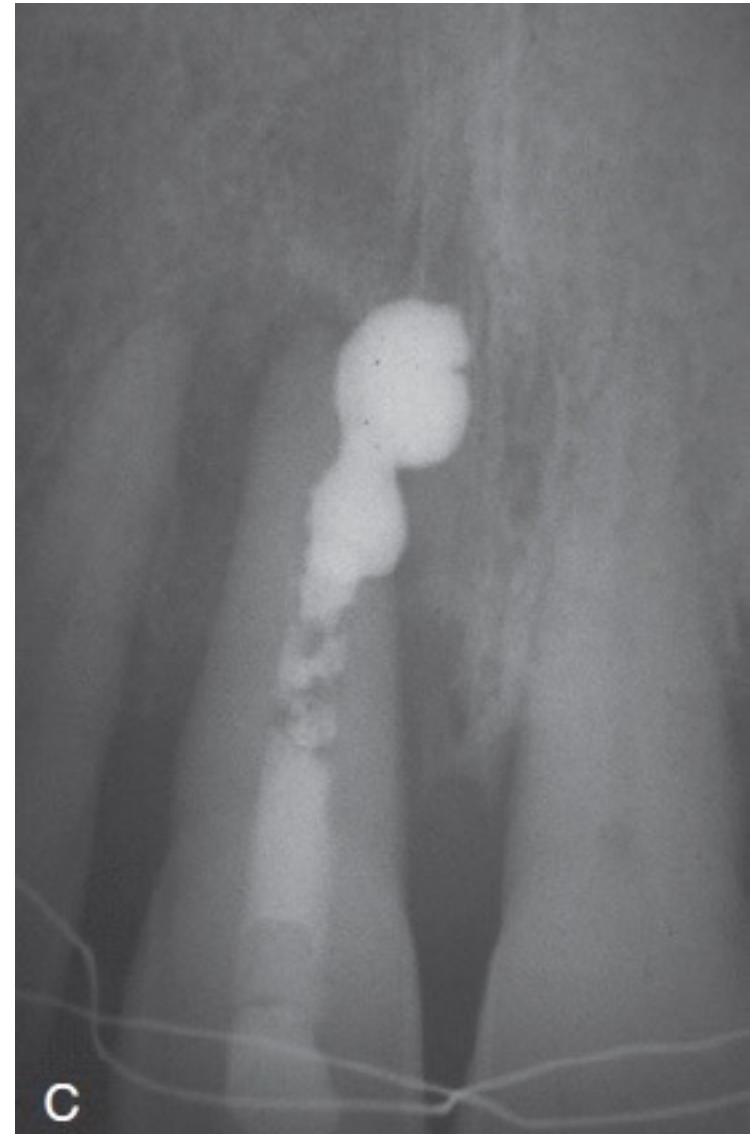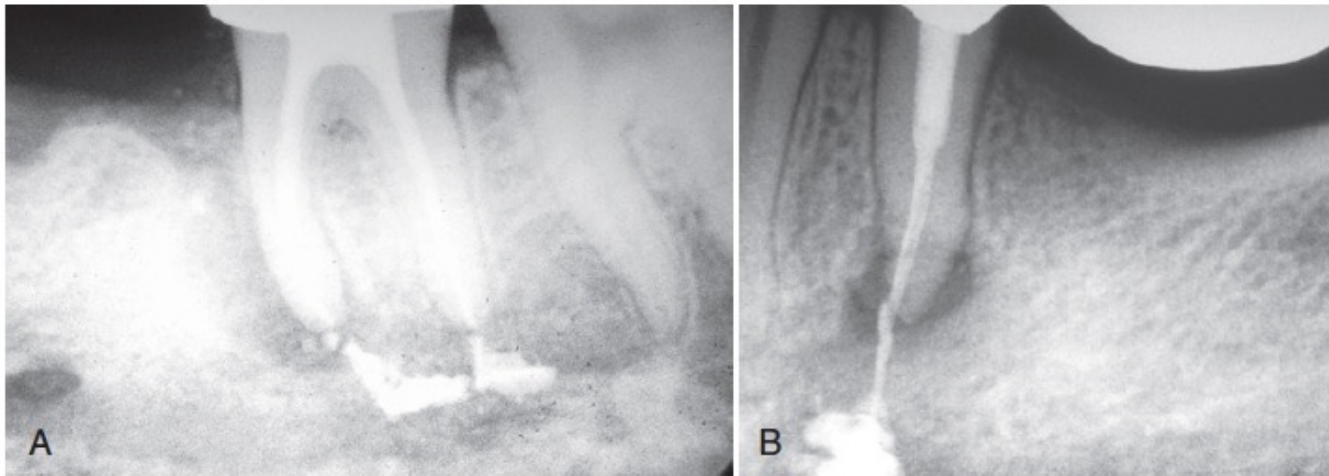


• Dr. Adreani





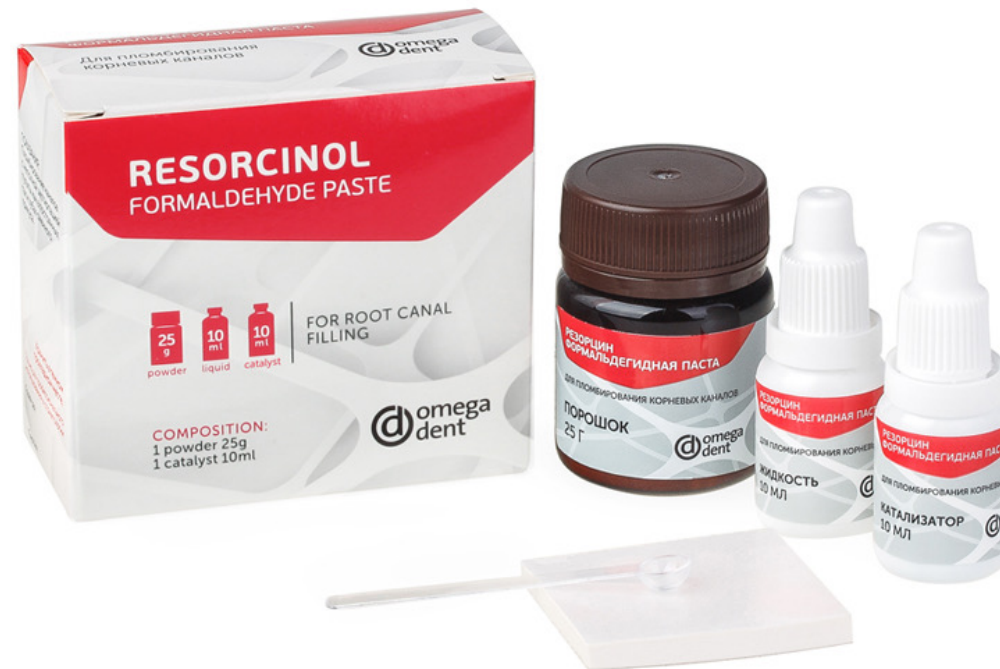Paste removal

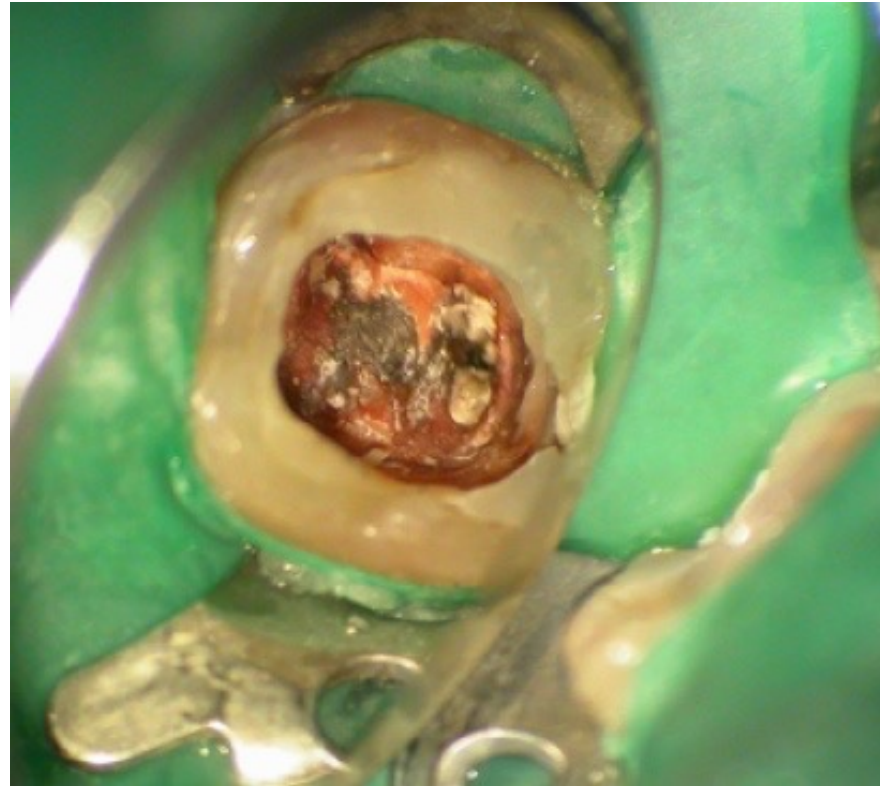

- **Removal of Non setting or Soft paste**

- Solvent
- Hand or rotary instrument (copious Naocl irrigation).
- Ultrasonically activated and irrigated files

Hard sitting paste





- Resorcinol-formaldehyde resin “Russian Red”

- **Removal of Hard sitting pastes:**

- Burs , Ultrasonic tips (accessible straight portion of the canal)
- Precurved small hand files (apical area)
- Use of Solvent (Endosolve – R, Septodent)



(Endosolve – R, Septodont)

Removal of Silver Point

