

Lecture 9: Clinical Steps

By Dr Cheryl Fu

Based on slides by Dr Matsubara



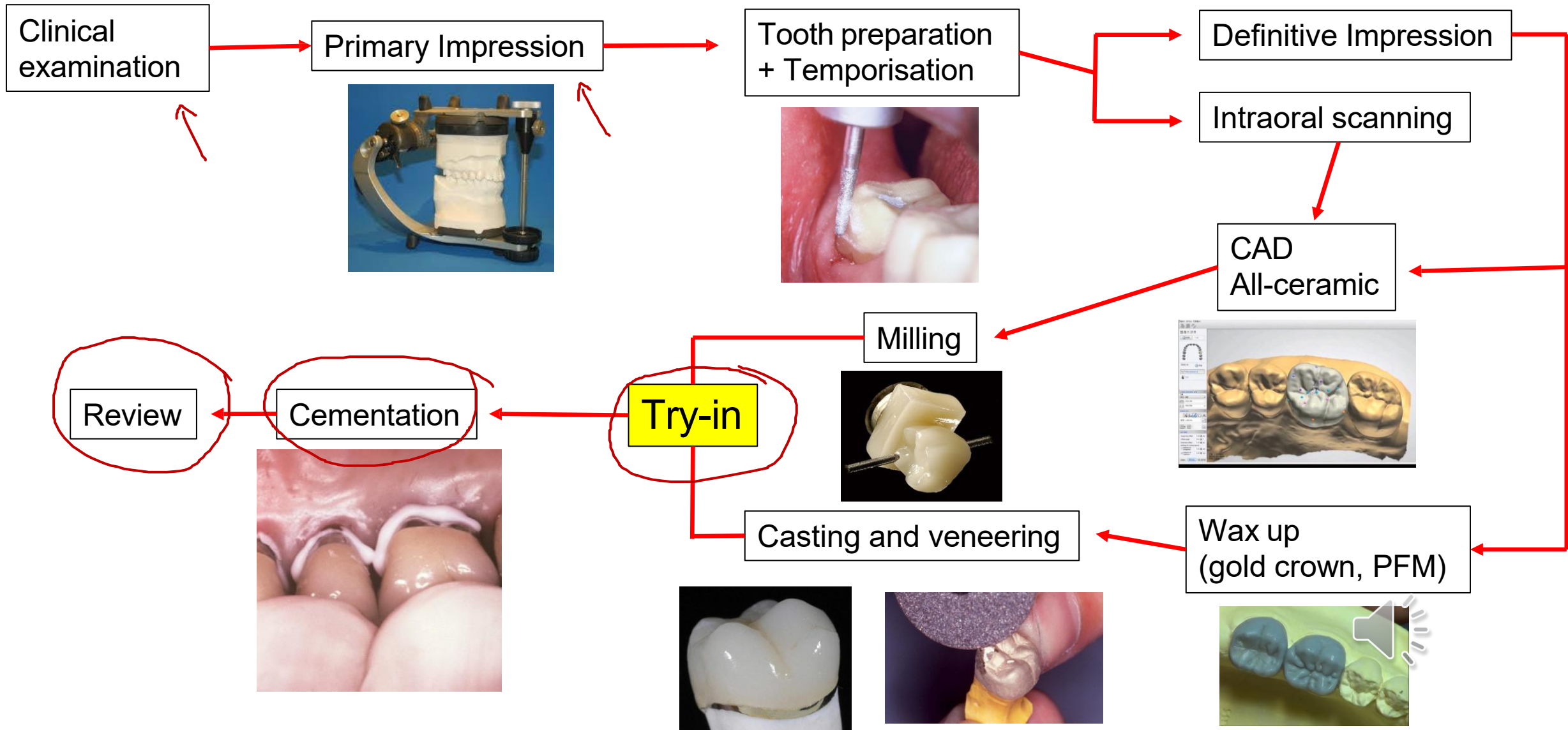
Learning Objectives

- The “big picture” of indirect restorations
- Clinical steps for treatment planning, preparation stage and insert
- Assessing the permanent crown

No reading for this lecture!



The “big picture”



Treatment planning

- Assessing the tooth (+assessing all the dentition and the patient)



- Assessing the tooth (+assessing all the dentition and the patient)

Why Does a Tooth Need a Crown?



Considerations for a crown:

- Destruction of tooth structure**
- Aesthetics
- Plaque Control/Moisture Control
- Retention**

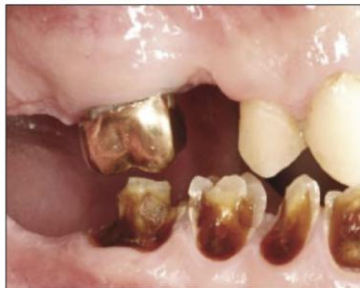

Figure 3a.

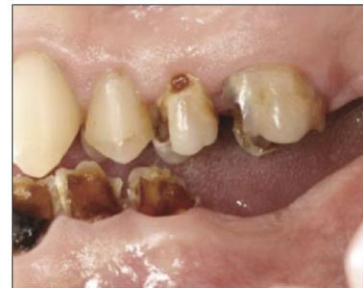

Figure 3b.

Figure 3. Patients abusing methamphetamine often present with rampant caries.
(Photos courtesy of Dr. Jimus Emrani)

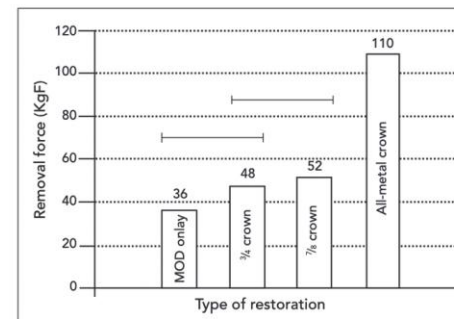


Fig 6-1 A comparison of resistance to removal forces for four types of crowns ($P = .05$).^{1,2} MOD, mesio-occlusodistal.

Fundamental of Fixed Prosthodontics

Lecture 1!



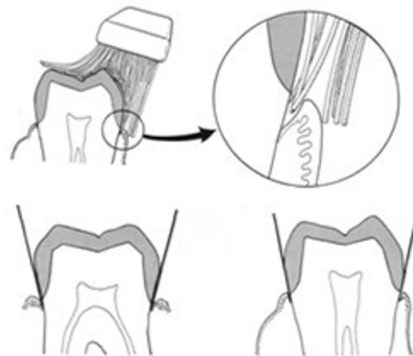
- Assessing the tooth (+assessing all the dentition and the patient)

Principles of Tooth Preparations



ABUTMENT TOOTH

- Principles of tooth preparation
- Partial or complete preparation



BIOLOGICAL

- Conservation of tooth structure
- Avoidance of overcontouring
- Supragingival margins
- Harmonious occlusion
- Protection against tooth fracture

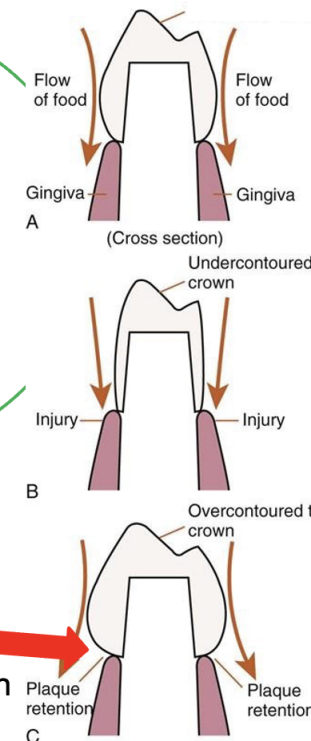
MECHANICAL

- Retention form
- Resistance form
- Deformation

AESTHETIC

- Minimum display of metal
- Maximum thickness of porcelain
- Porcelain occlusal surfaces
- Subgingival margins

Patient can't clean this!



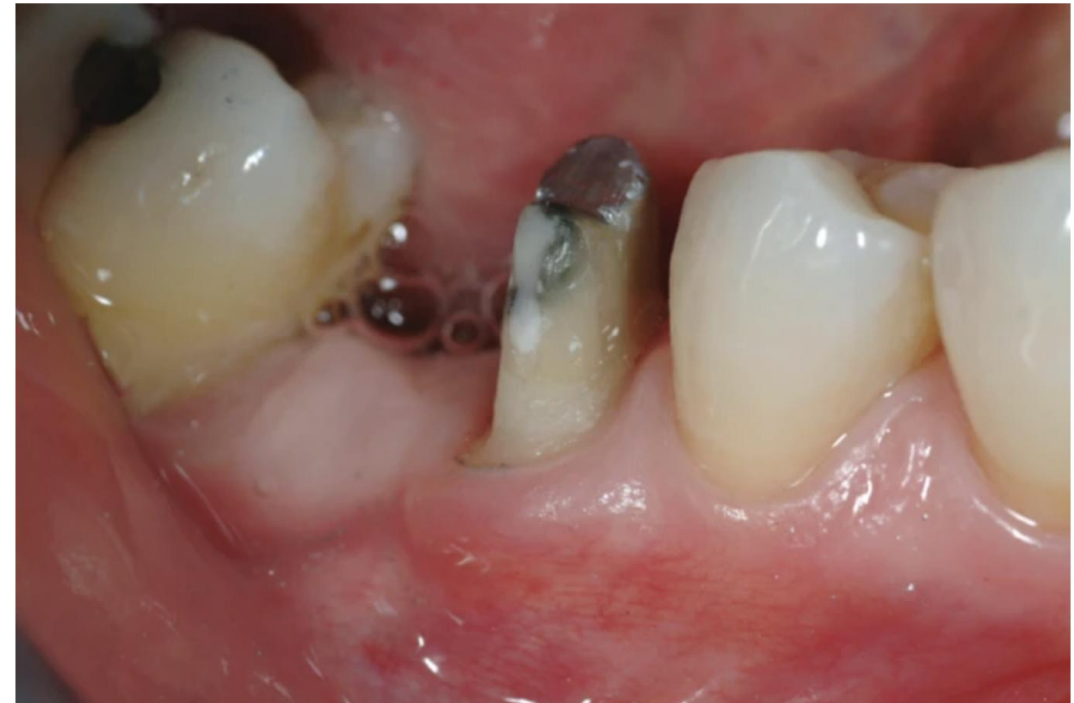- Assessing the tooth (+assessing all the dentition and the patient)

”Between 3 and 25% of teeth prepared for full coverage crowns will lose vital pulp functions within 15–20 years, with previously compromised teeth fairing worse than those that are more intact”

[Home](#) > [Extra-Coronal Restorations](#) > Chapter

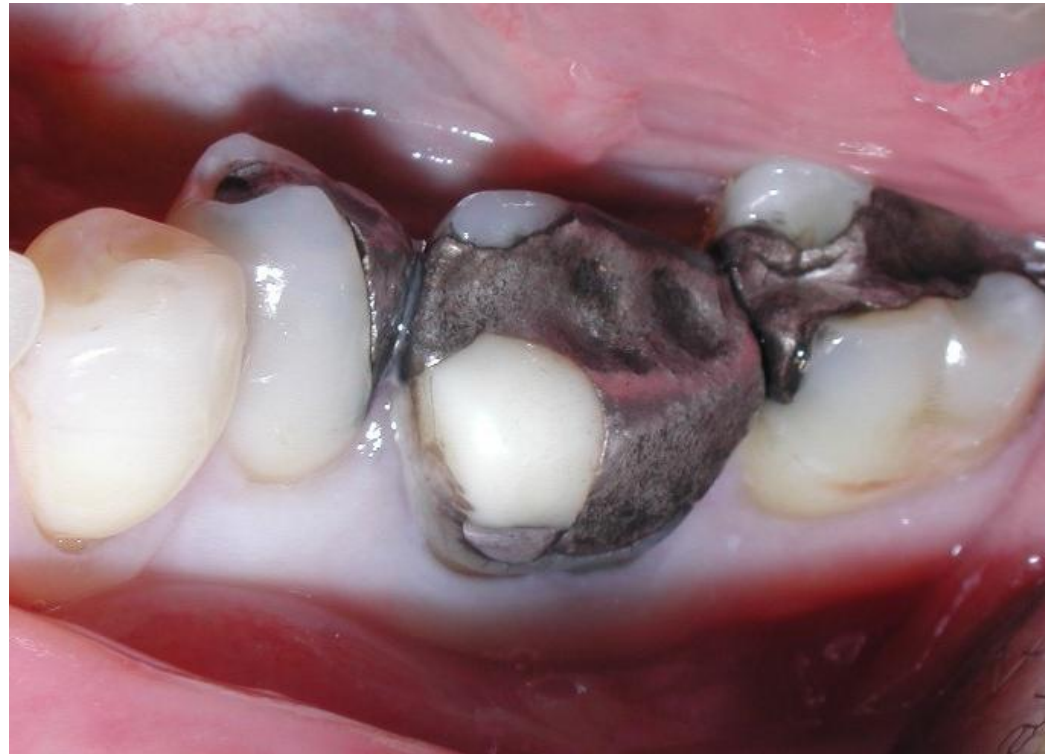Preserving Pulp Vitality

Chapter | First Online: 01 August 2018



Many teeth prepared for extra-coronal restorations have already endured cycles of disease and direct restoration. They should be evaluated carefully before preparation to minimise the risks of unexpected pulp breakdown. In this case we see a prepared lower premolar with multiple amalgam restorations and a buccal composite repair that make up the core

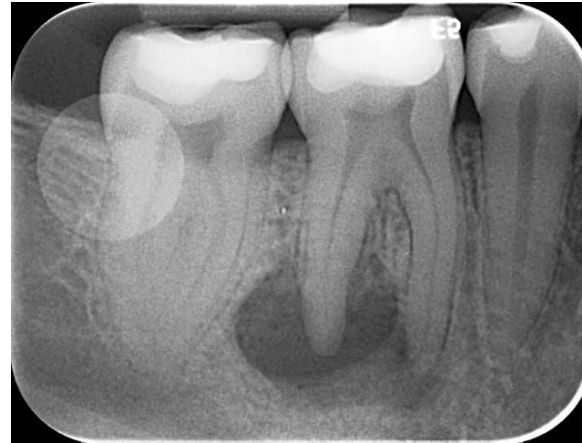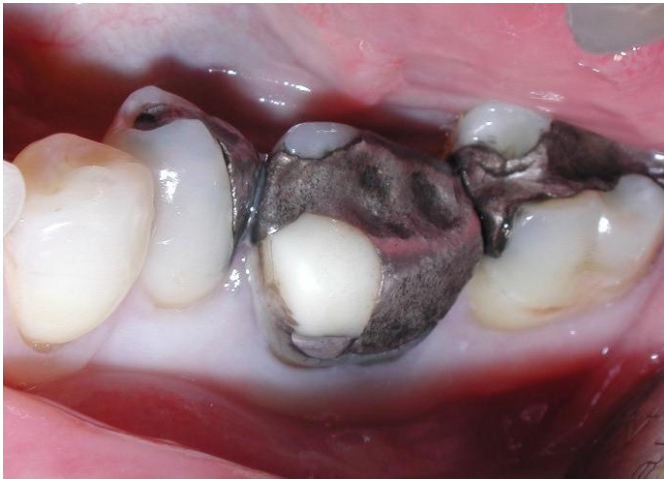Treatment planning



Would you crown this tooth?

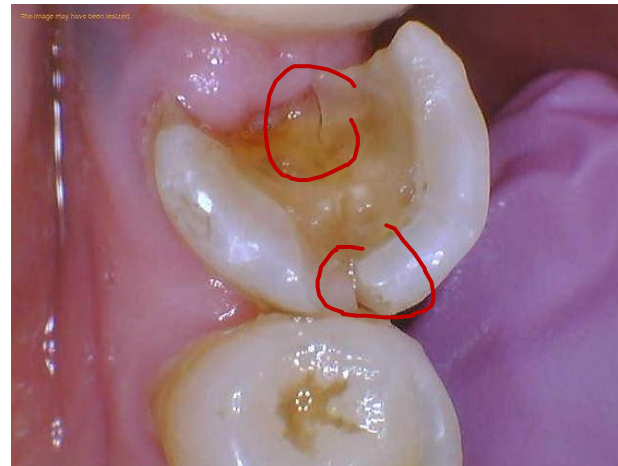

Treatment planning



This is obviously not a radiograph of the same tooth, I just found an image from Google

What if you took a PA and saw this?
Would that change your treatment plan?



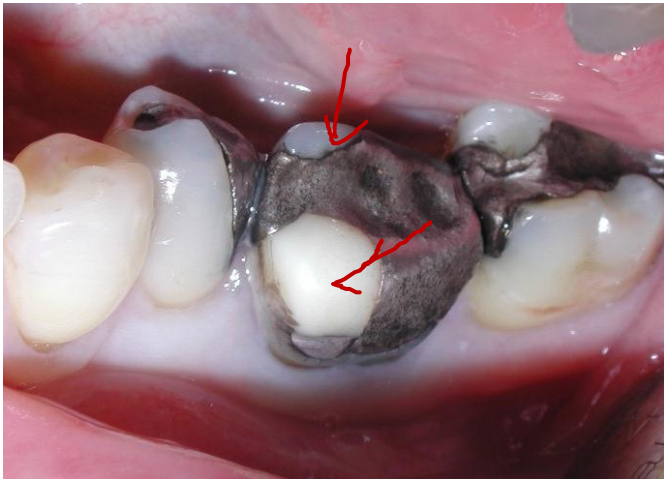
This is obviously not photo of the same tooth, I just found an image from Google

What if you removed the restoration and saw this? Would that change your treatment plan?

Well, it depends on the exact clinical scenarios

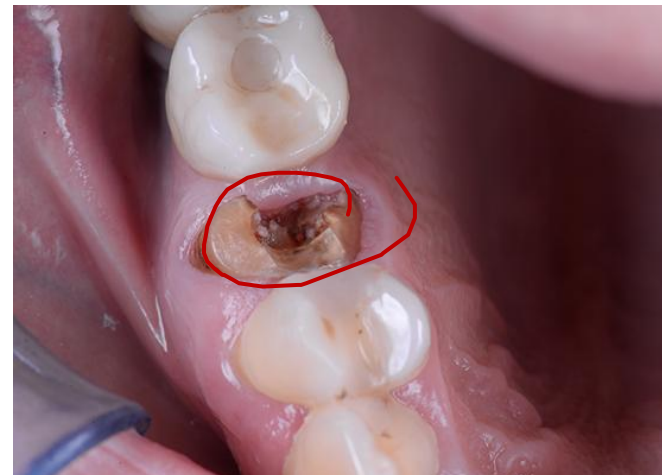

Treatment planning



What if that tooth was acting as an abutment tooth for an elderly patient?

Well, it depends on the exact clinical scenarios



This is obviously not a radiograph of the same tooth, I just found an image from Google

What if after restoration removal this was all that was left of the tooth?



Some pearls of wisdom:

- Carry out all investigations that COULD potentially change your treatment plan
- Not every tooth NEEDS a crown even if it meets the indications (It depends on the combination of unique clinical factors)
- Think about if your treatment is really going to benefit the patient (weighing against the financial+time commitments of the patient)



- **Before patient arrives:**
 - Decide on material of choice. Why is that material the best?
 - Approval of treatment plan (more on this later)
 - Wax up of tooth if any modifications require for existing tooth+ putty key
- **Day of preparation**
 - Bring patient in, confirm treatment with them quickly, make sure they know what's happening
 - Administer LA. (If you don't have up to date opposing model because you did other restorative work since the diagnostic model, then take new impression. If you don't have putty key, do it now)
 - Prep tooth according to guidelines for the correct materials. Check for undercuts and sufficient occlusal clearance
 - Make provisional restoration
 - Retraction cord+expasyl
 - Impressions, remove retraction cord!
 - Temporise

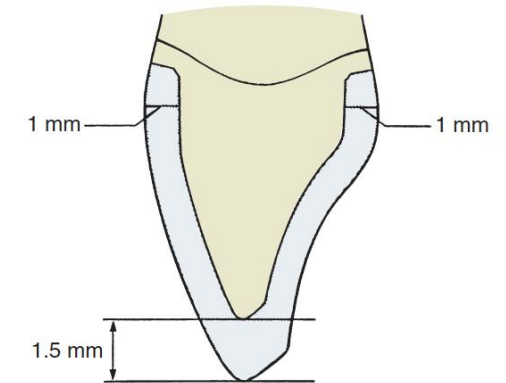


FIGURE 11-1 ■ Recommended reduction for all-ceramic crowns.

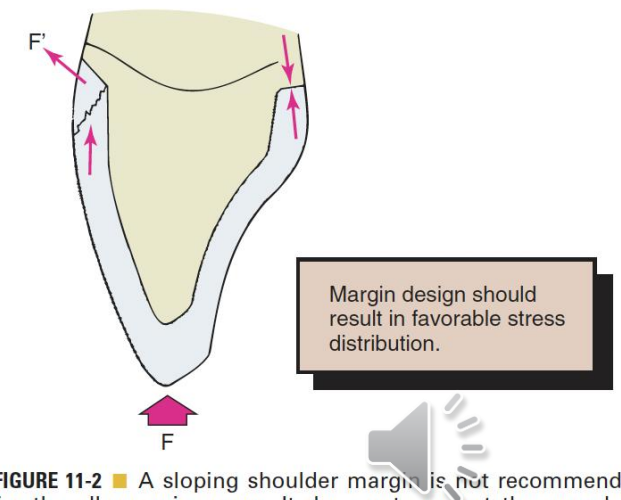


FIGURE 11-2 ■ A sloping shoulder margin is not recommended for the all-ceramic crown. It does not support the porcelain. Incisal loading leads to tensile stresses near the margin if the forces are not reciprocated (arrows), which may cause brittle failure. *F*, Force.

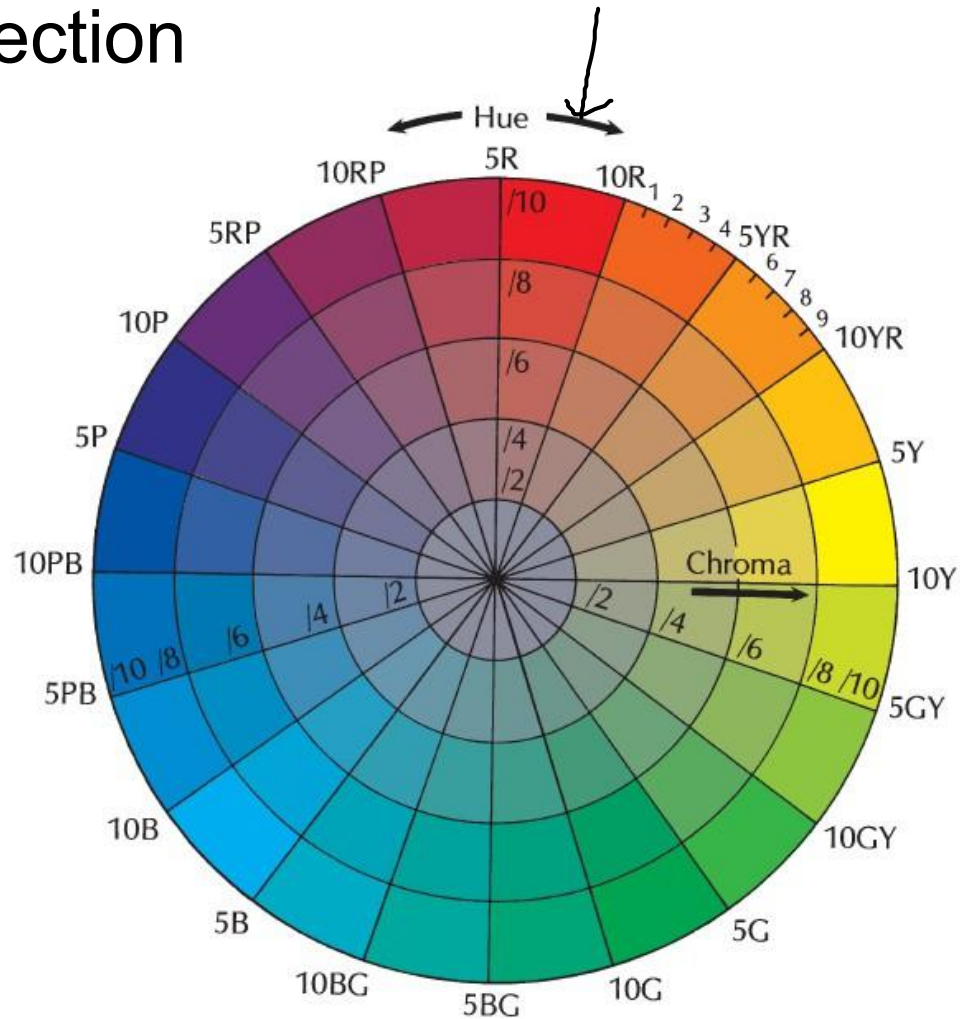
Several methods of shade selection:

- Shade tabs (different methodologies)
- Digital shade selection (may be built into intra-oral scanners)
- Send patient to lab



Shade Selection

- Hue
- Chroma
- Value



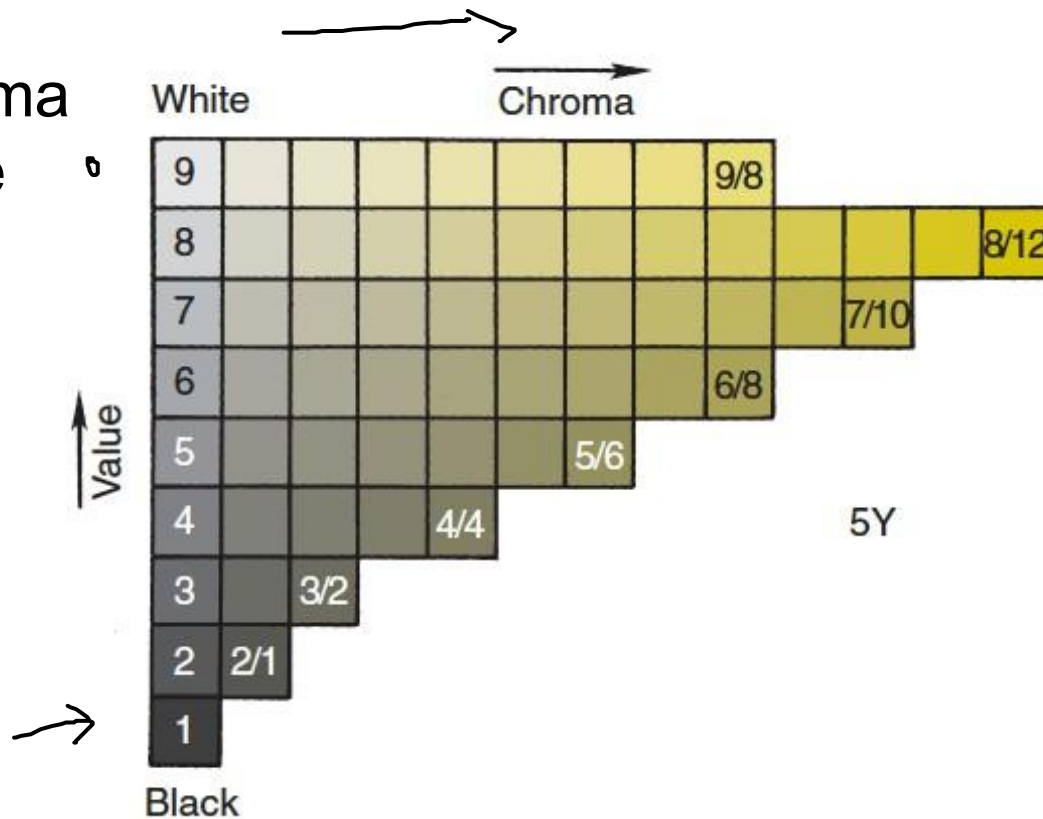
Hue: the particular variety of a color.
e.g. Blue, red, green, yellow, etc.

Chroma (saturation): the
intensity of a hue.



Shade Selection

- Hue
- Chroma
- Value



Hue: the particular variety of a color.
e.g. Blue, red, green, yellow, etc.

Chroma (saturation): the
intensity of a hue.

Value: the relative lightness or
darkness of a color



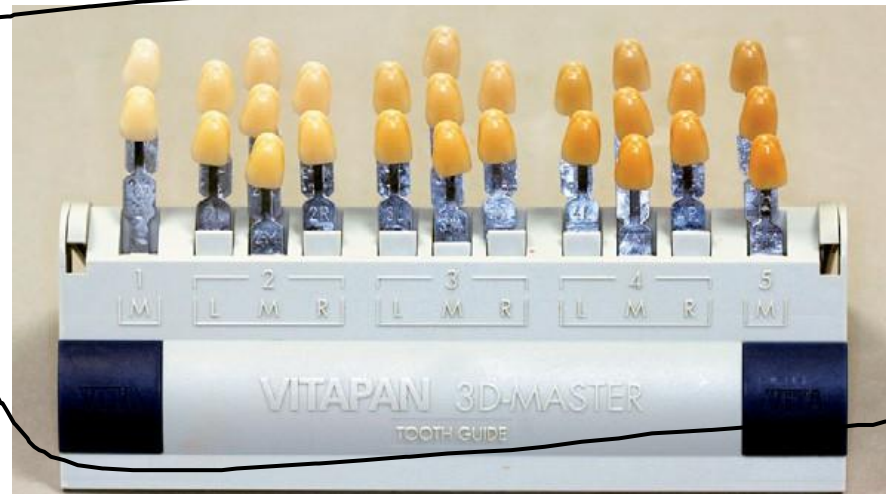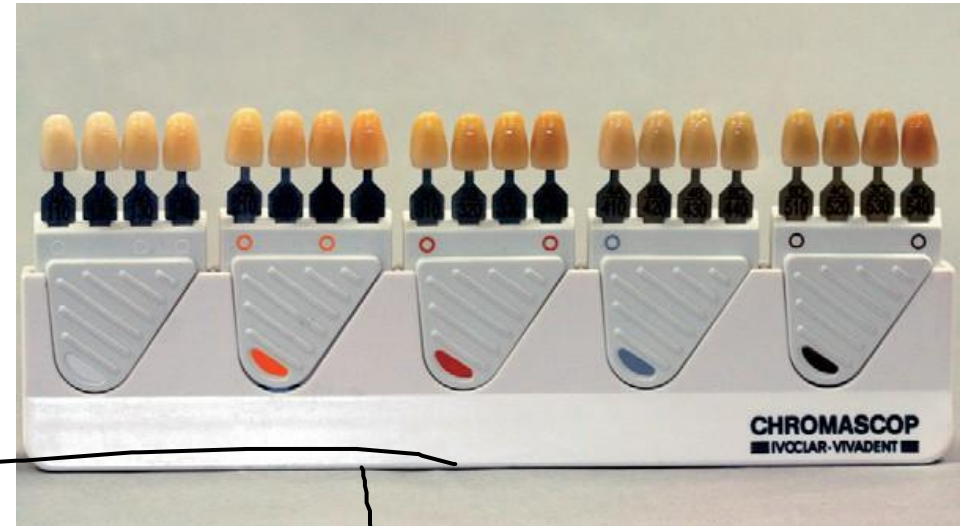
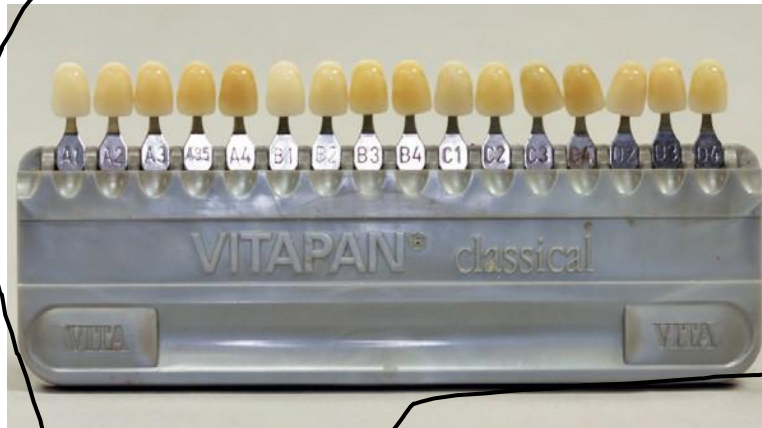
Clinical Sequence



Shade Selection



Shade guides




Shade Selection

Shade guides

VITA

Chroma and Value



1° Hue
2° Chroma
and value

A
Orangeish

B
Yellowish
Hue

C
Yellow/grayish

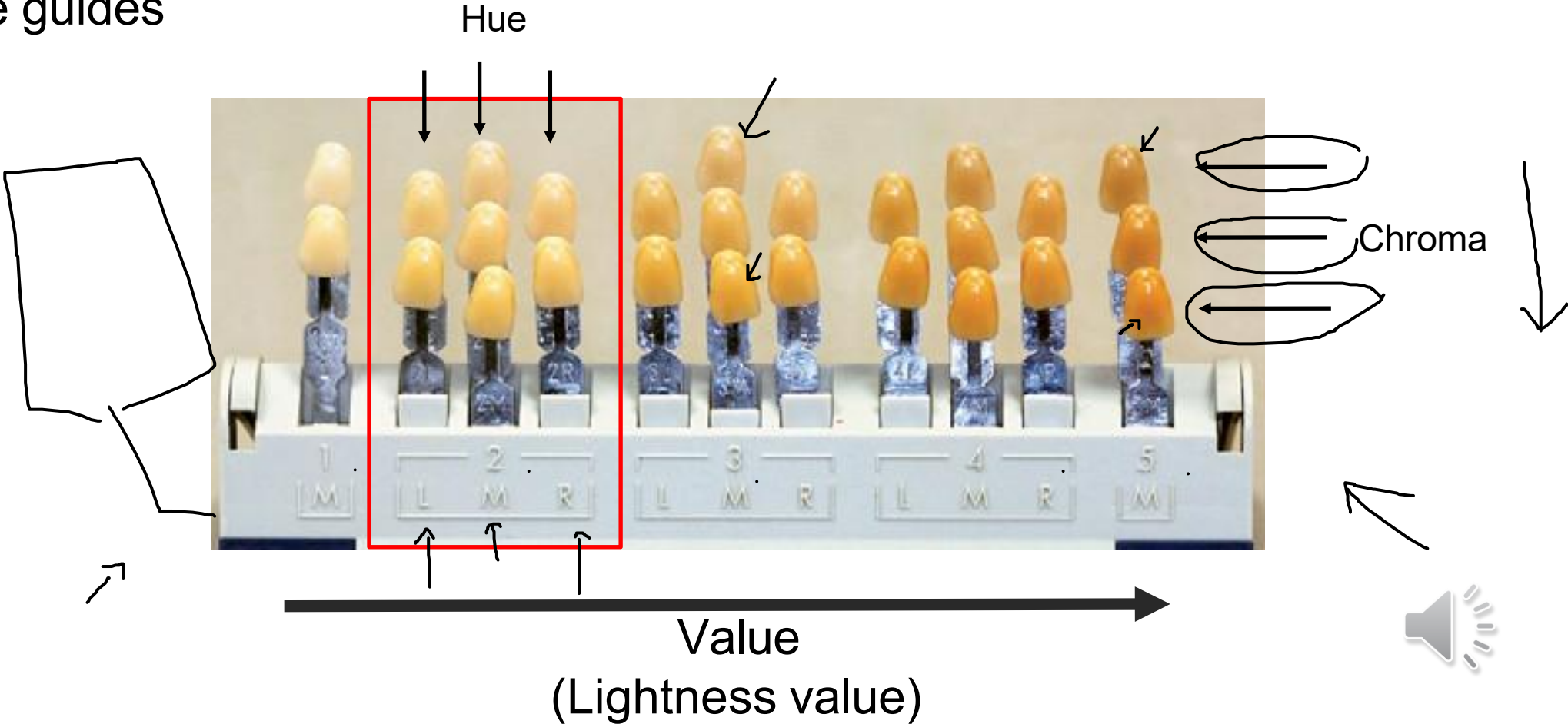
D
Orange/grayish



Shade Selection

Vitapan 3D-Master

Shade guides



Clinical Sequence




THE UNIVERSITY OF
**WESTERN
AUSTRALIA**



Oral Health Centre
of Western Australia

Shade Selection

Shade guides



1° Value



Light Dark

Value
(Lightness level)

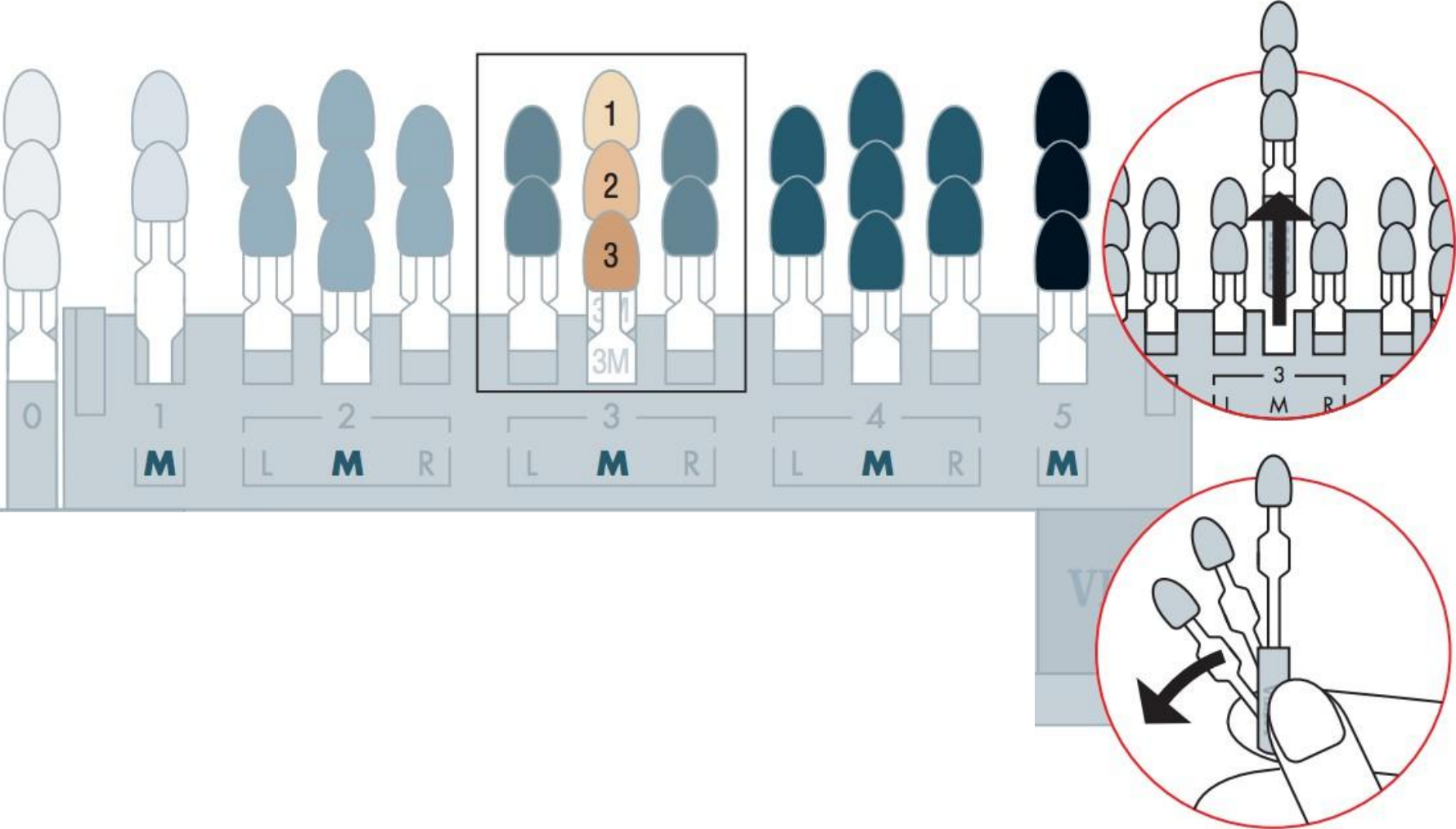
Clinical Sequence

Shade Selection

Shade guides

1° Value

2° Chroma



Clinical Sequence

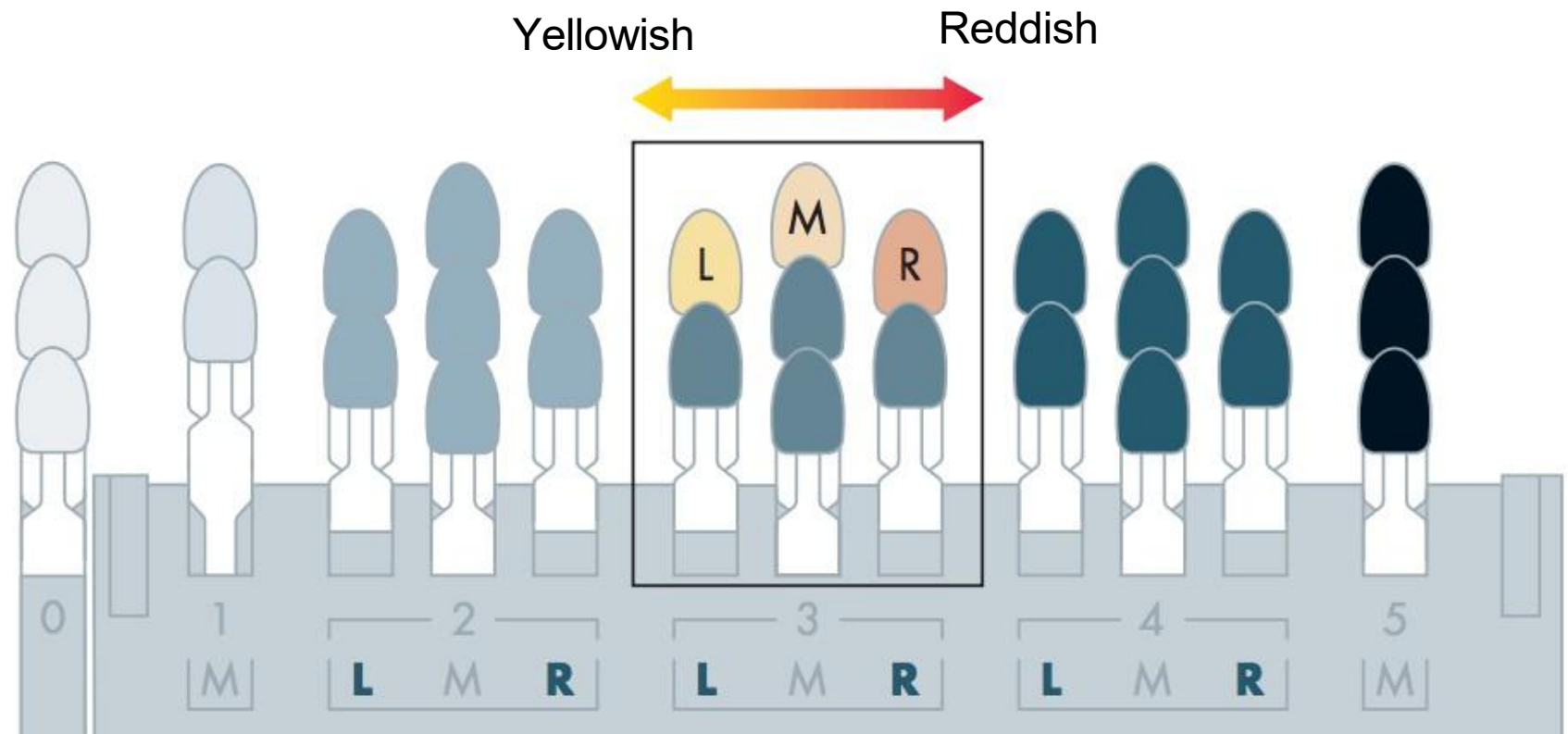
Shade Selection

Shade guides

1° Value

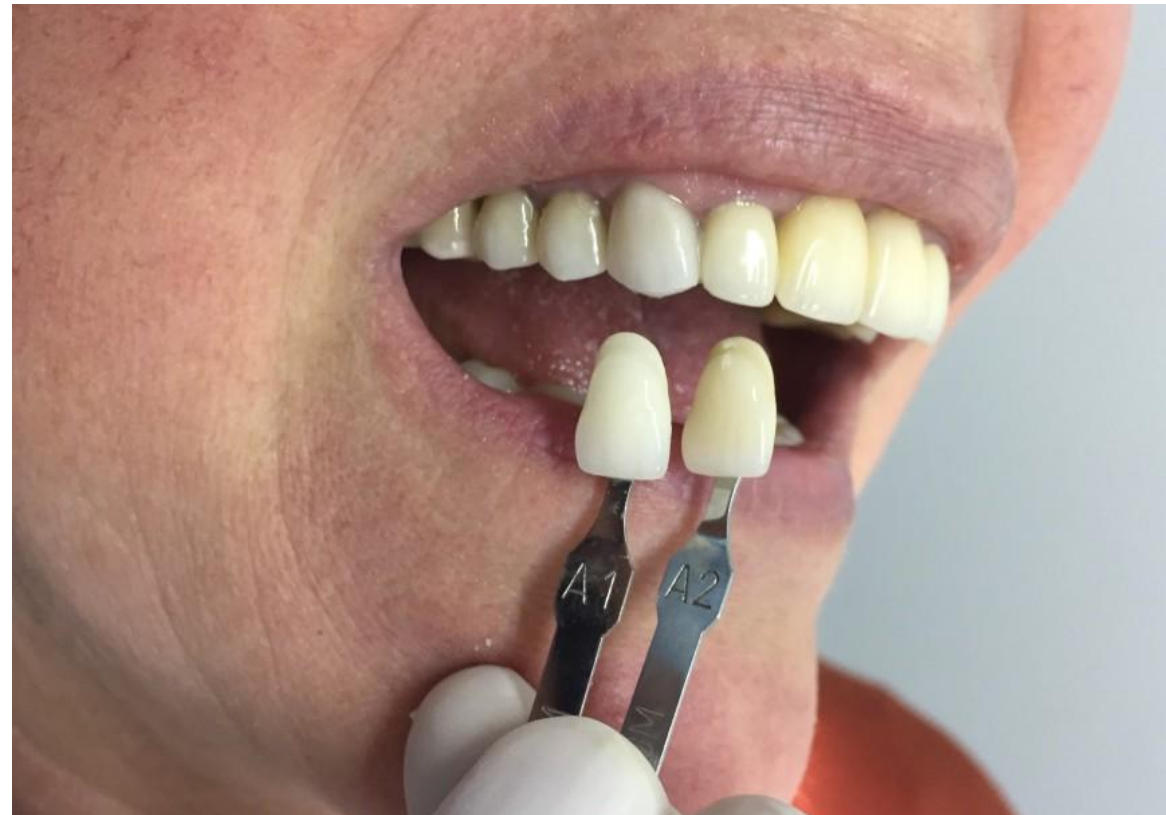2° Chroma

3° Hue



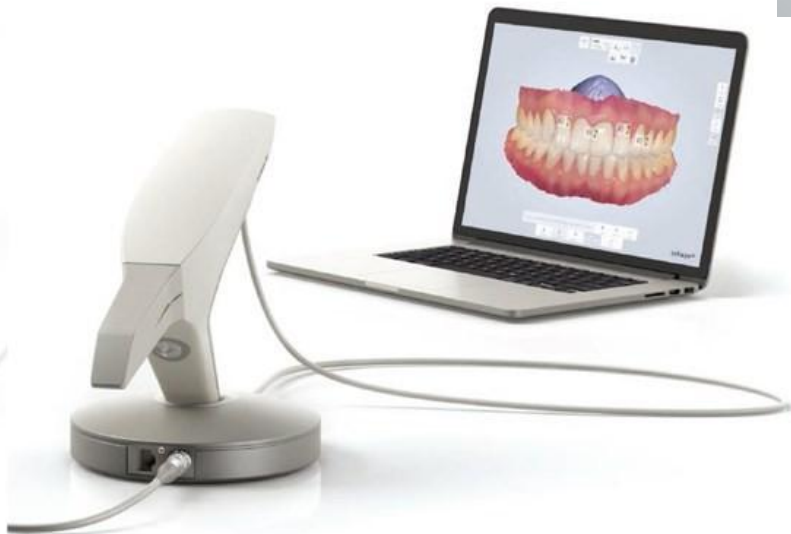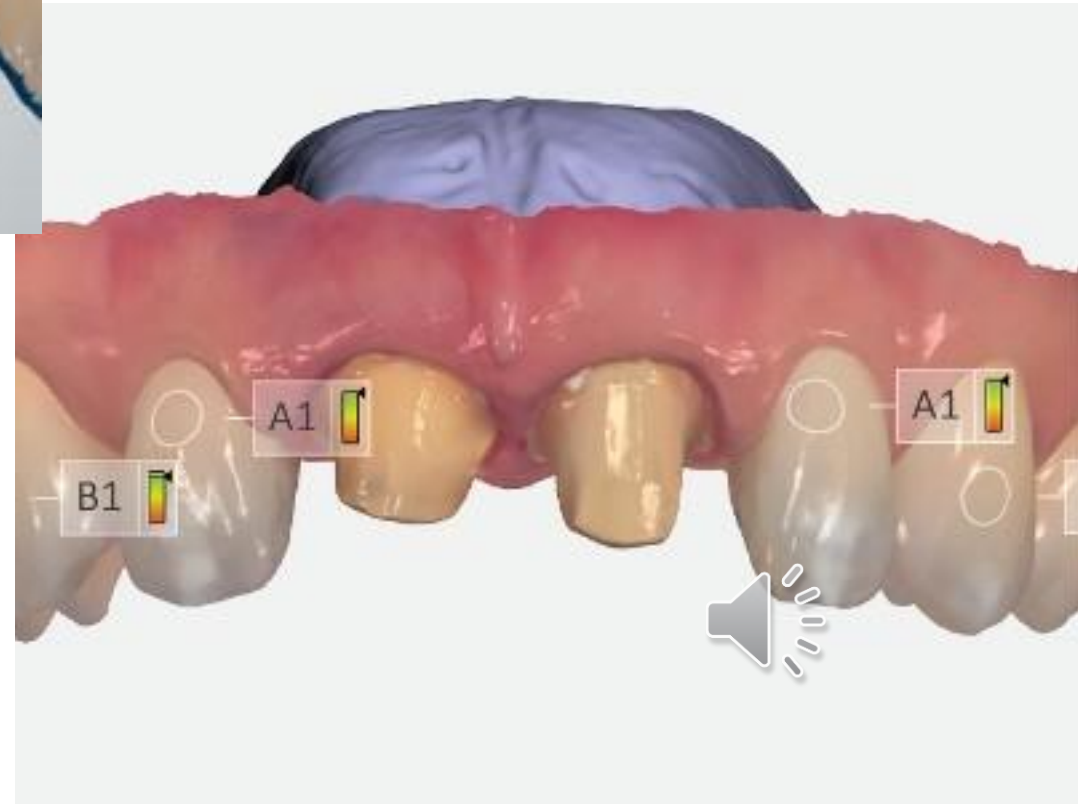
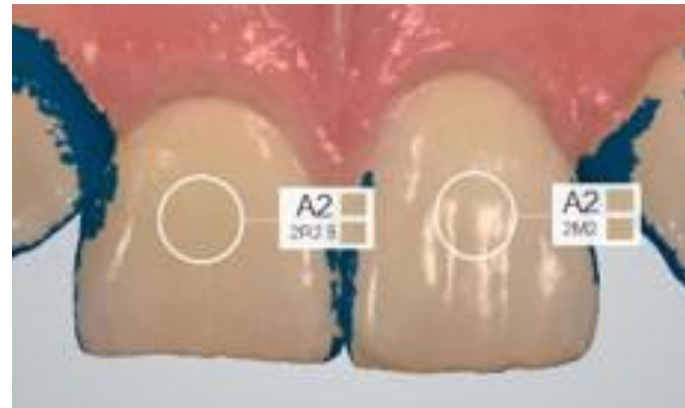Shade Selection

Photographs with the shade guide



Shade Selection Digital Systems

TRIOS intra-oral scanner (3Shape)



Shade Selection Digital Systems

In vivo tooth-color measurement with a new 3D intraoral scanning system in comparison to conventional digital and visual color determination methods.

- Dentists and Dental technicians – Vita 3D Master
- 3Shape Trios
- Vita Easyshade (2 models)
- SpectroShade (2 models)

Negligible clinical differences between conventional method and Trios
No significant difference between digital systems



Evaluation: Seating, fitting, contact points

Systematic approach

1. Evaluation of the crown on the die
2. Seating the crown on the prepared tooth
3. Assessment of the seated crown



Lab steps

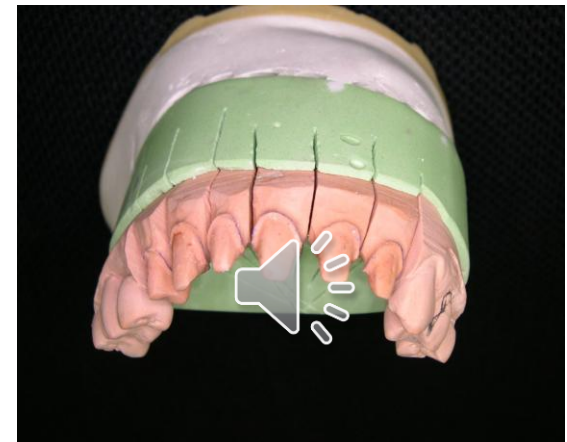
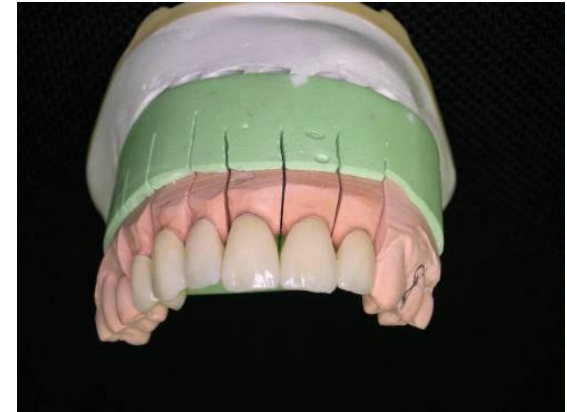After the crown is returned from the lab we must check the crown.



EVALUATION OF CROWN ON THE DIE

Aims:

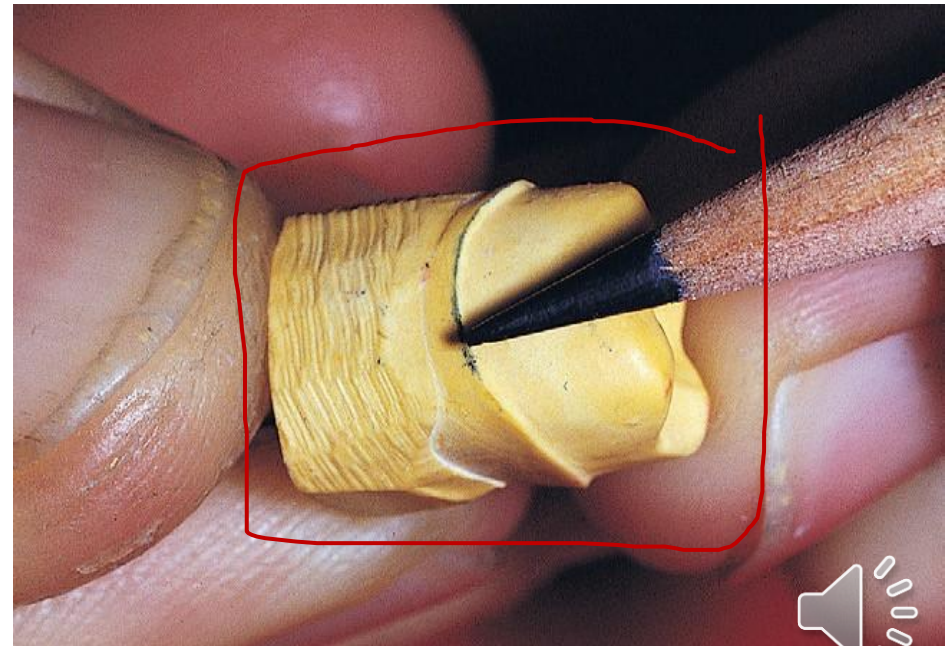
- Detection of fabrication errors (laboratory related) prior to the clinical appointment
- Save critical chair time
- Anticipation of problems before clinical appointment
- Consider good lighting and magnification
- In case of problem, consult with the dental laboratory



EVALUATION OF CROWN ON THE DIE

Assess the die and opposing model

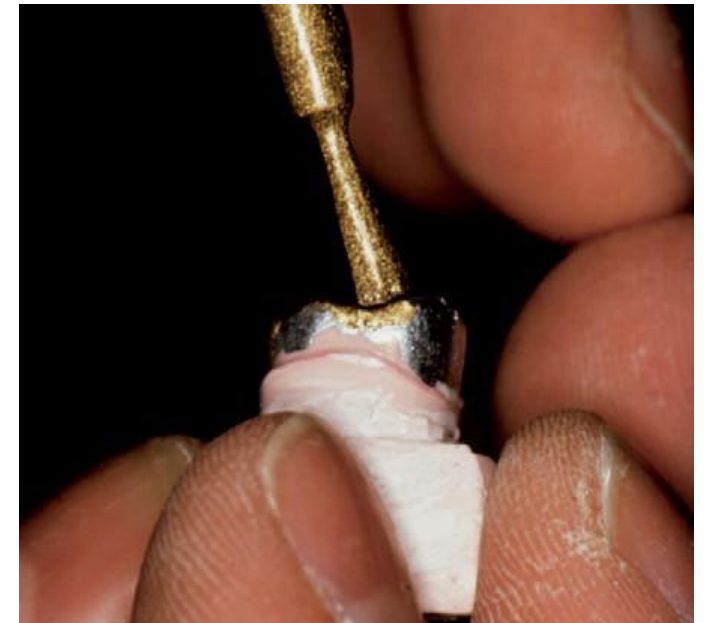- Poor pouring ←
- Overtrimming ←
- Fracture ←
- Scratches ←
- Wear ←



EVALUATION OF CROWN ON THE DIE

Internal surface:

- Casting problems: air bubbles ←
- Casting nodules or blebs ←
- Ideally, the casting should touch the die at the margins only



Die spacer 

EVALUATION OF CROWN ON THE DIE

Overall fit and resistance:

- Looseness 
- Excessive gap 
- Proximal contact areas 

Marginal fit:

- Open margins
- Overhangs or underextensions



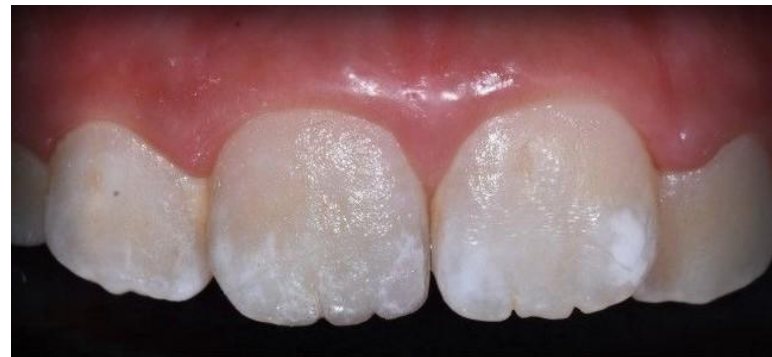EVALUATION OF CROWN ON THE DIE

External surface

- Appearance (restoration design)
- Contour
- Shade
- Rough or smooth (polished)

Occlusion (articulator)

- Centric contacts
- Eccentric contacts
- Interferences



Insert Appointment:

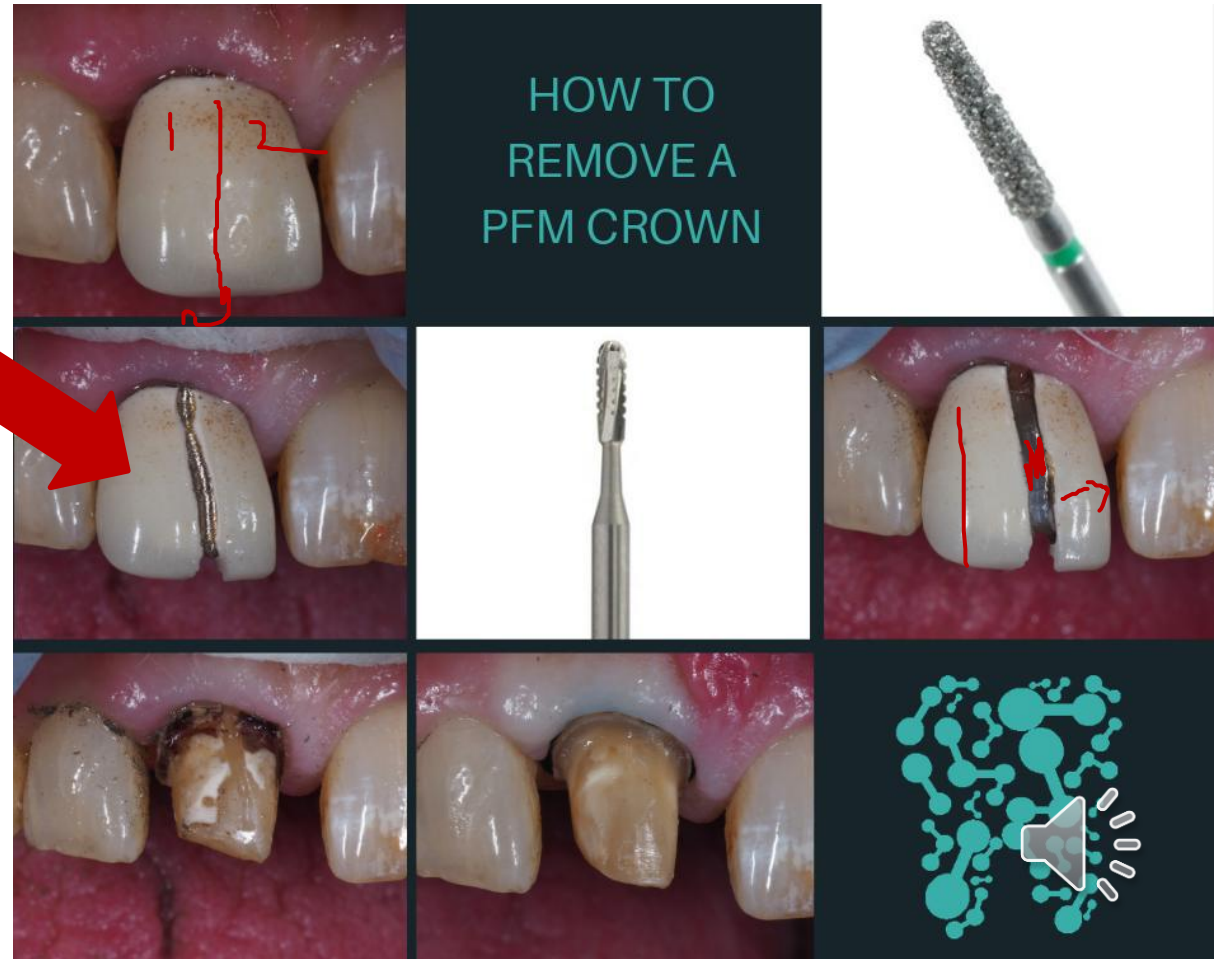- Bring patient in, administer LA if required
- Remove temporary crown. Can sometimes wiggle it off. If not possible, carefully section temp crown and break the temporary.
- Clean off temporary cement with ultrasonic scaler
- Try-In



SEATING THE CROWN

Remove the provisional restoration

- Excavator, sickle probe
- Hemostat, Backhaus forceps, pliers
- Crown remover:
 - Back-action crown remover
 - Automatic crown remover
 - Richwill crown remover



IDEAL CROWN

- Easily seated
- Stable
- Accurate occlusal contact
- Adequate proximal contacts
- Accurate marginal fit
- Aesthetic



SEATING THE CROWN

- The crown should seat on the prepared tooth without forcing
- If it is not seating, possible **causes** may involve:



SEATING THE CROWN

- The crown should seat on the prepared tooth without forcing
- If it is not seating, possible **causes** may involve:

Single crown

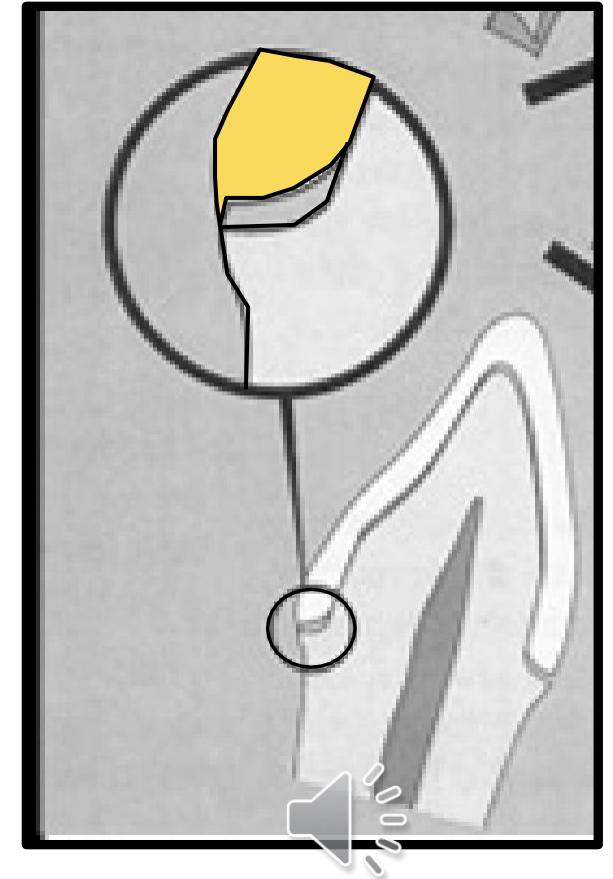
Proximal contacts

Internal fit

Inaccurate margins/ over extensions

Retained temporary cements

Trapped gingival tissue



Order to check:

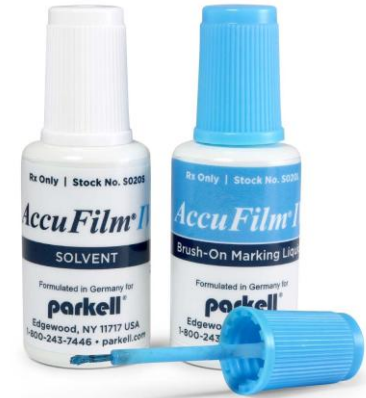- a) Proximal contact
- b) Internal fit
- c) Marginal fit



SEATING THE CROWN

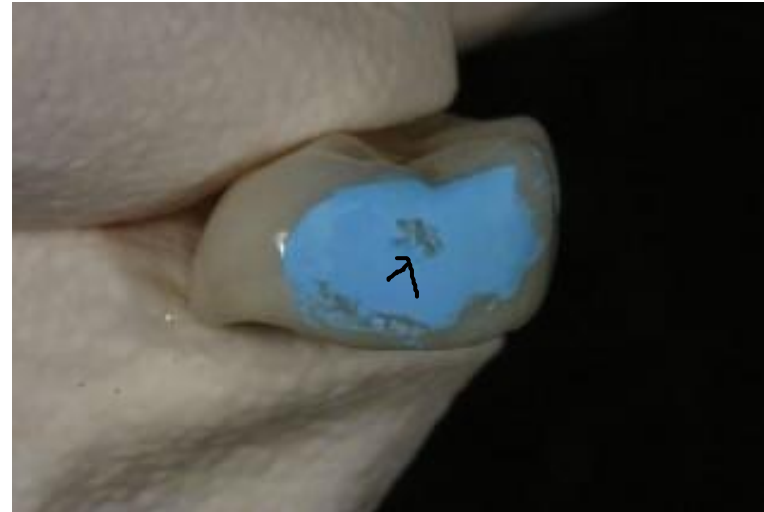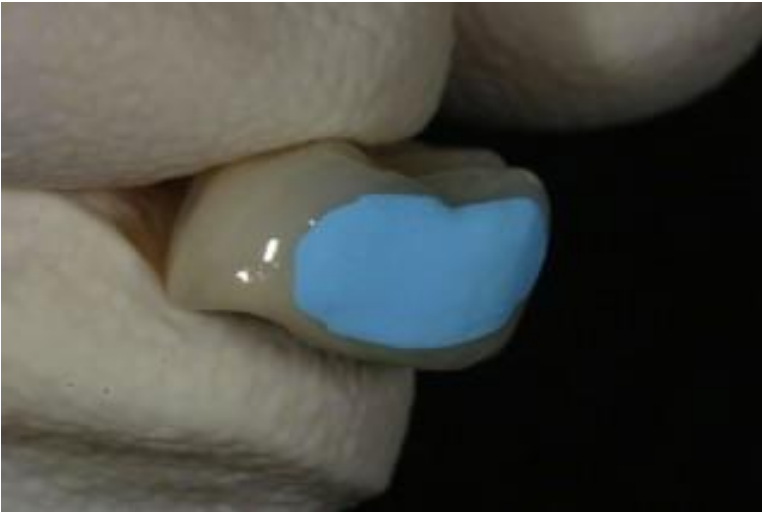Proximal contacts

- Assess tightness with dental floss
- There should be some tightness but not too difficult
- Articulating paper (20 μm), marking liquid (Accufilm), spays (occlude)
- The shim stock (8 μm) should just pass through the contact
- Minor adjustment at a time
- If the contacts are open, return to the laboratory for material addition



SEATING THE CROWN

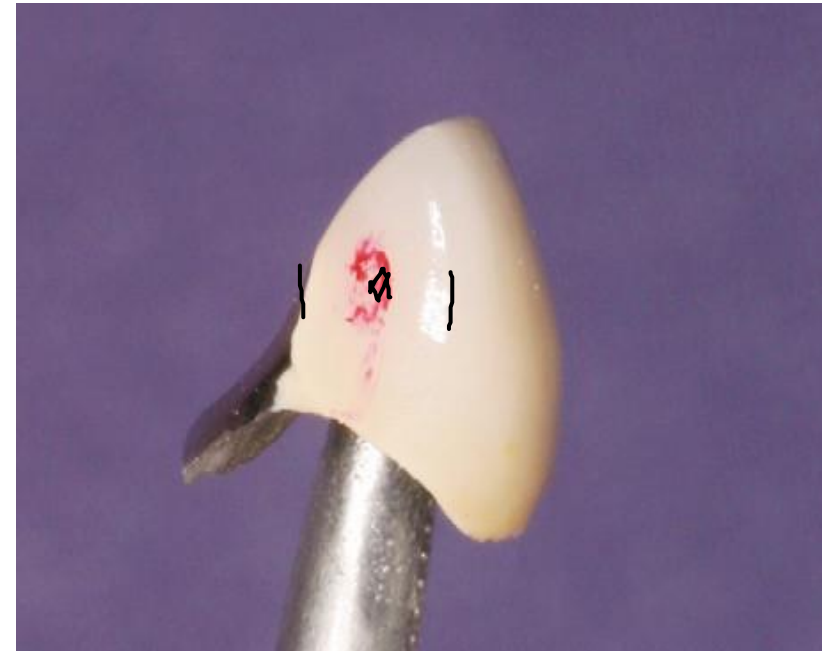
Proximal contacts



SEATING THE CROWN

Proximal contacts

Should be at the same location to the natural proximal contacts



SEATING THE CROWN

Internal fit

- ▶ The restoration should seat completely without interference of the occlusal or axial surfaces
- ▶ The fitting surface should be checked and adjusted accordingly
 - Disclosing medium (Fit Checker, LB impression material)
 - Spraying thin layer of aerosol indicator (Occlude)
- ▶ The relief can be achieved with a diamond bur

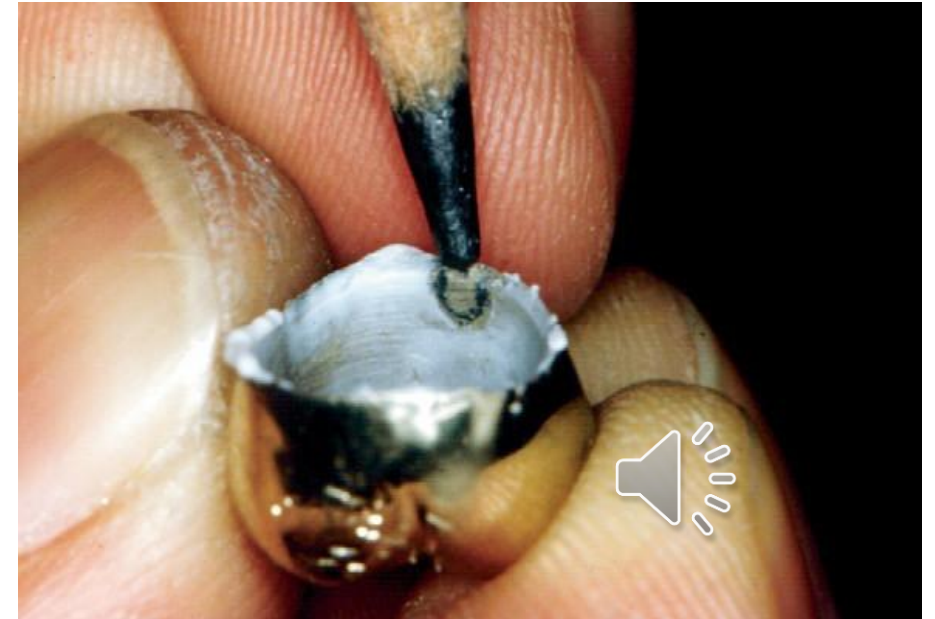
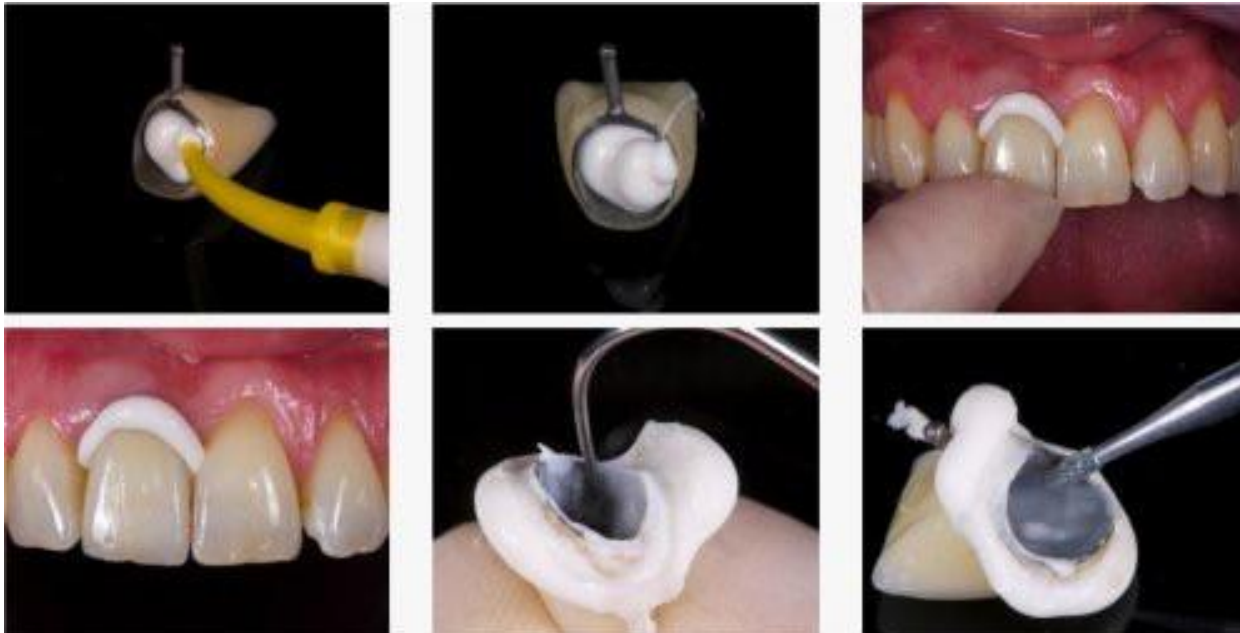

SEATING THE CROWN

Internal fit

Fit Checker application

- Penetrated areas of the medium indicate high spots
- Can be adjusted accordingly




SEATING THE CROWN

Internal fit

If crown fits the model well but does not seat in the mouth, consider problems with impression

Caused by:

- Early impression removal
- Distortion of impression
- Latex contamination



Take a new impression



SEATING THE CROWN

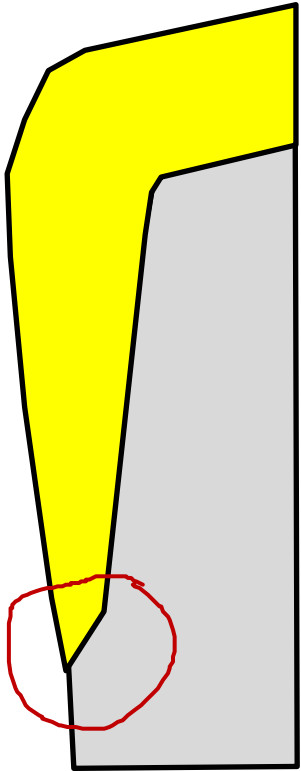
Marginal fit

- Should be as accurate as possible
- Poor marginal adaptation:
 - Gap (100 micron is the borderline for acceptability)
 - Overhang
 - Under extension
 - Ledge

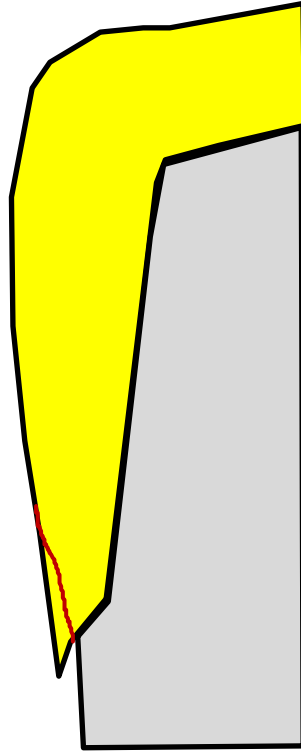


SEATING THE CROWN

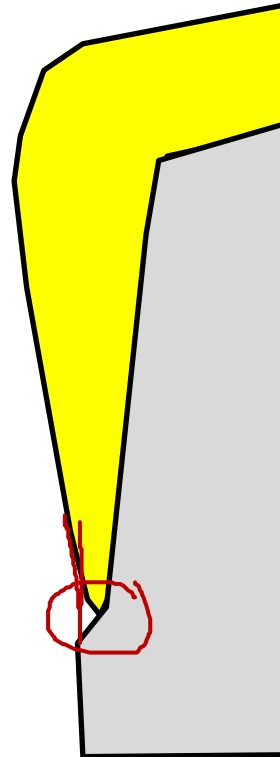
Marginal fit




Ideal



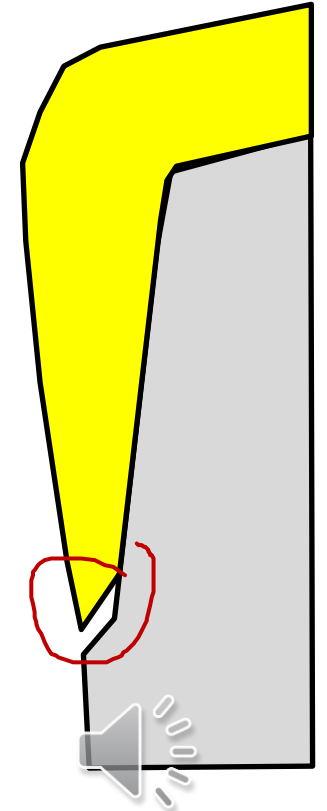
Overextended



Underextended



Overhang



Open margin

SEATING THE CROWN

Marginal fit

Effects of open margins:

- Sensitivity
- Dissolution of cement
- Plaque retention
- Caries
- Gingival inflammation



SEATING THE CROWN

Marginal fit

- ▶ Poor marginal fit can be due to inability to read the finish line by the technician

Overhangs/overextension: can be adjusted

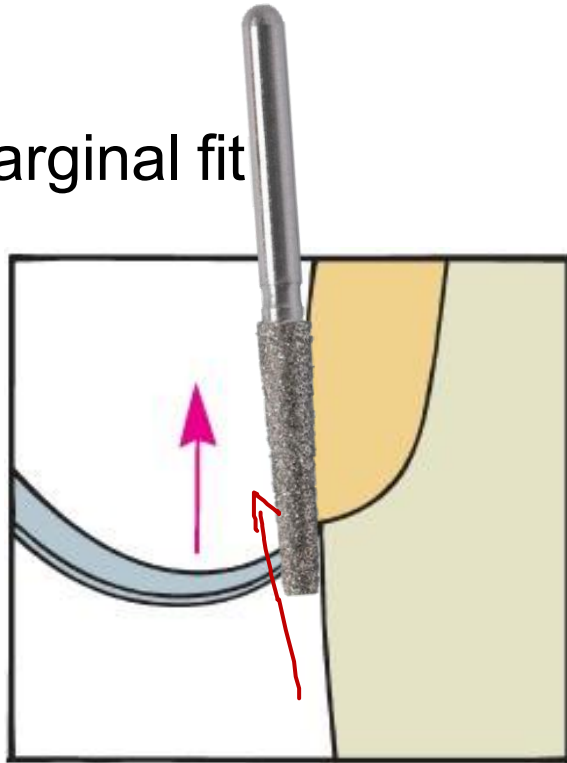
Underextension: may require remake

Gap: require remake

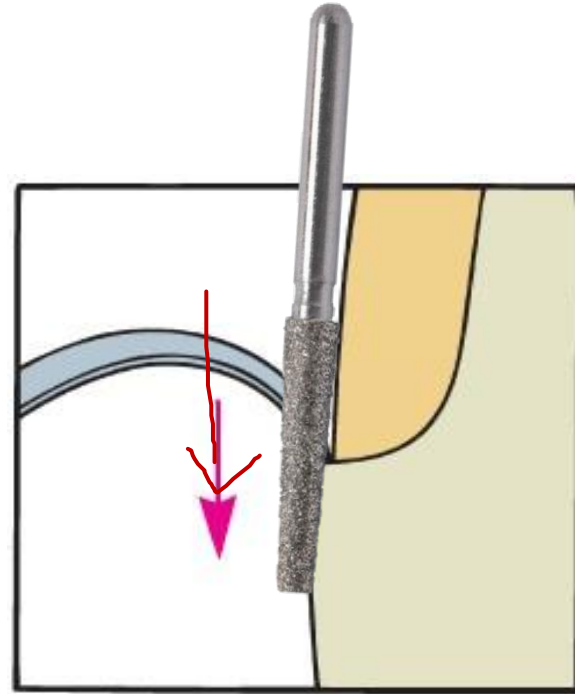


SEATING THE CROWN

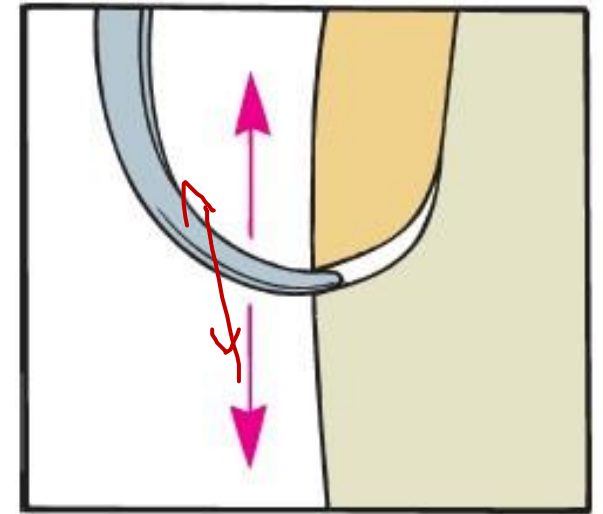
Marginal fit



Gingivo-occlusal direction



Occluso-gingival direction



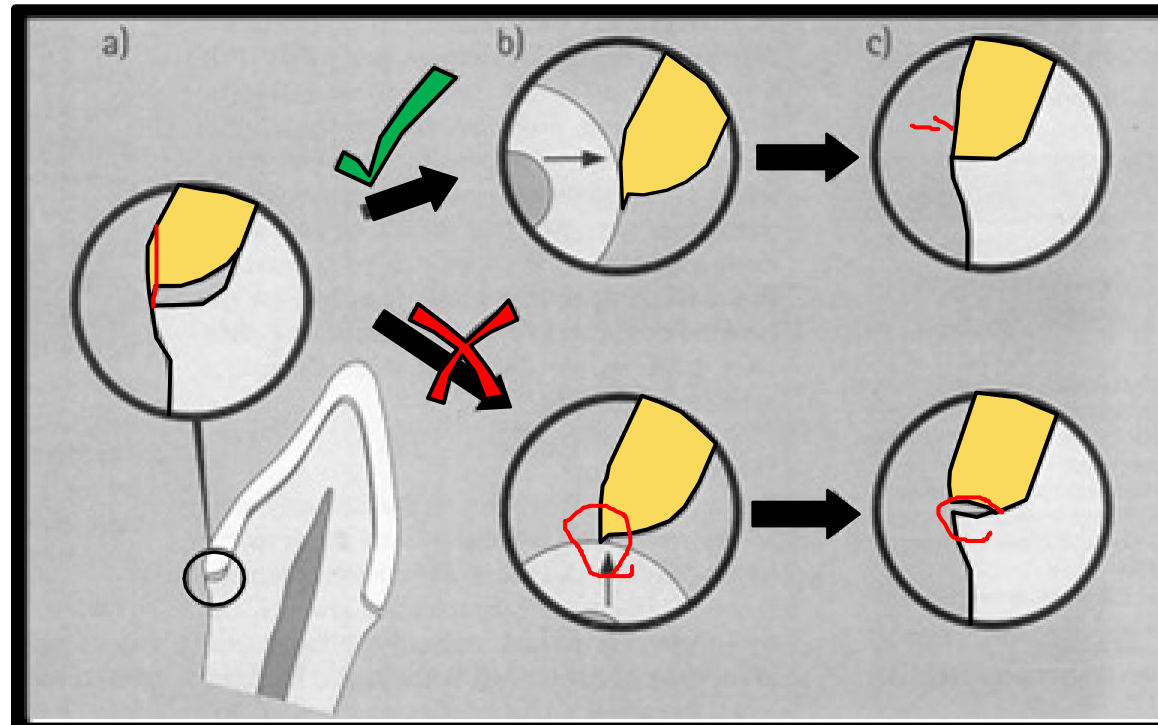
Both

New impression 

SEATING THE CROWN

Marginal fit

Adjust overextended margins or overhangs from the external surface, not the fitting surface



ASSESSMENT OF THE SEATED CROWN

Aims

- ▶ Check
 - Stability
 - Contour
 - Occlusion
 - Aesthetics

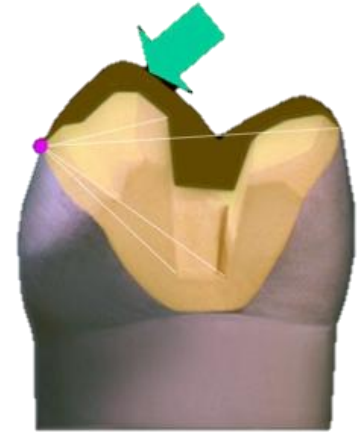
- ▶ Confirm the suitability for cementation



ASSESSMENT OF THE SEATED CROWN

Stability

- Restoration should not rotate when the force is applied
- Instability causes failure in function (mainly in cementation)



internal surface misfit



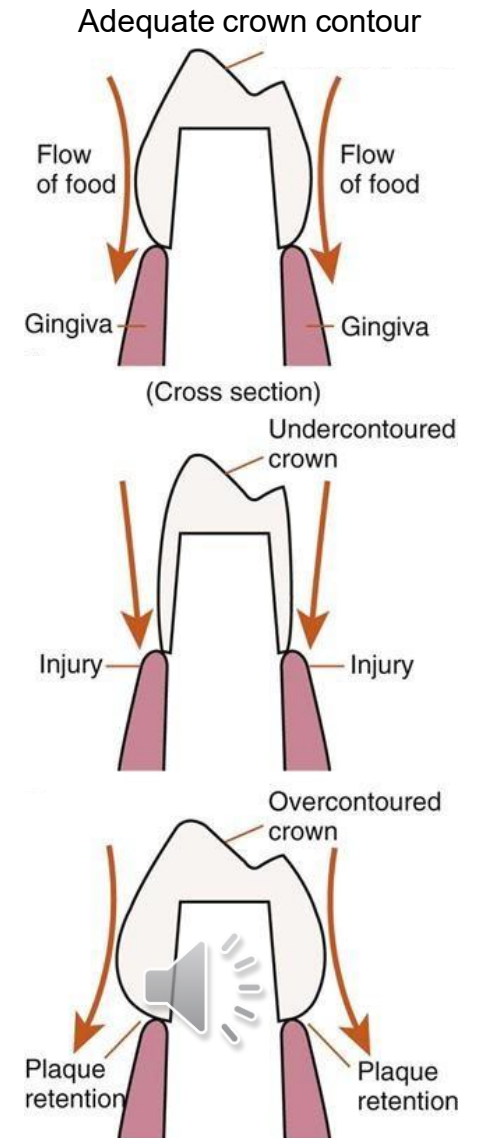
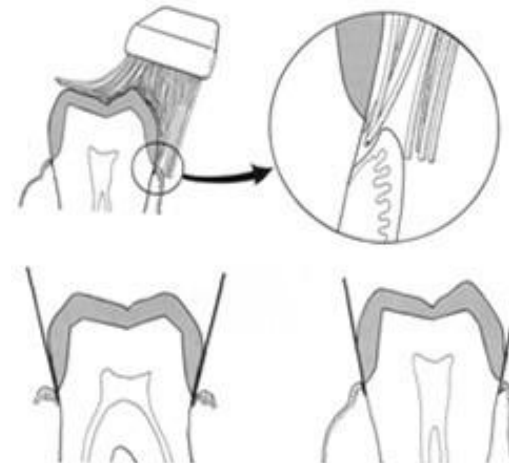
caused by distortion in impression or fabrication process



ASSESSMENT OF THE SEATED CROWN

Contour

- ▶ Improper contour may impair gingival health and affects the natural appearance
- ▶ They must be adjusted before cementation



ASSESSMENT OF THE SEATED CROWN

Occlusion

- The crown should be fully seated
- Major adjustments should be done prior to cementation
- Minor adjustments can be completed after cementation
- Inadequate occlusal contacts can be caused by
 - Poor occlusal recording
 - Poor articulation

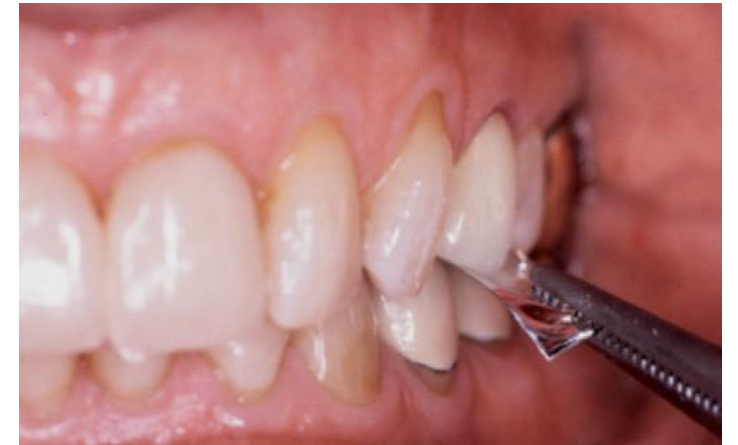

ASSESSMENT OF THE SEATED CROWN

Occlusion

Shim stock assessment

- The shim stock will determine if an occlusal contact is present
- Assess the occlusion on all teeth with and without the prosthesis
- Assess the occlusion on the crown



8 μ m thick



Analysis of Active Oral Tactile Sensitivity in Individuals with Complete Natural Dentition

Tiago HS Anastacio¹, Nathalia B de Moraes², Eduardo J de Moraes³, Valquiria Quinelato⁴, Jose A Calasans-Maia⁵, Cintia CP Martins⁶, Telma Aguiar⁷, Aldir N Machado⁸, Priscila L Casado⁹

ABSTRACT

Aim: To evaluate the active tactile sensitivity in individuals with complete natural dentition, determining the smallest thickness detected by the participants, and clarifying if there is a difference between the thicknesses analyzed.

Materials and methods: Active tactile sensitivity was evaluated in 40 research participants. Inclusion criteria included participants with complete natural dentition, without active or history of periodontal disease, absence of temporomandibular disorders, bruxism, and restorations in the evaluated area. Exclusion criteria included age below 18 years. The active tactile perception threshold was evaluated by using carbon sheets of different thicknesses (0, 12, 24, 40, 80, 100, and 200 μm), which were inserted in the participants' premolars, bilaterally. The carbon sheet was inserted so as not to come into contact with the oral soft tissues. Subsequently, the participant occluded and was asked about the perception of the intraocclusal object 20 times in each occlusal contact. The collected data were tabulated considering the amount of positive and negative responses for each carbon thickness. Values of $p < 0.05$ were considered significant.

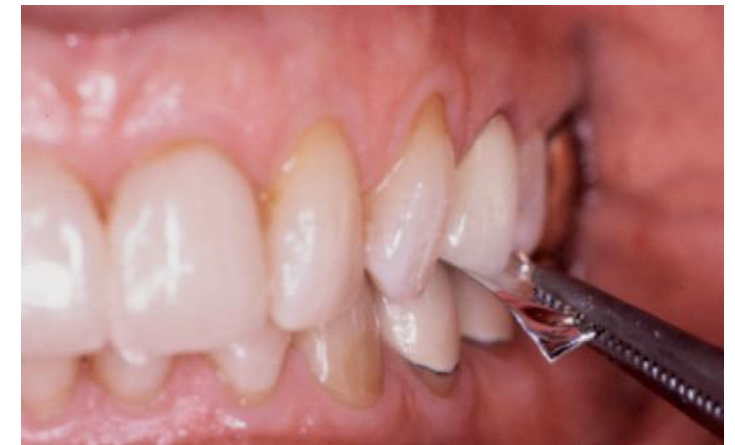Results: The results showed that there was linearity in perception, on both sides, besides, the natural dentition was able to perceive difference in thickness from 12 μm .

Conclusion: We conclude that the 12 μm thickness is noticeable in occlusion and can be differentiated from other thicknesses in natural dentition and that there is no difference between the tactile sensitivity of the right and left sides.

Clinical significance: A better understanding of active oral tactile sensitivity will contribute to numerous clinical applications in dentistry, including occlusal adjustment in dental rehabilitation, dental implants prosthesis design, and survival of prosthetic rehabilitation.

Keywords: Active tactile sensitivity, Dental occlusion, Mechanoreceptors, Oral proprioception, Periodontal ligaments, Permanent dentition.

The Journal of Contemporary Dental Practice (2021): 10.5005/jp-journals-10024-3069



8 μm thick

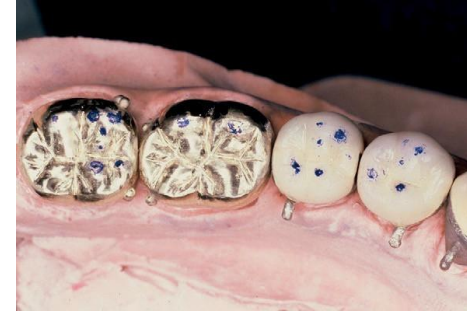


ASSESSMENT OF THE SEATED CROWN

Occlusion

Articulating paper assessment

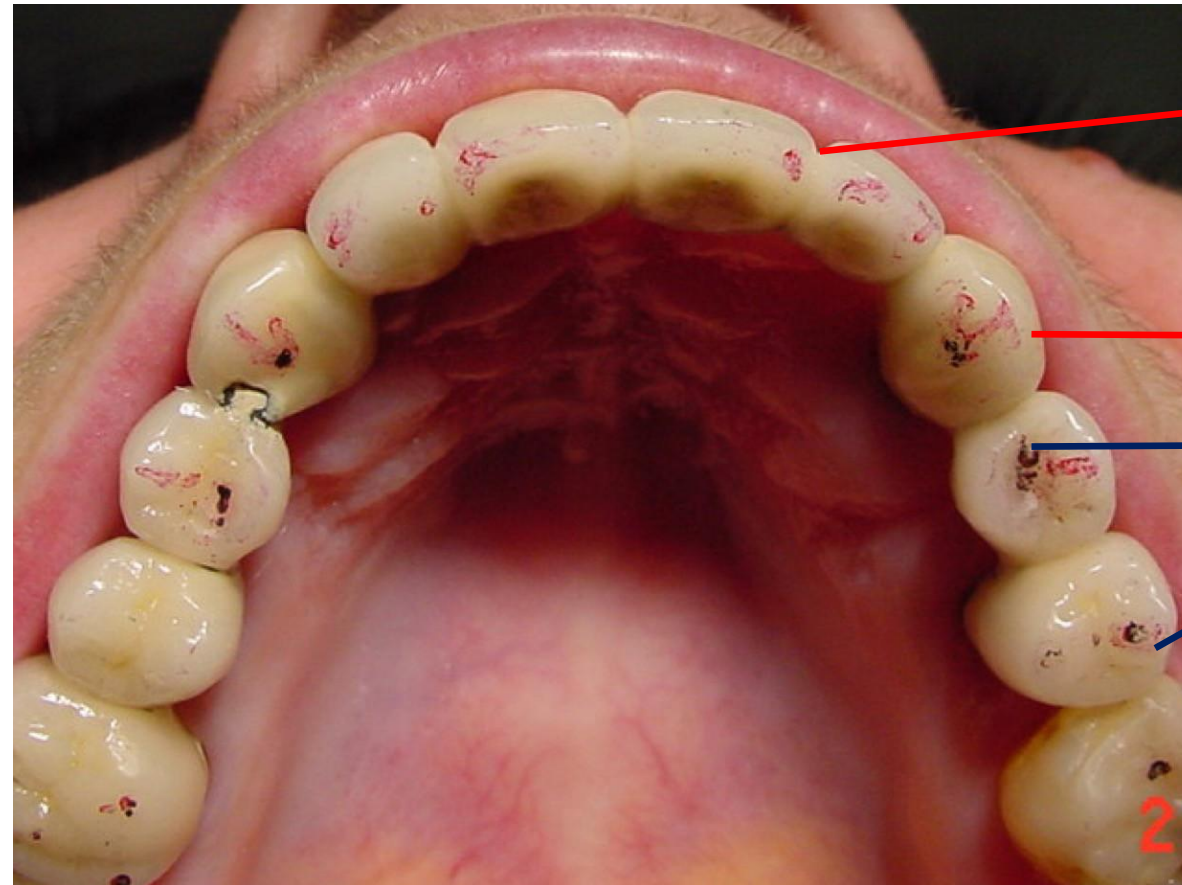
- Mark heavy contacts or interferences in centric and eccentric
- Articulating paper will locate the contact area
- Use different colors for different movements



ASSESSMENT OF THE SEATED CROWN

Occlusion

- ▶ Dark articulating paper (blues) for CR or maximal intercuspation position
- ▶ Lighter articulating paper (red) for eccentric position



Protrusion

Lateroprotrusion

MIC



ASSESSMENT OF THE SEATED CROWN

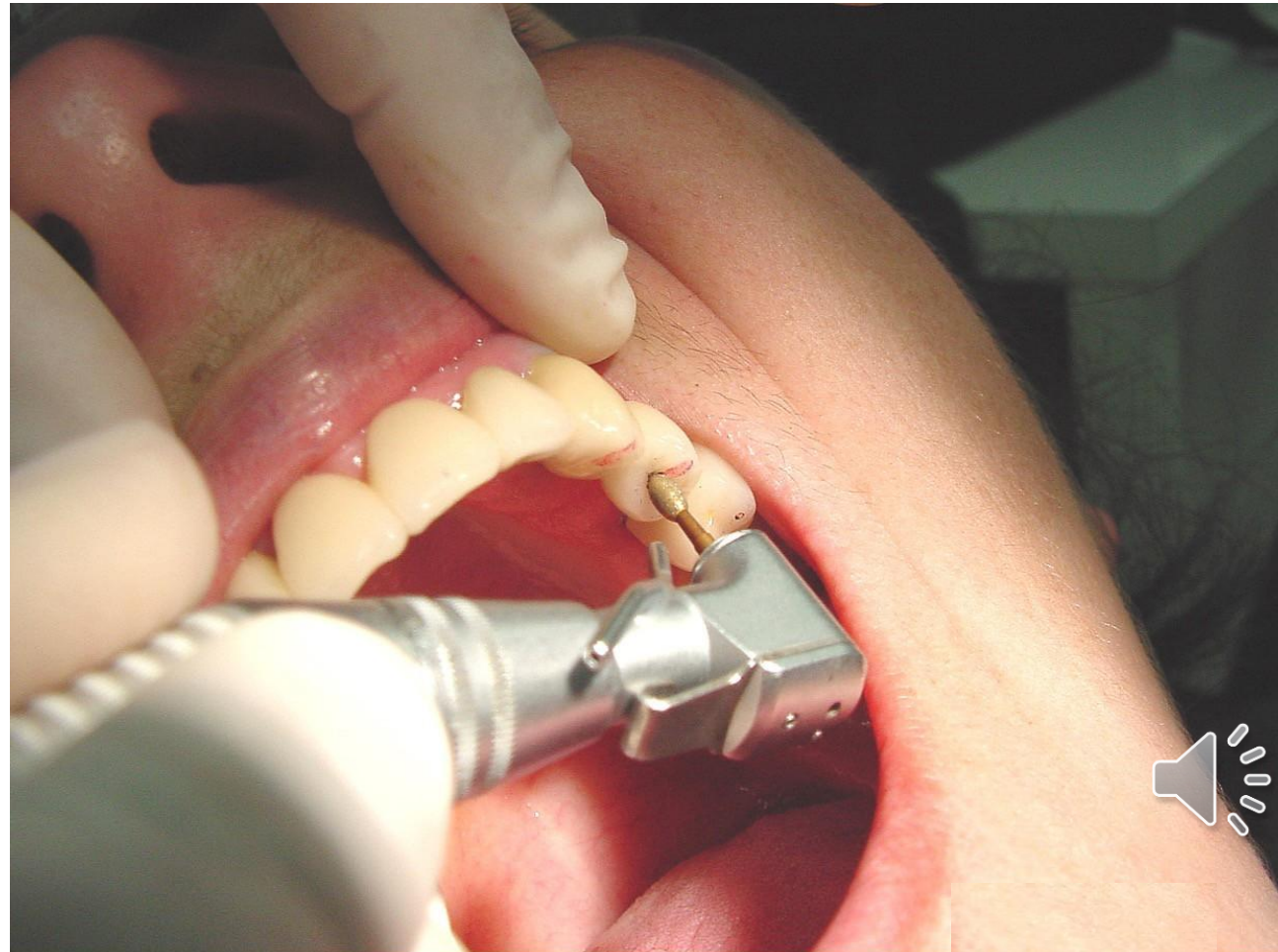Occlusion

Premature contact (centric)

- Adjust grooves or cusp inclines
- Never the tip of cusp

Interferences (eccentric)

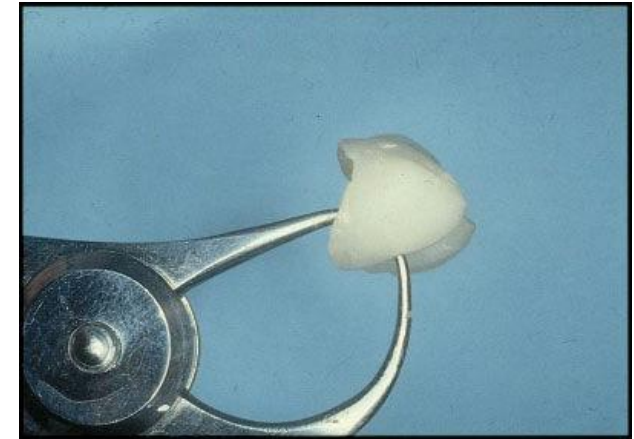
- Adjust cusp inclines
- Tip of cusps if necessary



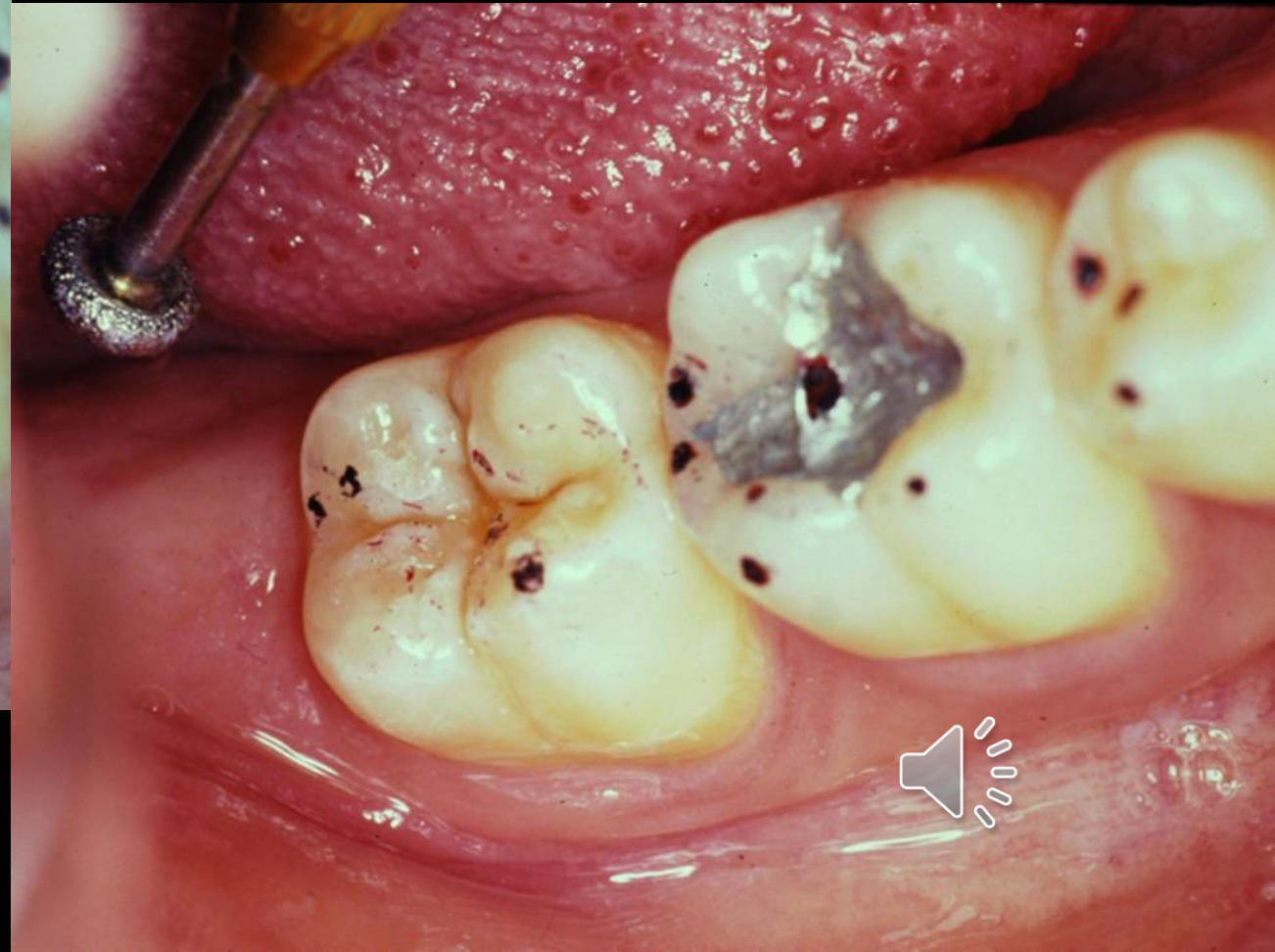
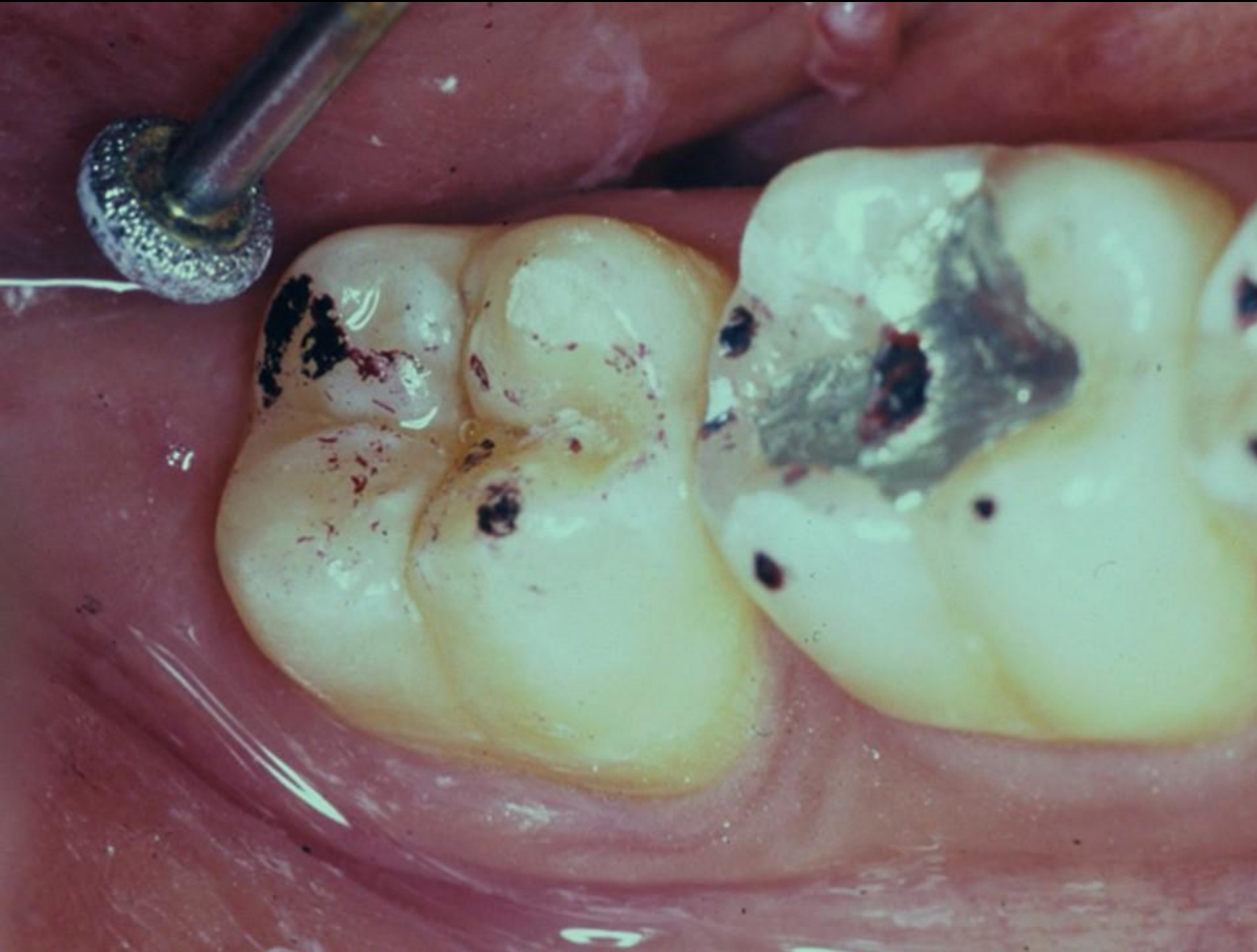ASSESSMENT OF THE SEATED CROWN

Occlusion

The prosthesis thickness should be measured
Thickness Gauge (Svensen Gauge)
In some cases the opposing tooth can be
adjusted



TRY-IN PROCEDURE




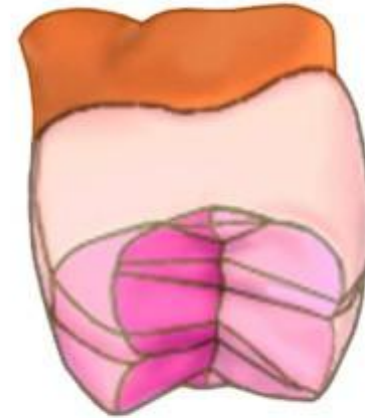
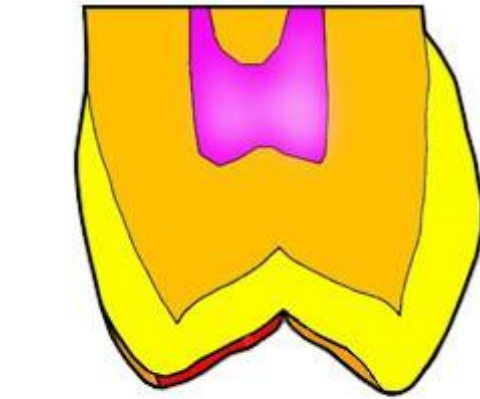
TRY-IN PROCEDURE



THE UNIVERSITY OF
**WESTERN
AUSTRALIA**



Oral Health Centre
of Western Australia



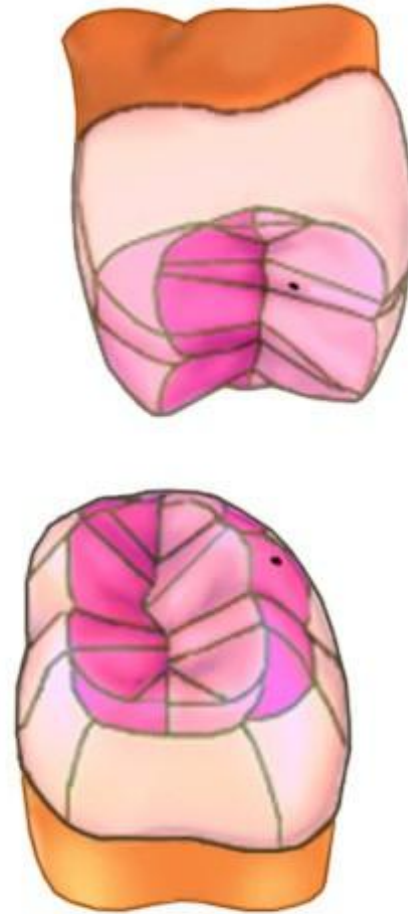
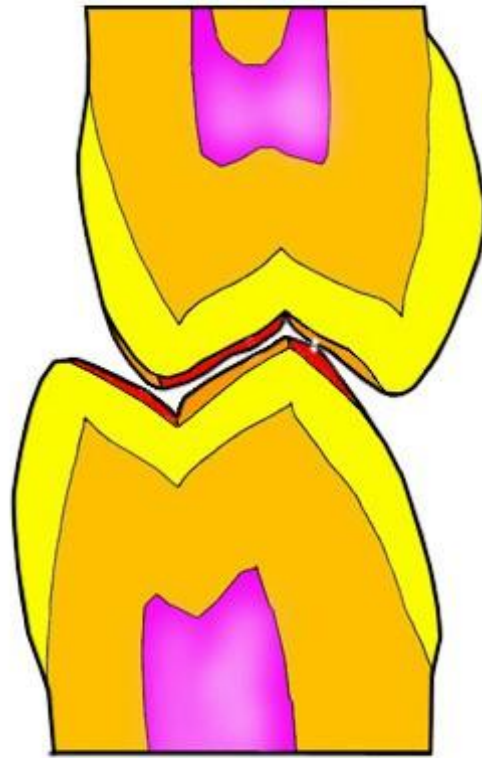
TRY-IN PROCEDURE



THE UNIVERSITY OF
**WESTERN
AUSTRALIA**



Oral Health Centre
of Western Australia



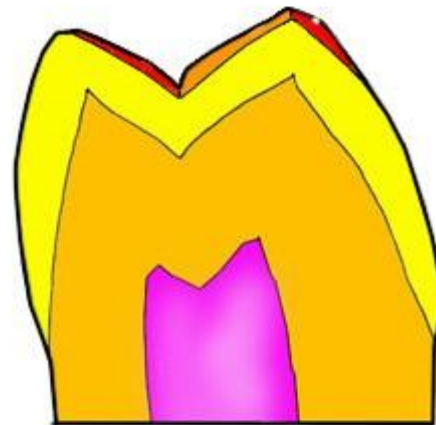
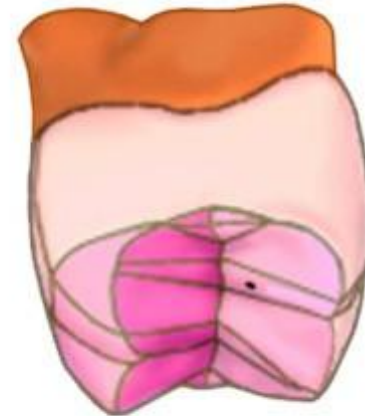
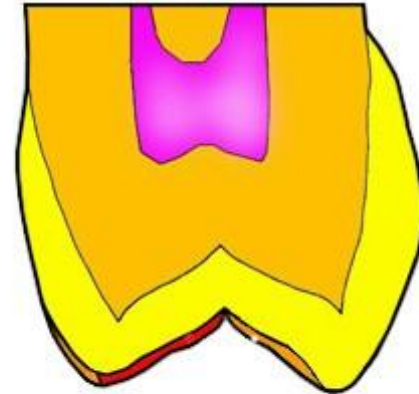
TRY-IN PROCEDURE



THE UNIVERSITY OF
**WESTERN
AUSTRALIA**



Oral Health Centre
of Western Australia



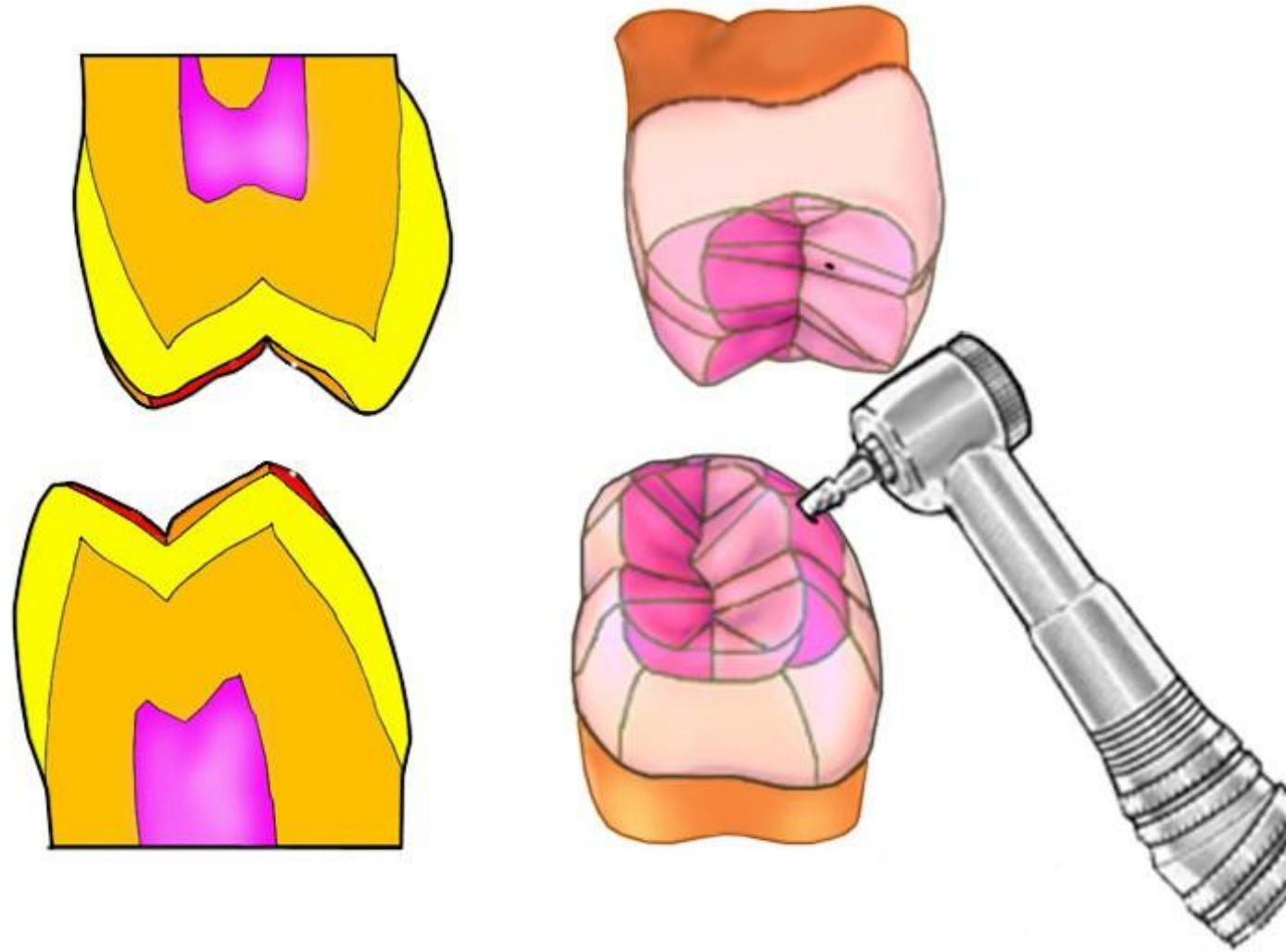
TRY-IN PROCEDURE



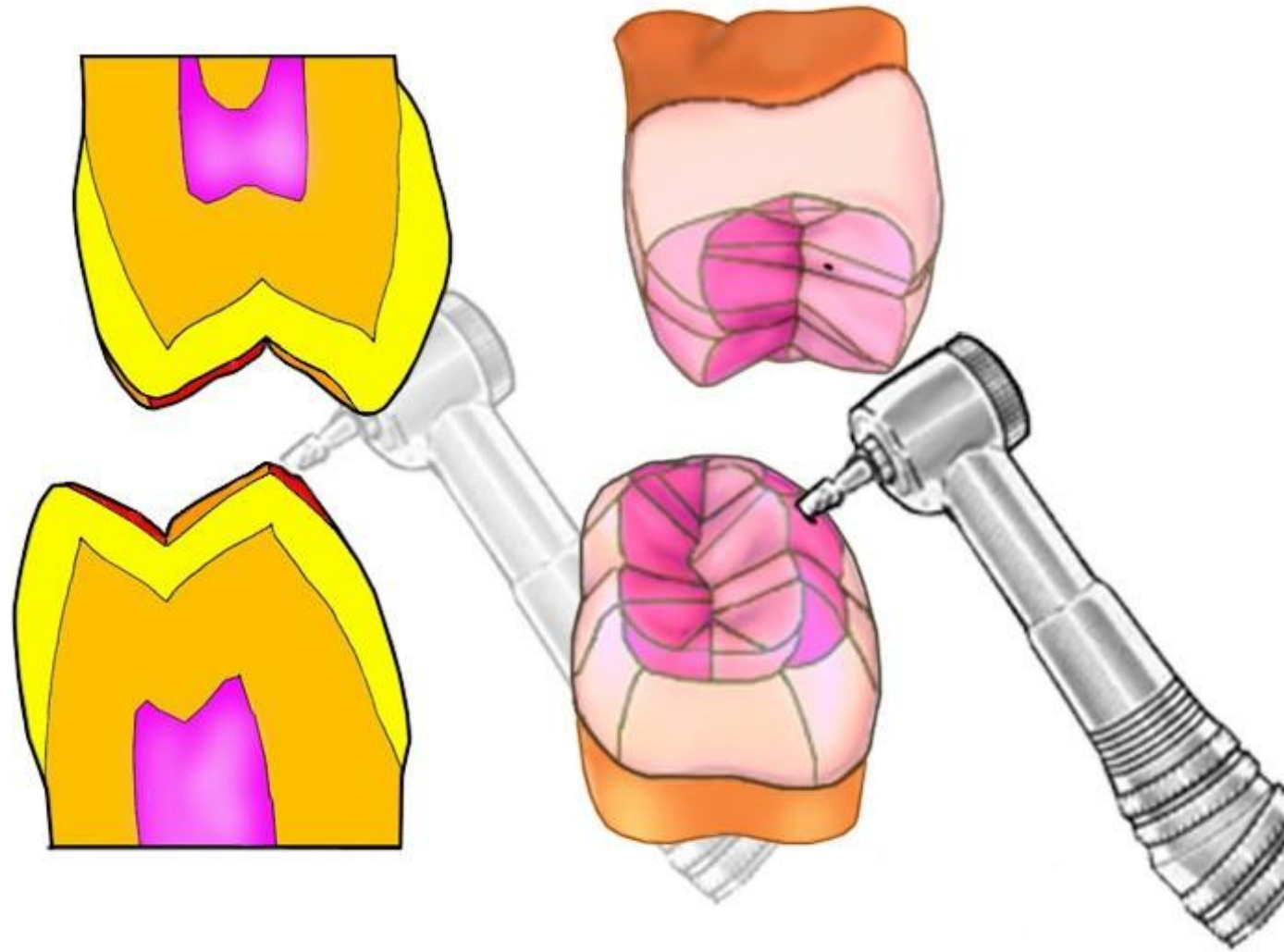
THE UNIVERSITY OF
**WESTERN
AUSTRALIA**



Oral Health Centre
of Western Australia



TRY-IN PROCEDURE



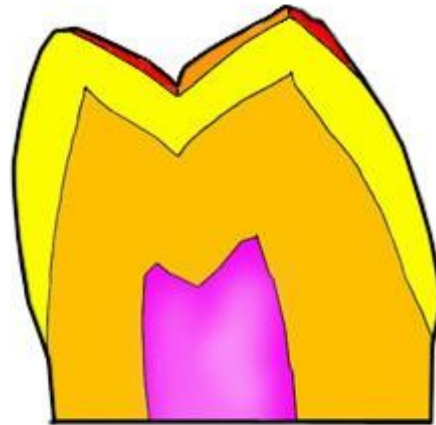
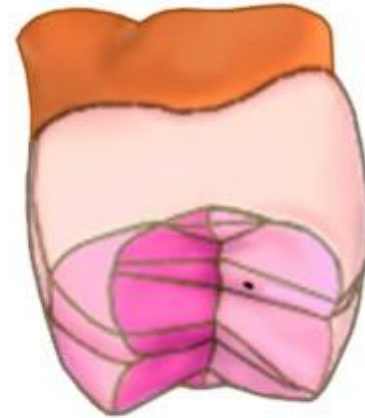
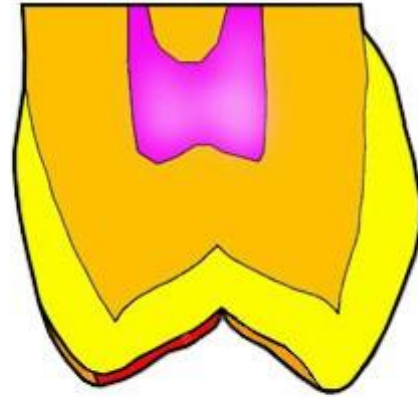
TRY-IN PROCEDURE



THE UNIVERSITY OF
**WESTERN
AUSTRALIA**



Oral Health Centre
of Western Australia



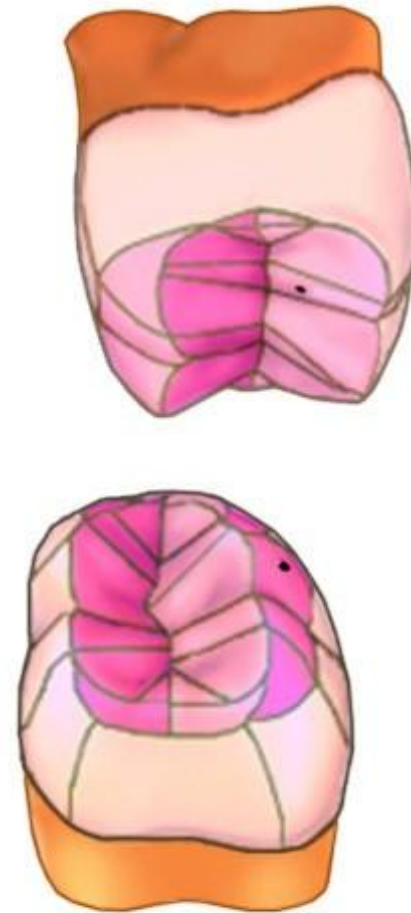
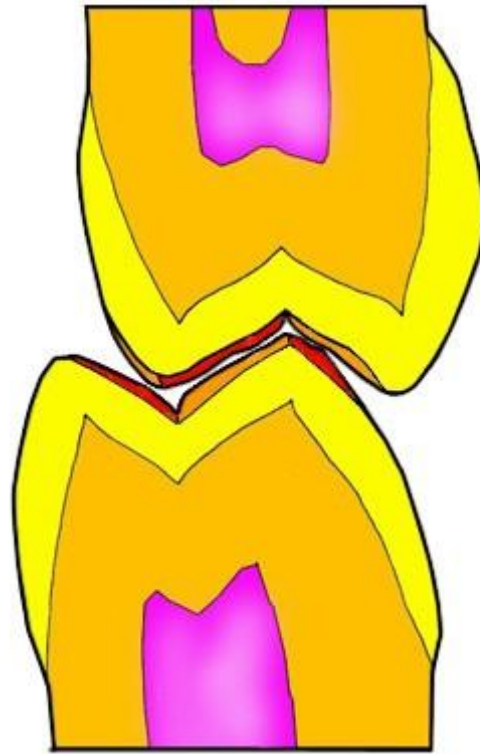
TRY-IN PROCEDURE



THE UNIVERSITY OF
**WESTERN
AUSTRALIA**



Oral Health Centre
of Western Australia



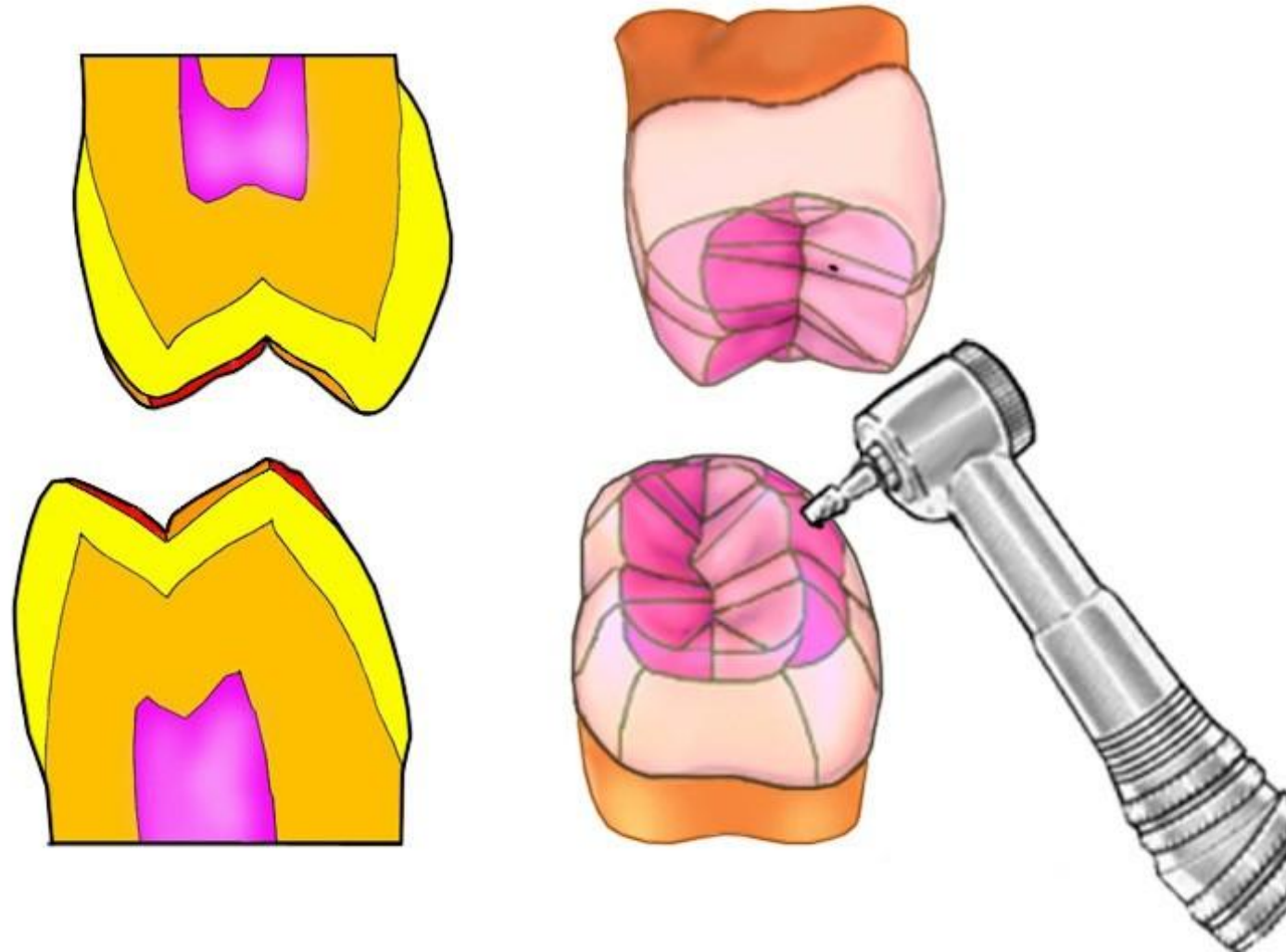
TRY-IN PROCEDURE



THE UNIVERSITY OF
**WESTERN
AUSTRALIA**



Oral Health Centre
of Western Australia



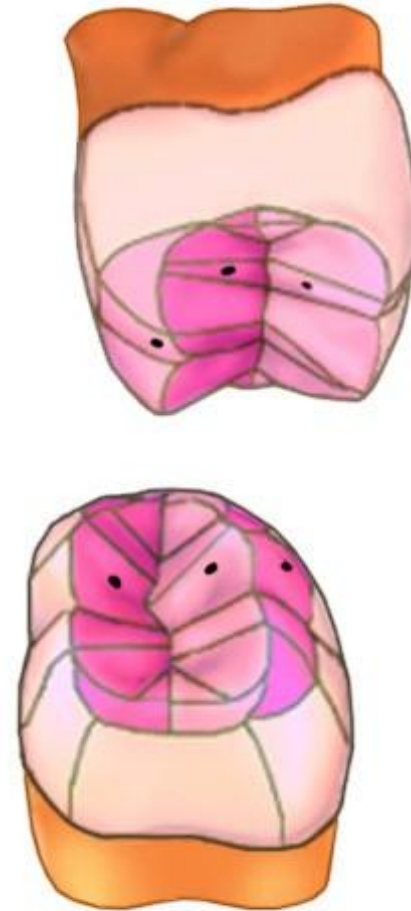
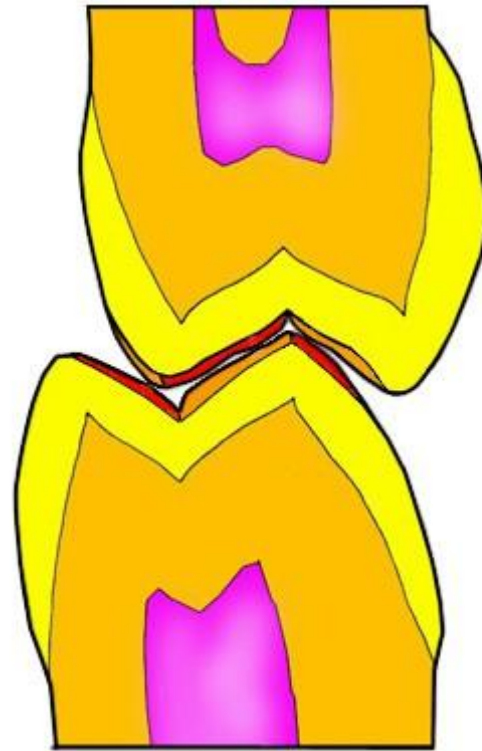
TRY-IN PROCEDURE



THE UNIVERSITY OF
**WESTERN
AUSTRALIA**



Oral Health Centre
of Western Australia



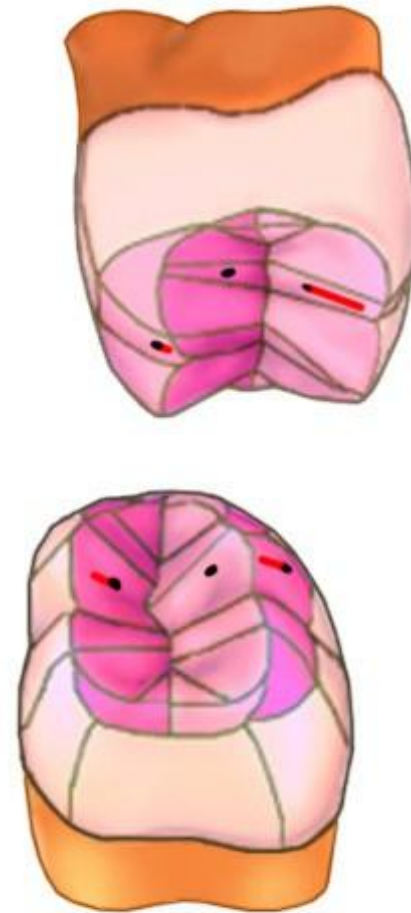
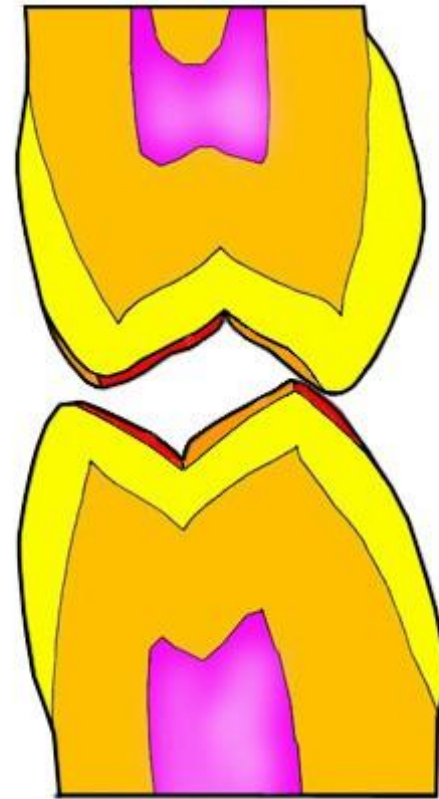
TRY-IN PROCEDURE



THE UNIVERSITY OF
**WESTERN
AUSTRALIA**



Oral Health Centre
of Western Australia



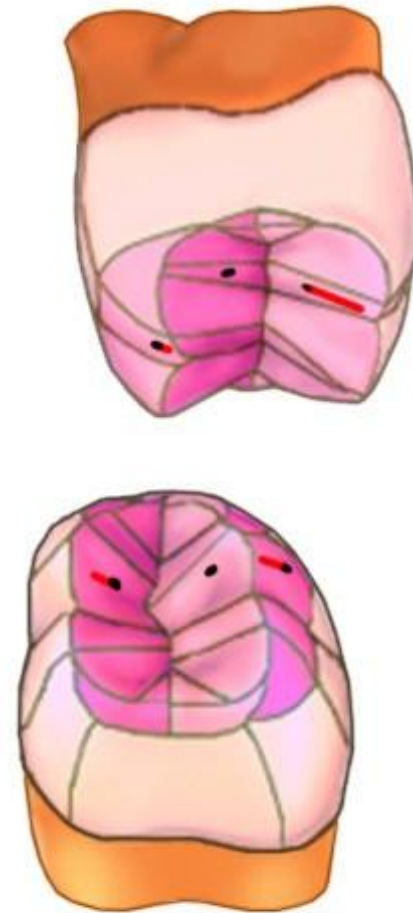
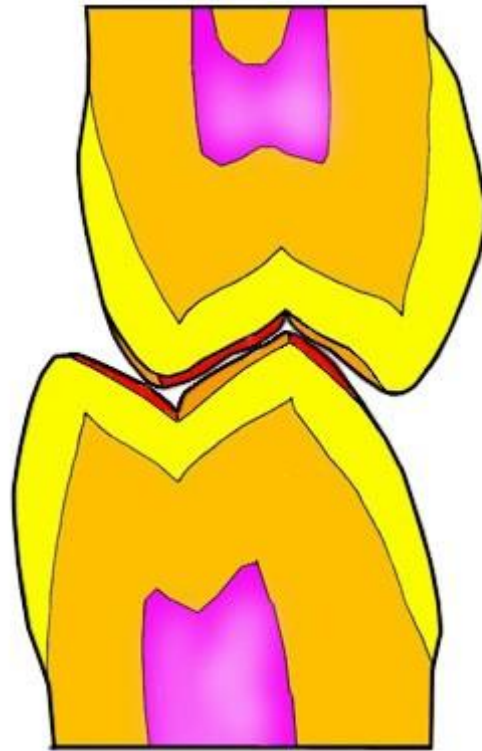
TRY-IN PROCEDURE



THE UNIVERSITY OF
**WESTERN
AUSTRALIA**



Oral Health Centre
of Western Australia



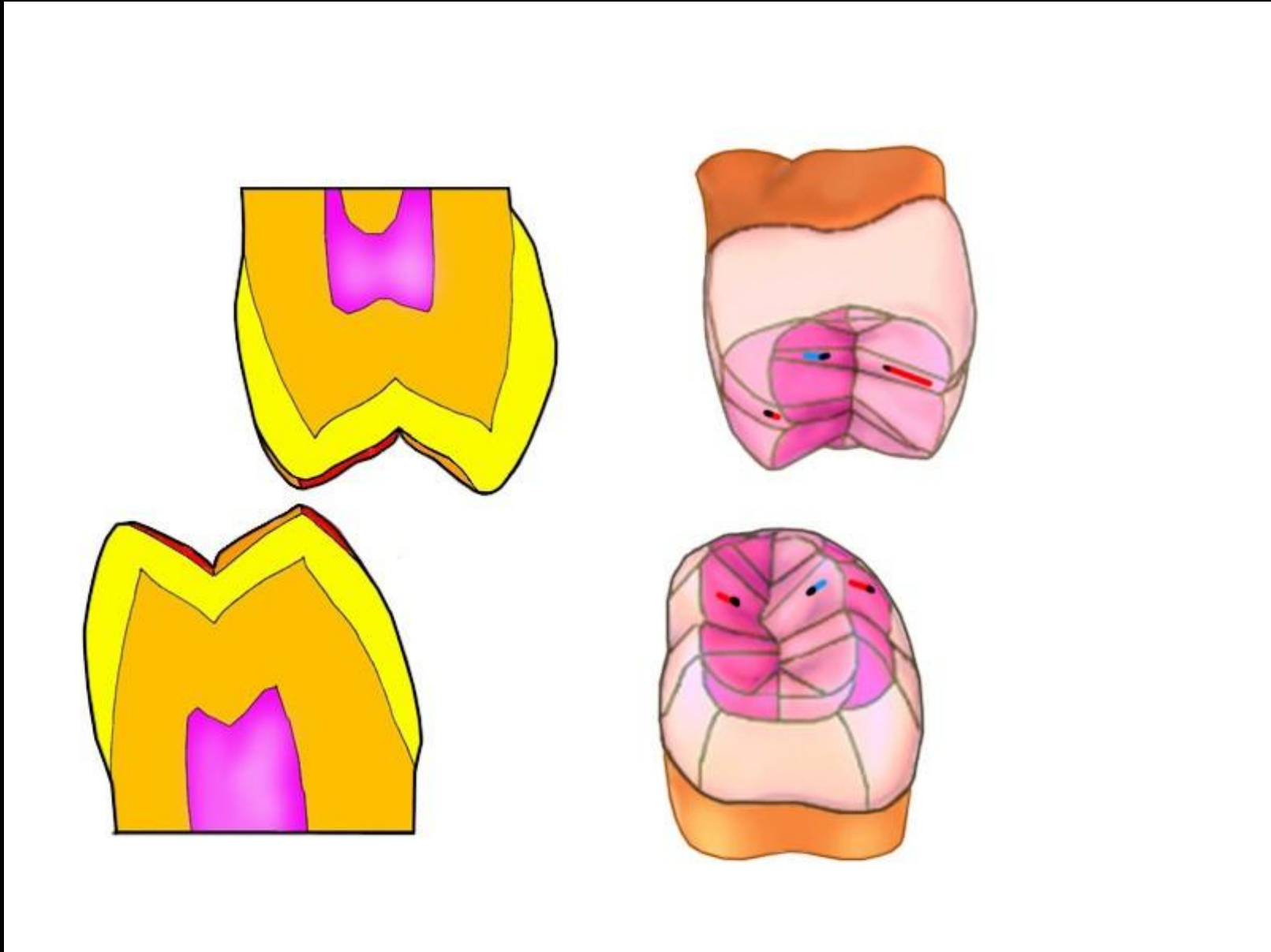
TRY-IN PROCEDURE



THE UNIVERSITY OF
**WESTERN
AUSTRALIA**



Oral Health Centre
of Western Australia



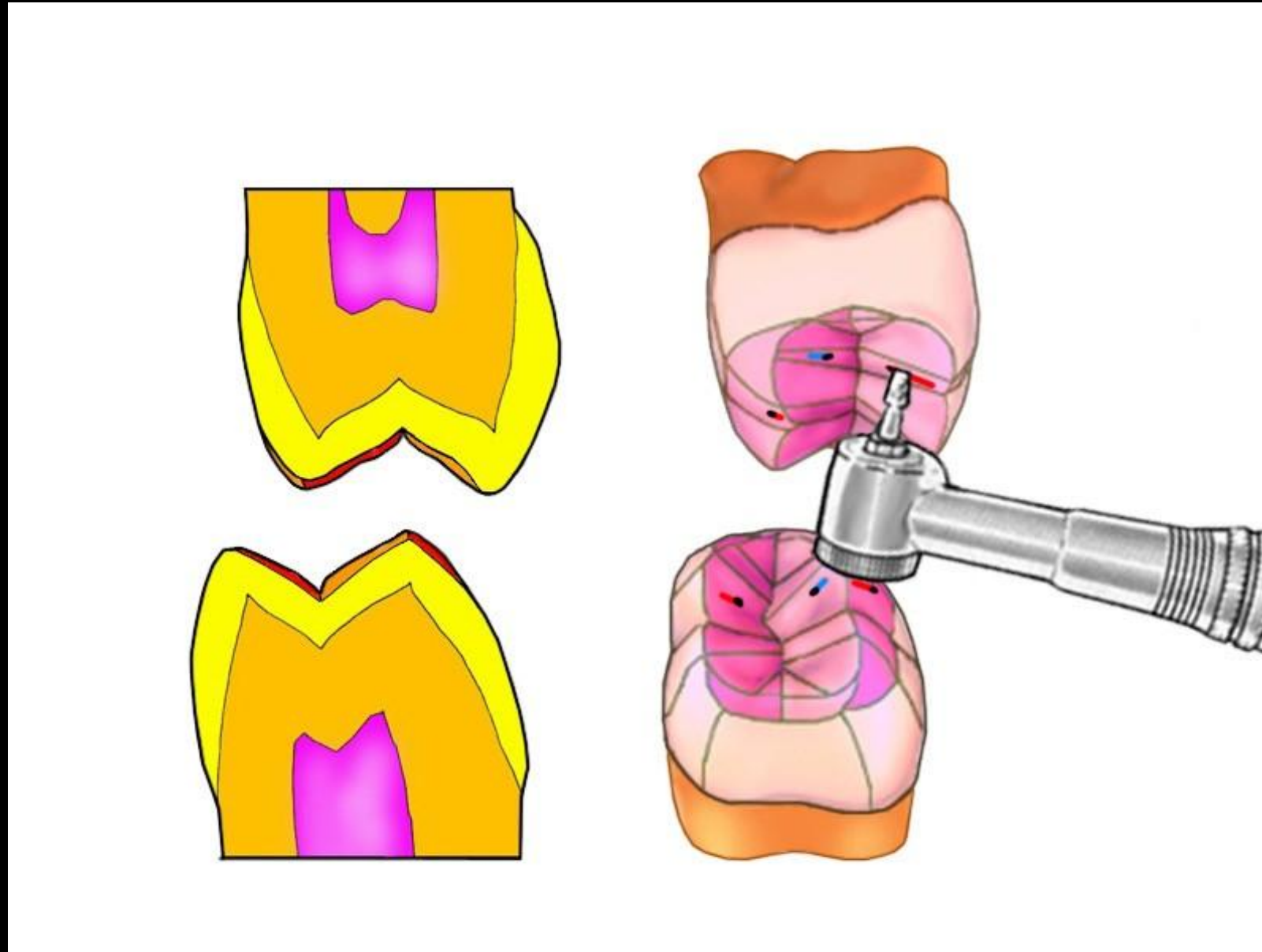
TRY-IN PROCEDURE



THE UNIVERSITY OF
**WESTERN
AUSTRALIA**



Oral Health Centre
of Western Australia



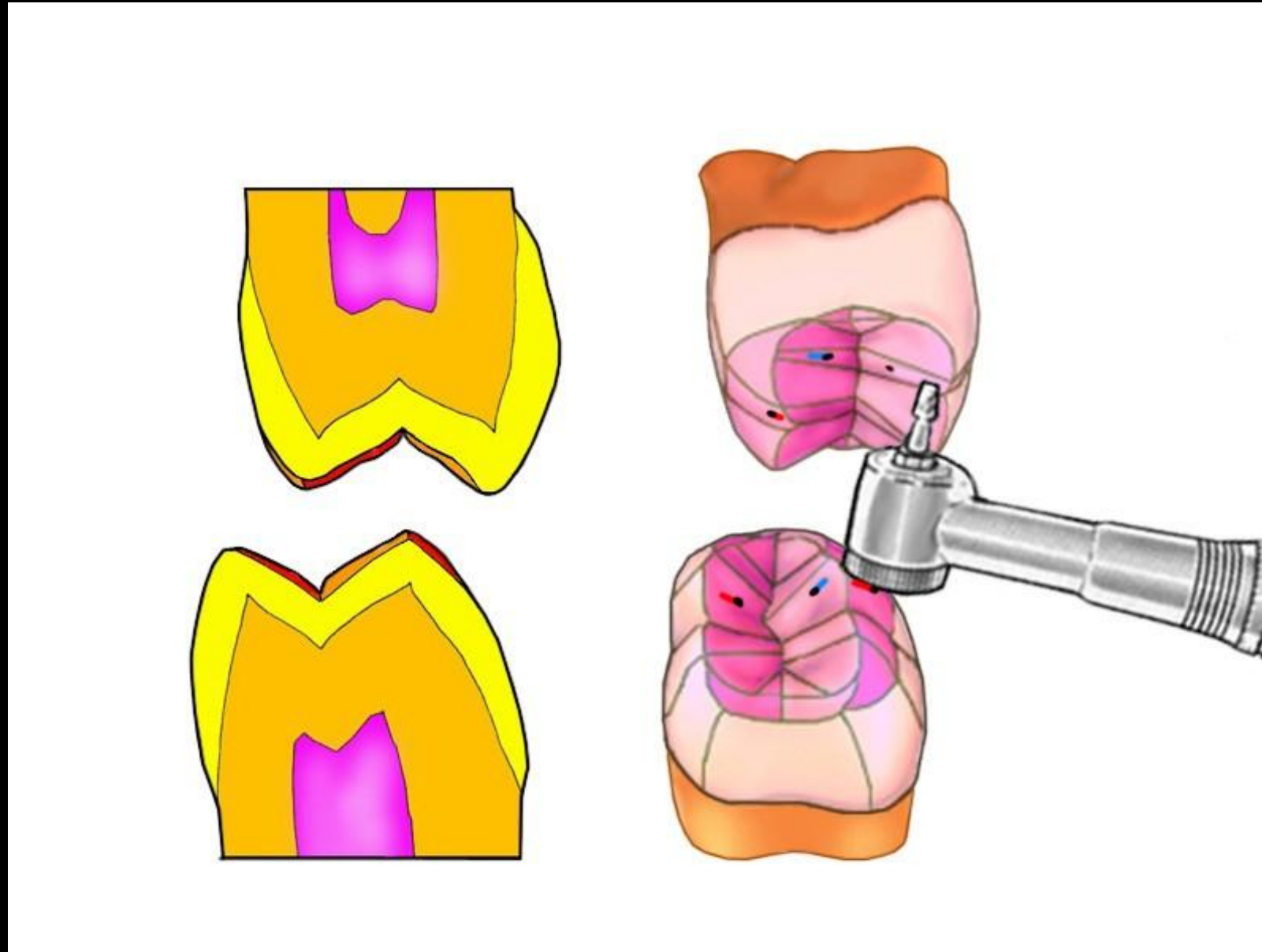
TRY-IN PROCEDURE



THE UNIVERSITY OF
**WESTERN
AUSTRALIA**



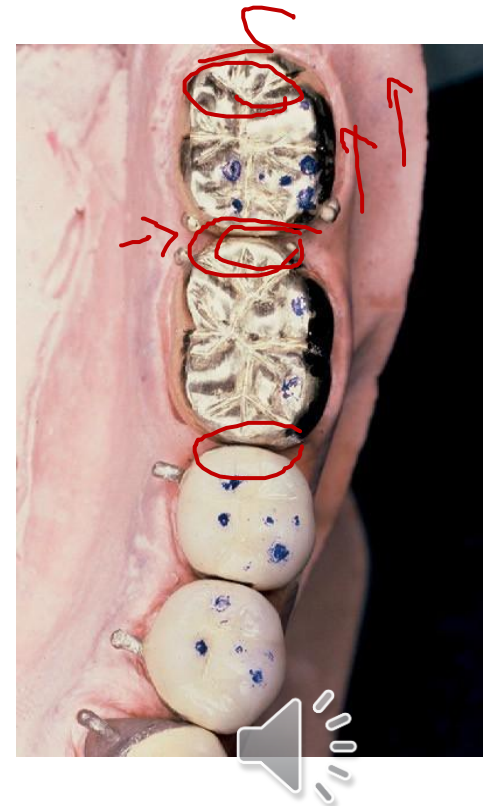
Oral Health Centre
of Western Australia



ASSESSMENT OF THE SEATED CROWN

Occlusion

- ▶ Completed adjustment
 - Well distributed occlusal contacts
 - Posterior teeth: the prosthesis and the remaining dentition should have the same occlusal contact and hold shim stock
 - Anterior teeth: the prosthesis should lightly hold shim stock if other anterior teeth do

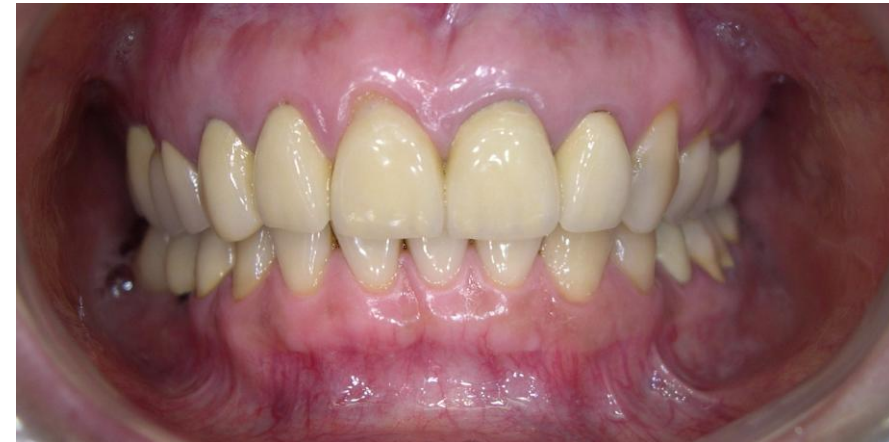

ASSESSMENT OF THE SEATED CROWN

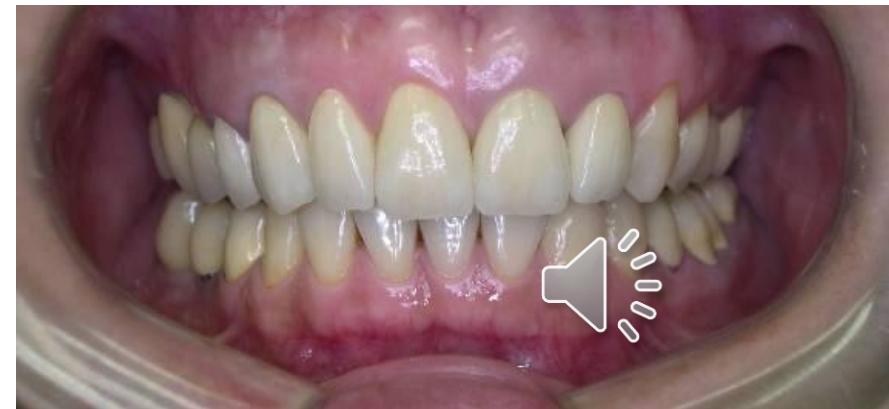Aesthetics

- Patient approval should be obtained prior to cementation
- Shade and morphology
 - Lighter shade: can be stained and glazed
 - Darker shade: should be cut back and followed by new ceramic application
- Modify the morphology with diamond burs and soflex discs
 - Send back for glazing
- Consider temporary cementation

Before



After



ASSESSMENT OF THE SEATED CROWN

Finishing and Polishing

- **Metal:** rubber polishing wheels and points
- **Ceramic:** Rough ceramic will wear the opposing teeth
 - Composite finishing rubber burs
 - Rubber cup and diamond polishing paste
 - Or send to laboratory for reglazing



ASSESSMENT OF THE SEATED CROWN

Finishing and Polishing

- **Metal:** rubber polishing wheels and points
- **Ceramic:** Rough ceramic will wear the opposing teeth
 - Composite finishing rubber burs
 - Rubber cup and diamond polishing paste
 - Or send to laboratory for reglazing



Systematic approach

1. Evaluation of the restoration on the die

- a) Die and opposing model
- b) Internal surface of restoration
- c) Restoration on the model (die)

2. Seating the crown on the prepared tooth

- a) Proximal contact
- b) Internal fit
- c) Marginal fit

3. Assessment of the seated crown

- a) Stability
- b) Contour
- c) Occlusion
- d) Aesthetics



Questions?

Send me an email if you have questions!