

Case Presentation

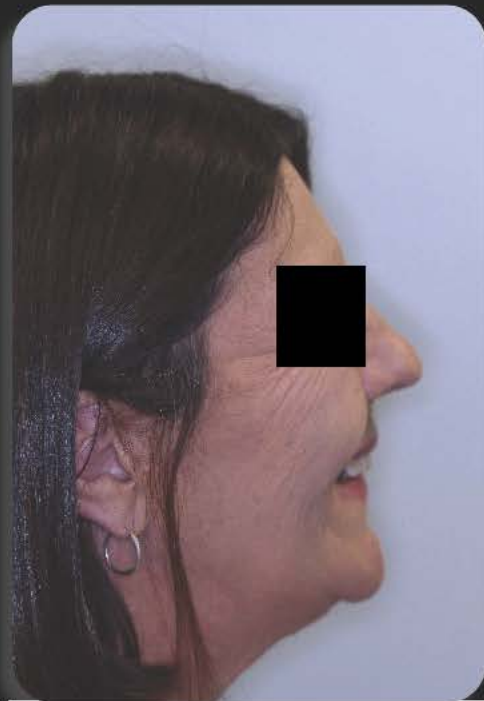
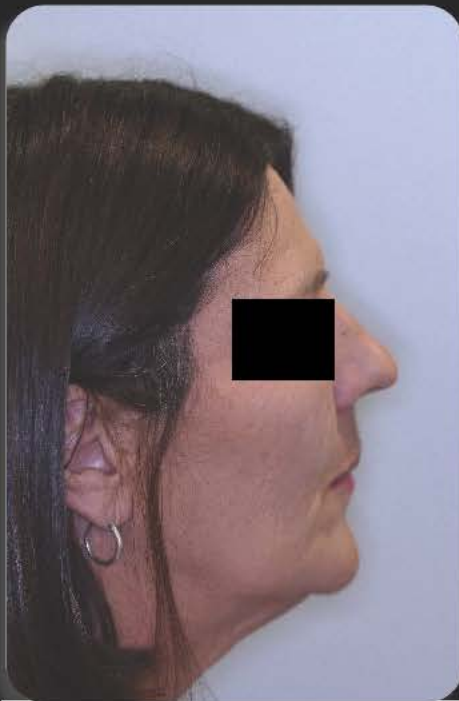
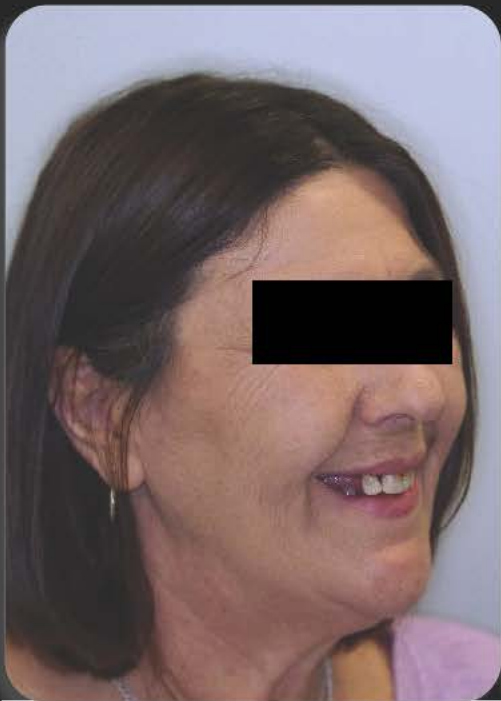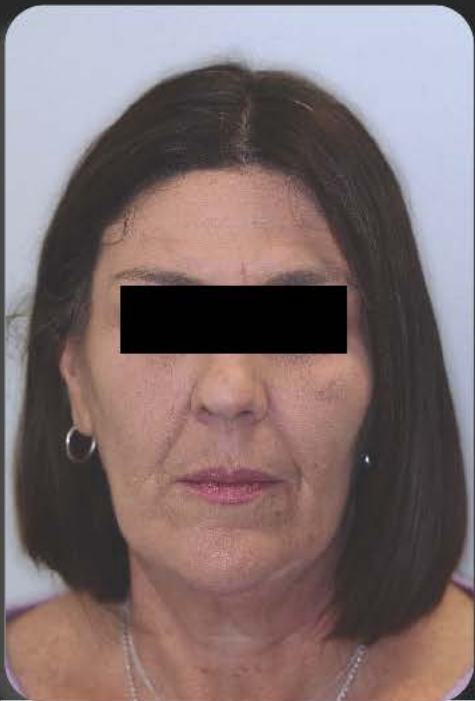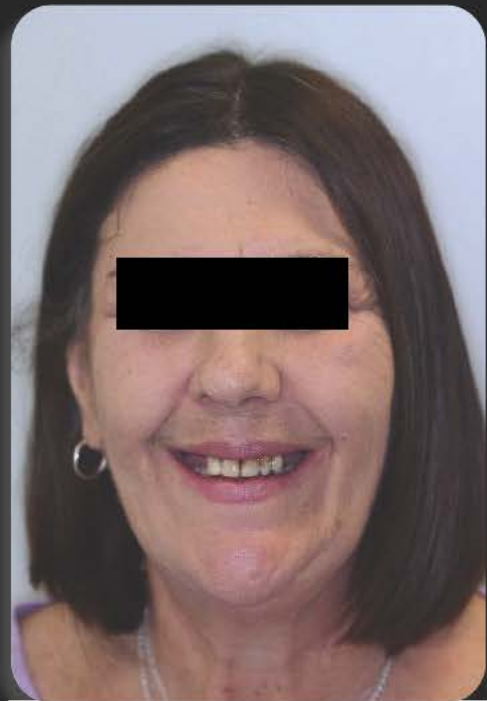Final Year Student

Doctor of Dental Medicine (DMD)

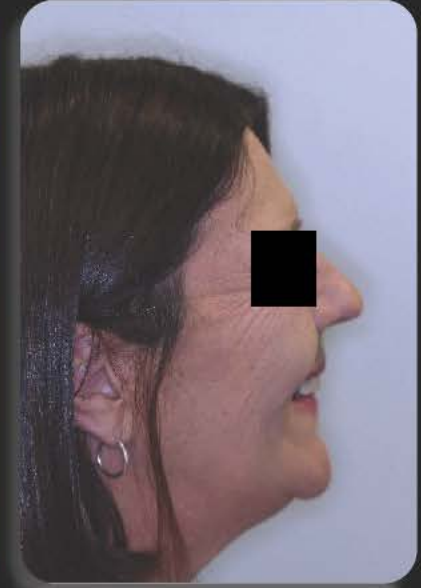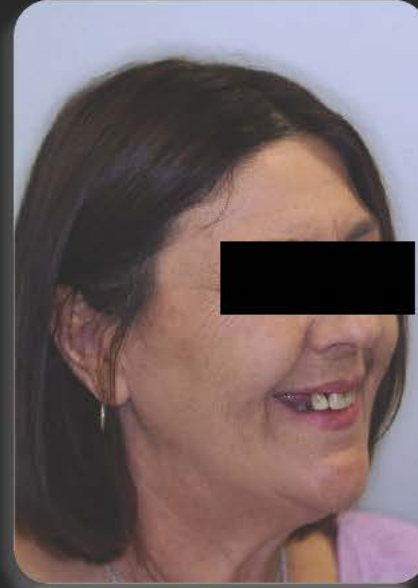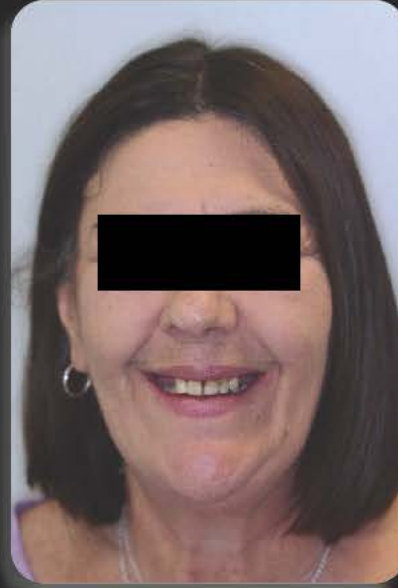University of Western Australia

51 yrs, F



1.1 Presenting complaint

- “I hate the appearance of my lower teeth, I want them all pulled out”
- “Three of my teeth have snapped off”
- “My upper denture keeps falling out”



1.2 History of presenting complaint

- Colleagues commented negatively on appearance of lower teeth
- Upper denture needs to be “glued in” with PolyDent Denture Adhesive
- Deteriorating dentition for many years

1.3 Medical history

- **Bipolar disorder type 2**
 - Clozapine 350mg tablet orally 1x/day
 - Ziprasidone 80mg tablet orally 1x/day, as required
- **Hashimoto's thyroiditis**
 - Levothyroxine 150µg tablet 2x/day
- **Bursitis**
 - Tramadol 200mg tablet orally 1x/day
- **Hypercholesterolaemia**
 - Fenofibrate 145mg tablet orally 1x/day
- **Insomnia**
 - Zopiclone 2x7.5mg tablet orally 1x/day
- **Smoker – 4 pack years**
 - 4 cigarettes/day for the past 20yrs
 - Recently 2 cigarettes/day
 - Trying to quit

1.4 Dental history

- Repeated temporary restorations
- Loss / fracture of multiple teeth due to caries and periodontal disease
- CrCo P/- made 4 years ago in OHCWA

1.5 Oral hygiene

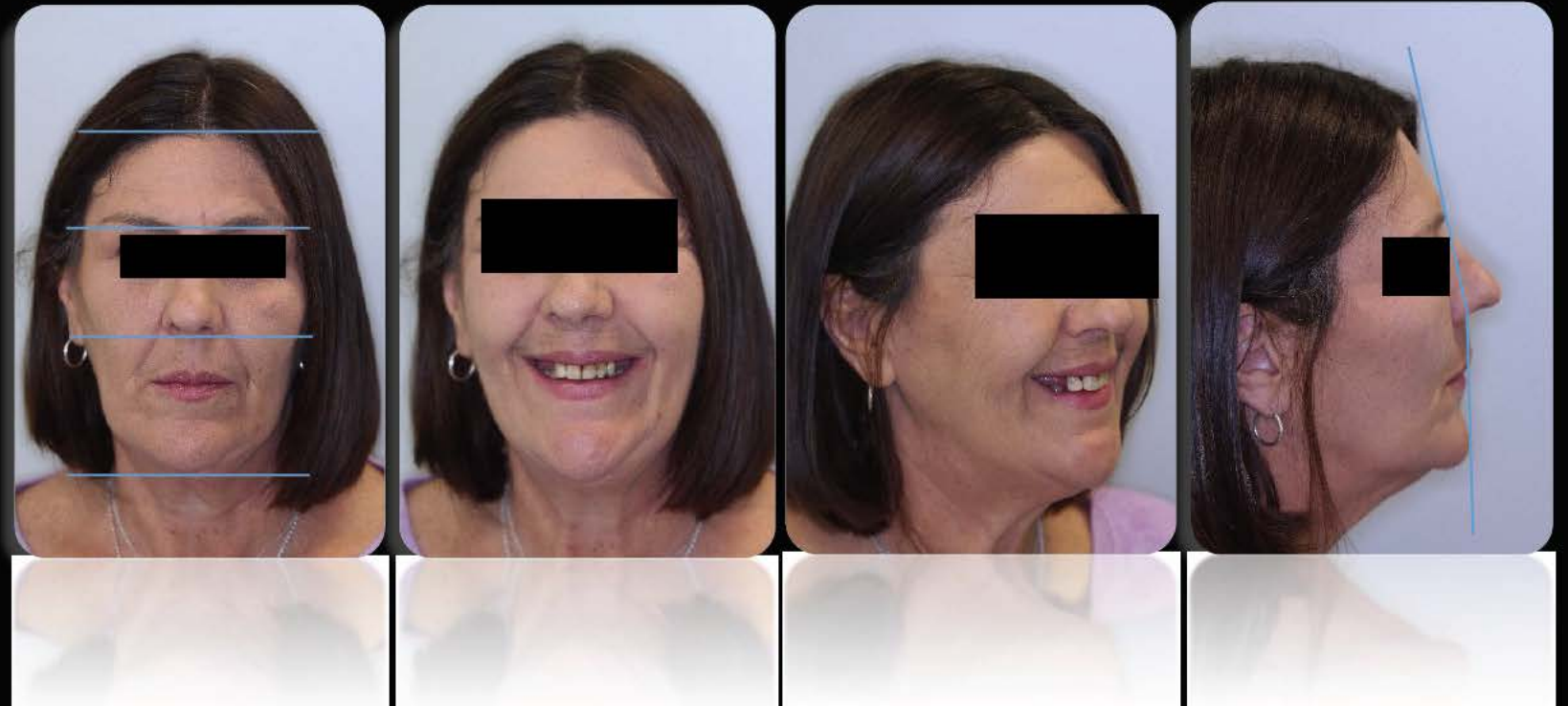- Brushing 2x/day
- Electric toothbrush
- Charcoal toothpaste (no fluoride)

1.6 Social history

- Works at a bakery
- Lives at home alone
- Close to mother, daughter and grandchildren
- Smokes 2 cigarettes/day – trying to quit
- Drinks wine 1-2 glasses/month

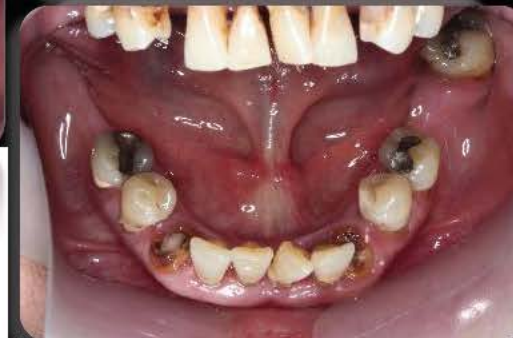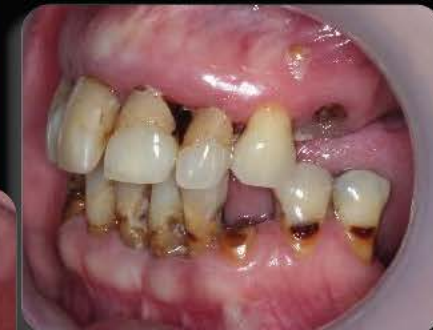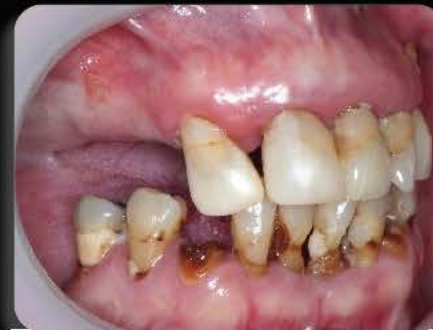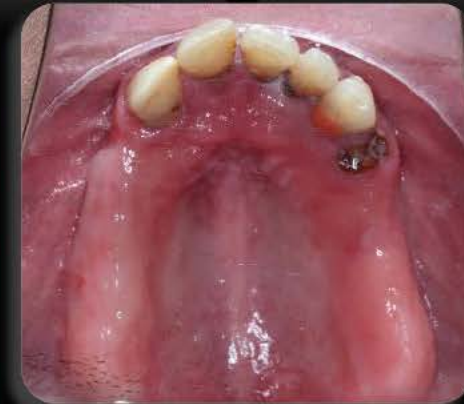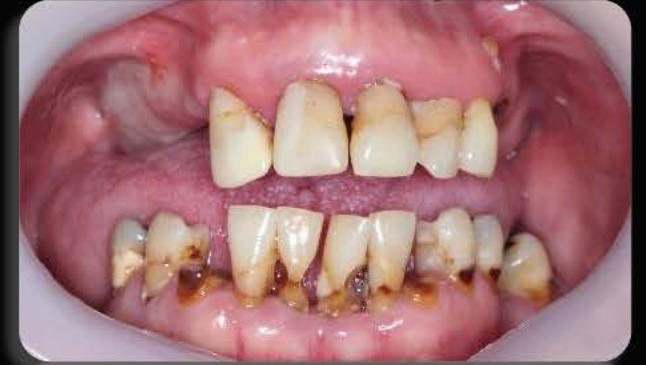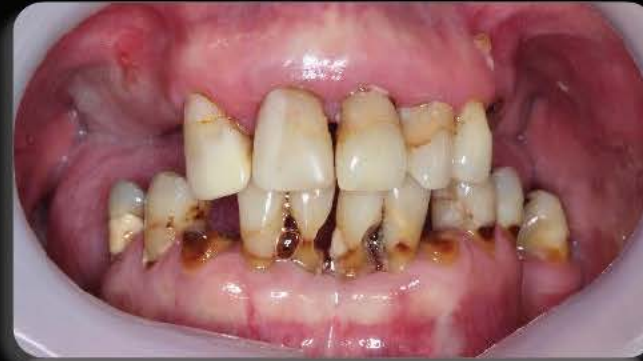1.7 Extra-oral examination

- Convex facial profile (CI II tendency)
- Elongated lower third of face
- Smile aesthetics
 - Wide buccal corridors
 - 95% incisal display
 - 0% gingival display



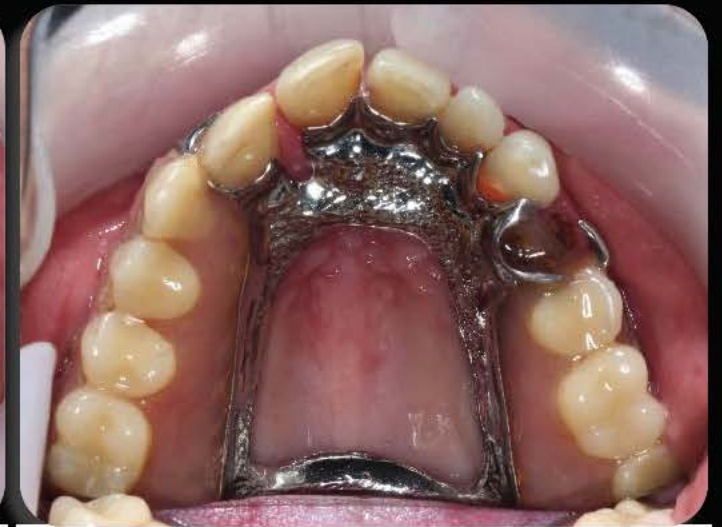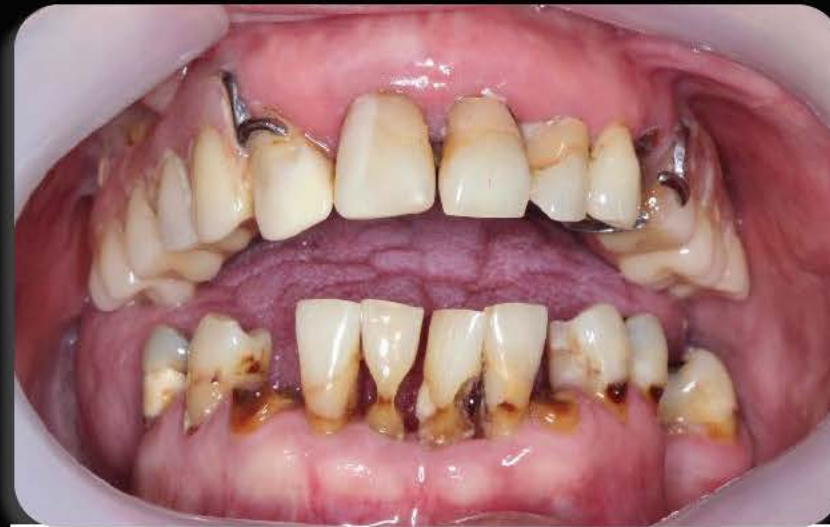1.8,1.9 Intra-oral examination

- **Mx hard palate**
 - Diffuse erythematous & edematous appearance
- **Gingiva**
 - Edematous, erythematous, blunting of interdental papilla, very painful to probing, BoP+
- **Dry appearance of oral mucosa**
- **Occlusion**
 - Loss of posterior contacts



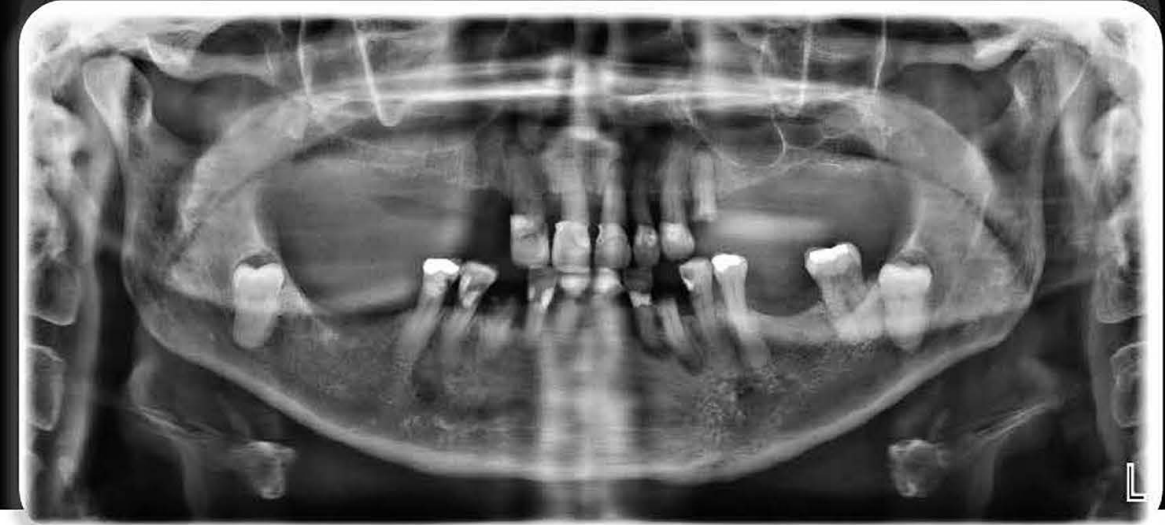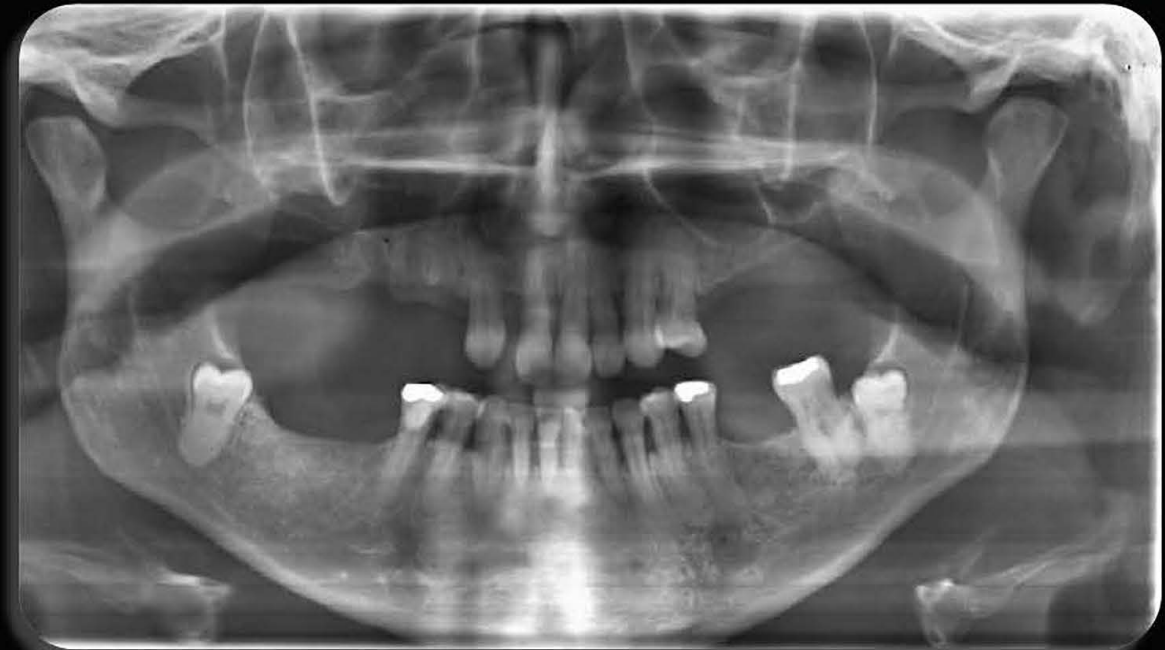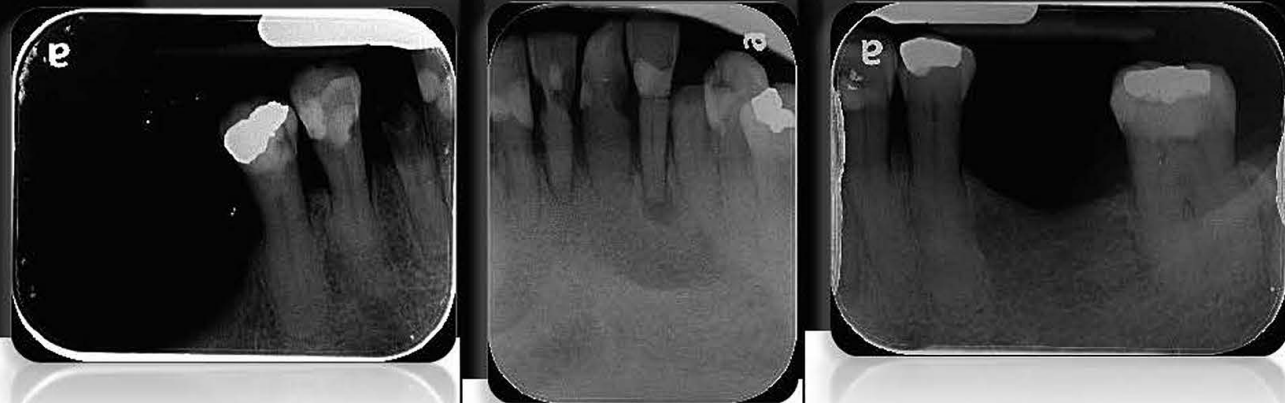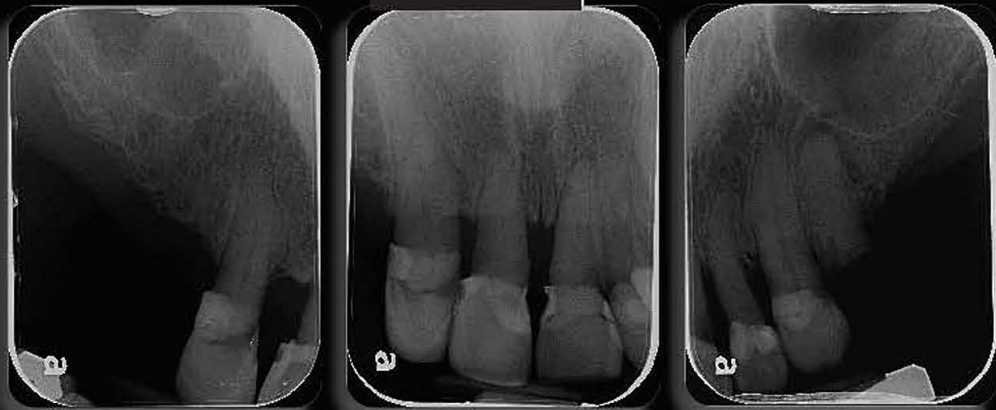
1.10 Dental prosthesis – CrCo P/-

- Age – 4yrs
- Appearance – POOR
- Retention – POOR
- Stability – POOR
- Pt satisfaction – POOR



1.13 Radiographs

- 2x OPGs taken [redacted] 2016 and 2018
- 6xPAs taken [redacted] 2018

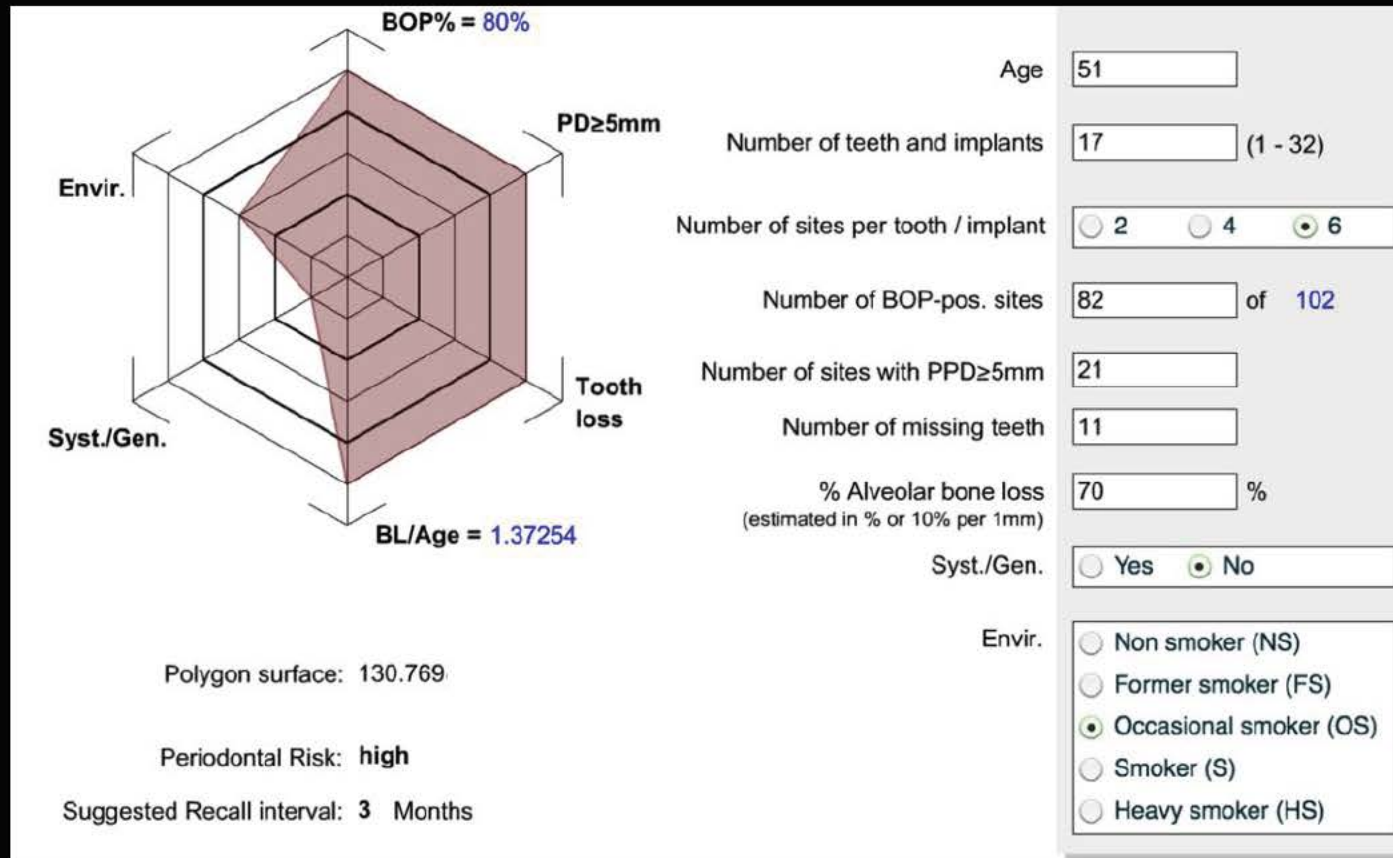


1.14 Caries risk assessment (Evans et al, 2008)

- **Diet assessment**
 - **High & frequent exposure to sugar & acid**
- **Plaque score**
 - **High – 54%**
- **Saliva assessment**
 - **Resting & stimulated adequate quantity & buffering**
 - **Resting compromised viscosity & pH**
 - **Stimulated compromised pH**
- **Clinical/radiographic examination**
 - **Frank cavitation affecting multiple teeth**

HIGH RISK

1.15 Periodontal risk assessment (Lang & Tonetti, 2003)



HIGH RISK

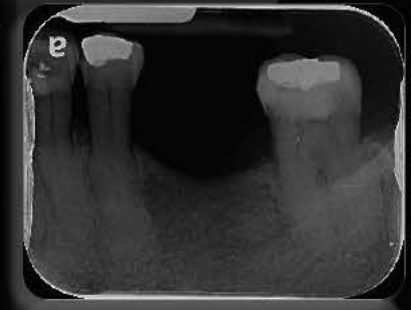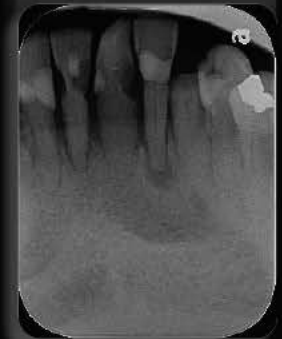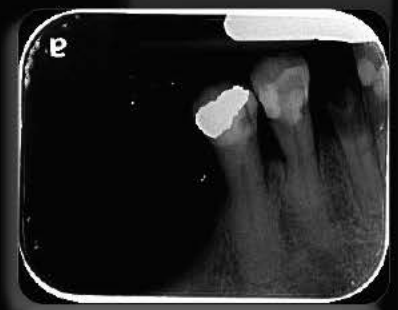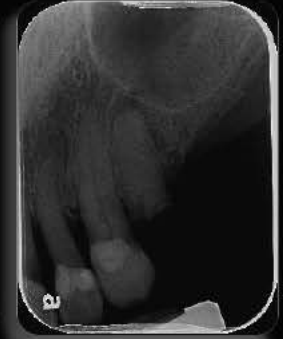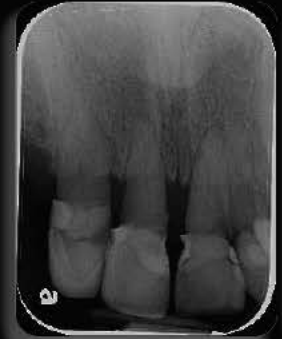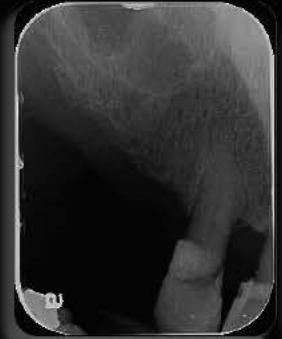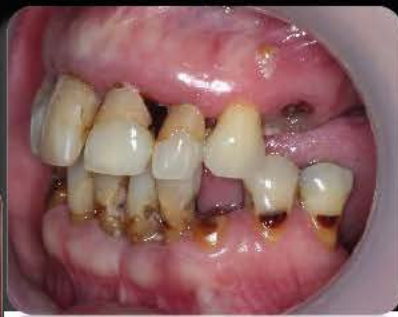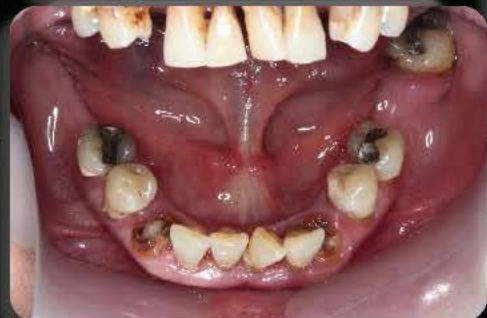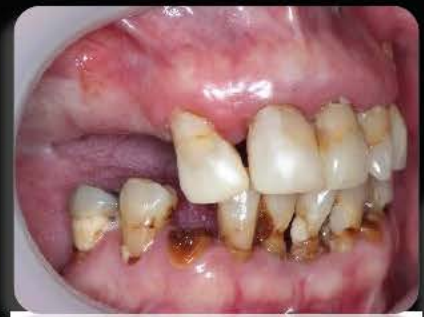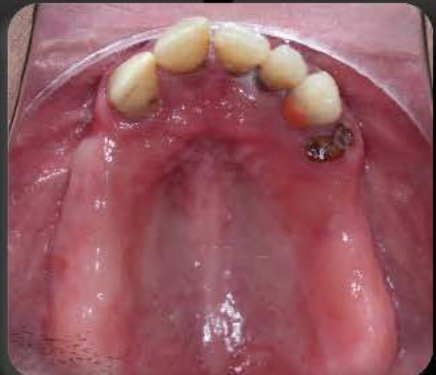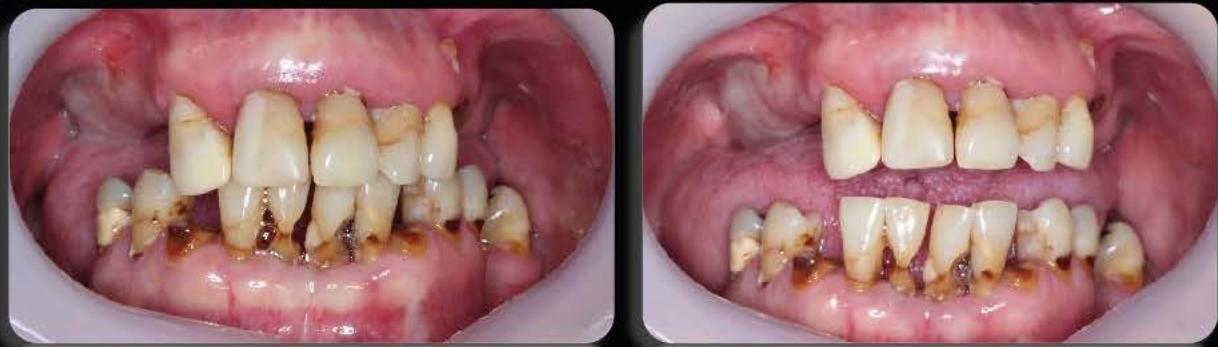1.17 Problem list

- **Poor smile aesthetics and unsatisfactory CrCo P/- (presenting complaint)**
 - Multiple root stumps, discolouration due to caries
 - Unsatisfactory CrCo P/- design and loss of retention due to fracture of abutment tooth 24
- **Host-related**
 - Bipolar disorder & hypothyroidism managed by medication
 - Dry mouth
 - Smoker
 - Frequent and high intake of sugary & acidic foods and drinks
 - Questionable OH compliance / dental attendance record
- **Pathology**
 - Carious root stumps 24, 33, 43
 - Frank cavitation due to caries 11, 13, 21, 22, 23, 31, 32, 34, 35, 41, 44, 45
 - Moderate to severe generalized chronic periodontitis modified by smoking (AAPD, 1999) / Periodontitis Stage 4 Grade C modified by smoking (Papapanou et al, 2017)
 - Pulpless and infected RCS and chronic apical periodontitis due to caries 24, 32, 33 (Abbott & Yu, 2004; Abbott, 2004)
 - Recurrent aphthous ulcerative disease
 - Denture stomatitis of the anterior hard palate
- **Morphology**
 - CI II tendency
 - Vertically impacted 38, 48
 - Hypercementosis 13, 23, 24, 34, 35, 44, 45
 - Missing teeth - Mx Kennedy CI I, Md Kennedy CI II Mod 1
 - Large, bulbous Mx anterior alveolar ridge
 - Loss of posterior support

1.18 Diagnoses

- **Poor smile aesthetics and unsatisfactory CrCo P/- (presenting complaint)**
- **Root stumps / “unrestorable” teeth**
- **Caries**
- **Periodontal disease**
- **Endodontically involved teeth**
- **Mx Kennedy CI I**
- **Md Kennedy CI II Mod 1**

1.19 Treatment options



1.19 Treatment options

- 1. Immediate acrylic F/P**
- 2. Conventional F/P**
- 3. Immediate or conventional F/F**
- 4. Mx and Md implant-supported fixed prostheses**
- 5. Temporization of remaining teeth \pm 24 tooth addition to CrCo P/-**
- 6. No treatment**

1.20 Management plan – Foundational phase

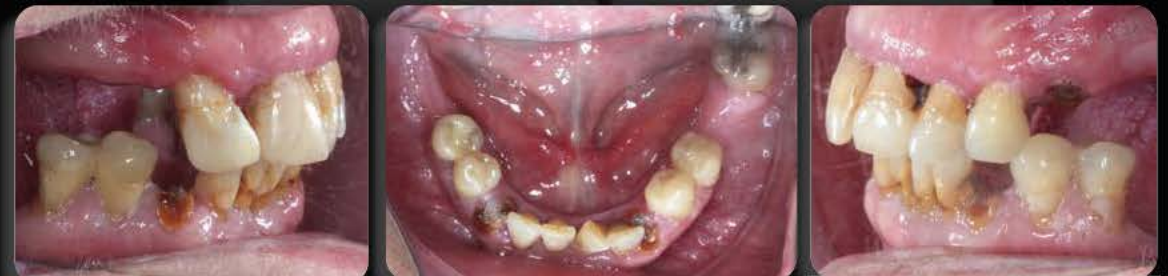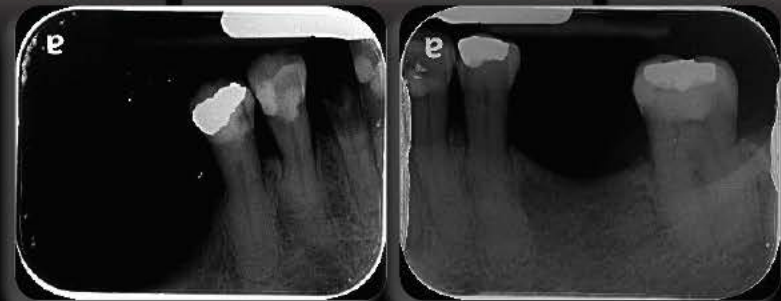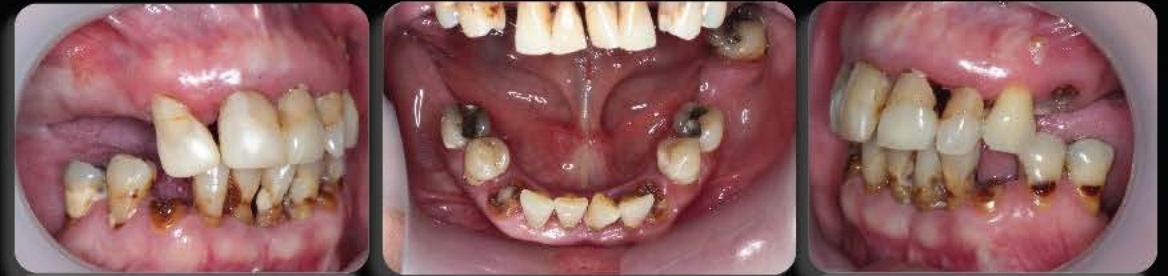- **Address the presenting complaint ([REDACTED])**
 - **Can understand the basis for pt's presenting complaint**
 - **Aesthetics is the main concern BUT there are many other issues going on**
 - **Huge burden of disease – caries, periodontitis, pulpless and infected teeth**
 - **Diseases processes are the underlying cause of aesthetic issues**
 - **Must treat the disease to improve aesthetics**
 - **Without treatment, diseases will continue to progress and aesthetics will worsen**

1.20 Management plan – Foundational phase

- **Discussing lifestyle factors / OH routine ([REDACTED])**
 - **Dry mouth**
 - **Smoking cessation counselling – “The 5As” (eTG, 2012)**
 - **Drink enough tap water – 1L/day**
 - **Reduce coffee intake**
 - **Diet**
 - **Reduce sugar intake**
 - **Reduce snacking**
 - **Oral hygiene and dental visits (Evans et al, 2008)**
 - **Brush 2x/day morning and night**
 - **Neutrafluor 5000 Plus toothpaste**
 - **Interdental brushes 1x/day at night**
 - **Attend all dental appointments**

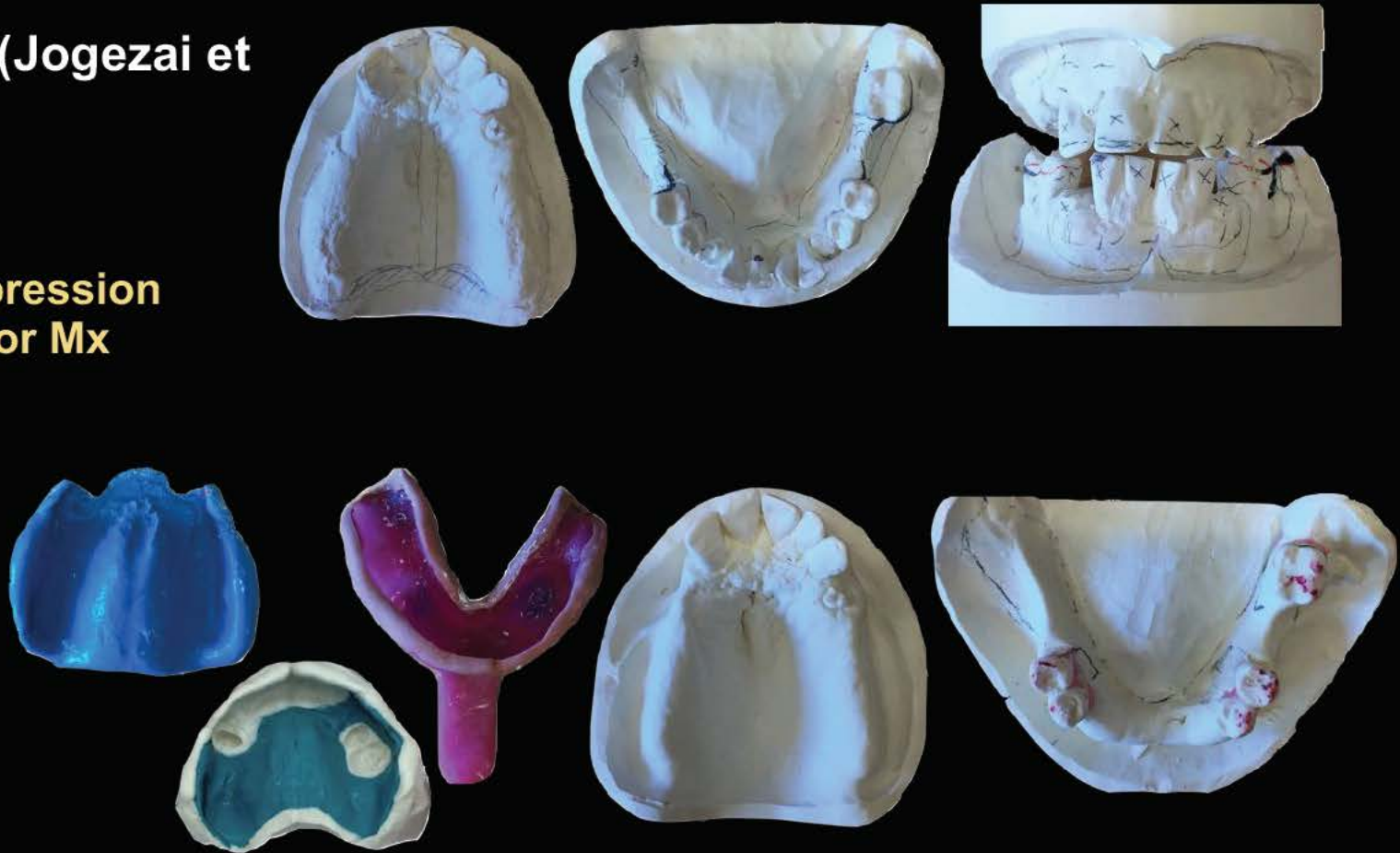
1.20 Management plan – Foundational phase

- **Selective SRD (2018)**
 - 37, 35, 34, 44, 45 SRD under LA
 - Prophy
 - Topical fluoride
- **Restorations (2018 - 2018)**
 - 34 MOLiBu Equia Forte + composite (Filtek Supreme) sandwich restoration
 - 35 OBU composite (Filtek Supreme) restoration
 - 44 DBuLi Equia Forte restoration
 - 45 MODLiBu Equia Forte + composite (Filtek Supreme) sandwich restoration



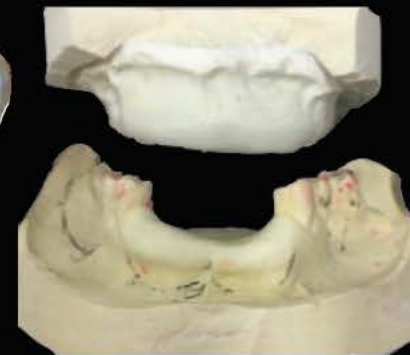
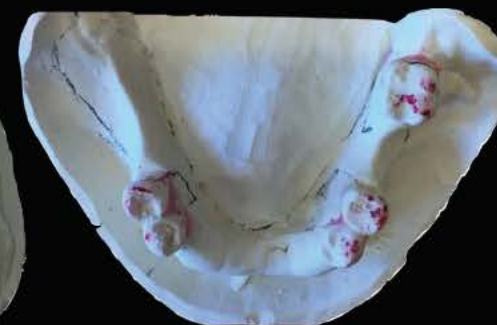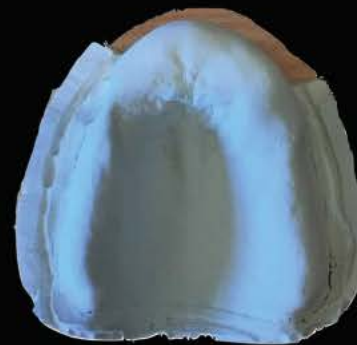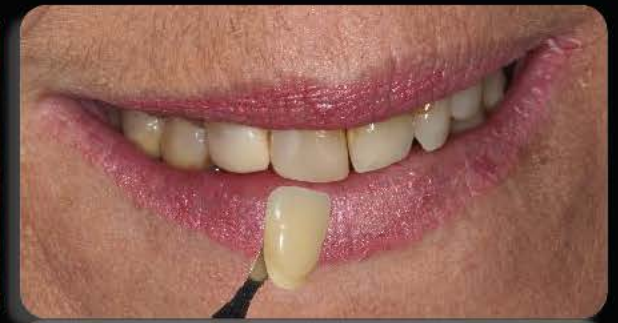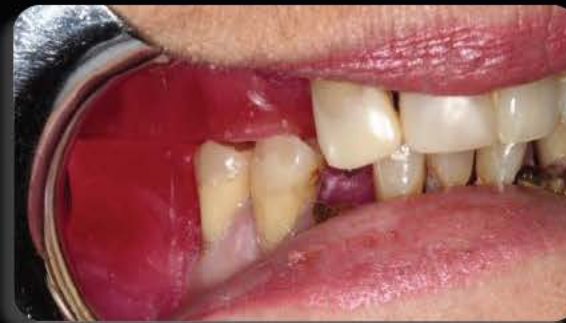1.20 Management plan – Reconstructive phase

- Immediate acrylic F/P work-up (Jogezai et al, 2018) (8/2018 - 2/2019)
 - Alginate impressions
 - Study models
 - Special trays – Campagna impression technique (Campagna, 1968) for Mx
 - Master models
 - Base and rims
 - Facebow & bite registration
 - Mounted master models

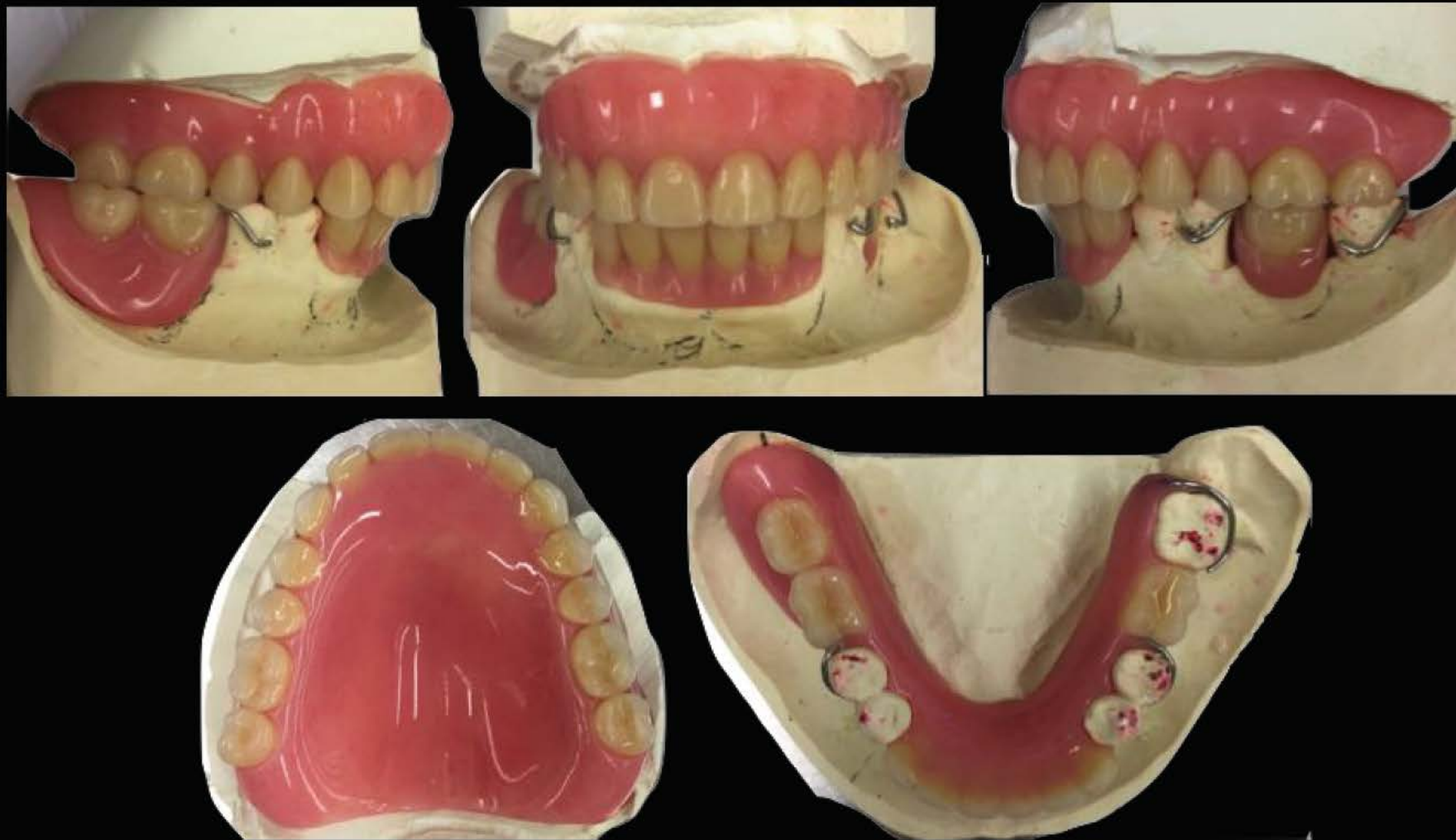


1.20 Management plan – Reconstructive phase

- Acrylic F/P work-up (Jogezai et al, 2018) (/2018 - 2019)
 - Shade selection - Vita Classical shade B3
 - Mx and Md casts marked with PPDs for teeth to be extracted to guide lab decoronation
 - Duplication of master casts
 - Wax up
 - Reduce Mx inc display by 1-2mm
 - Set Mx teeth following Pal surfaces
 - Process → acrylic F/P on mounted duplicates
 - Cross-mount to check fit and occlusion



1.20 Management plan – Reconstructive phase

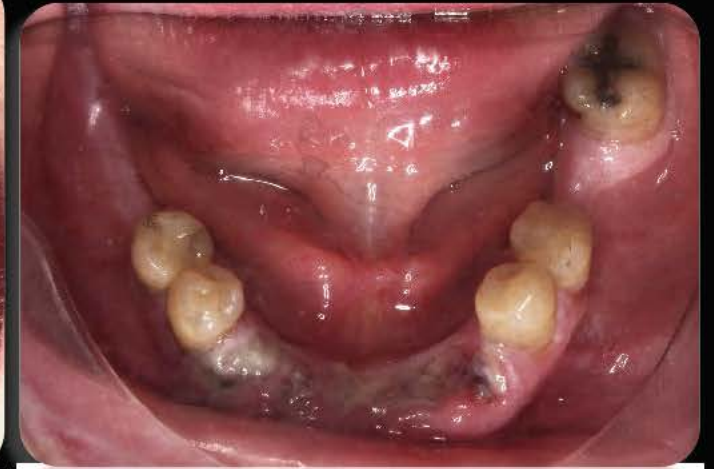
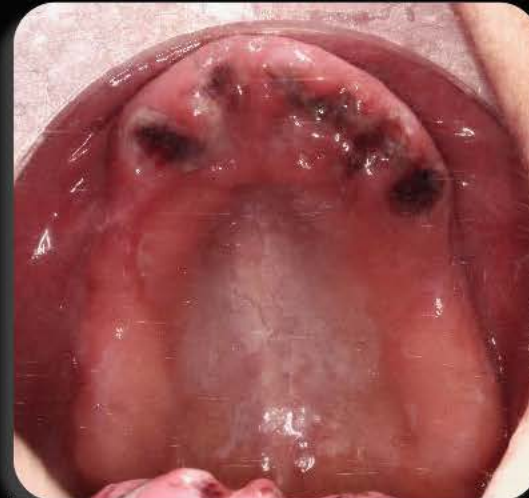
1.20 Management plan – Reconstructive phase

- **Pre-op extraction warnings**
 - Risk of bleeding, bruising, swelling, infection
 - Risk crown or root breaking
 - May require surgical procedure
- **Immediate F/P expectations**
 - Significant adaptation
 - Soreness immediately following exos
 - F/P will become loose after 4-6wks due to resorption of bone following exos
 - Temporary chairside relines every 3-4wks
 - Definitive reline at 6-12mths OR remake

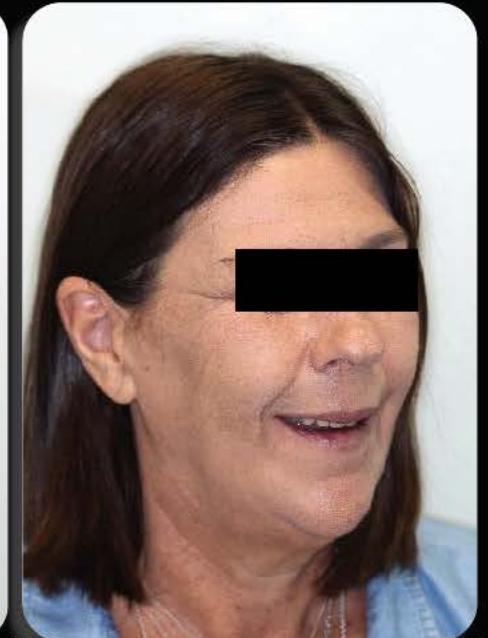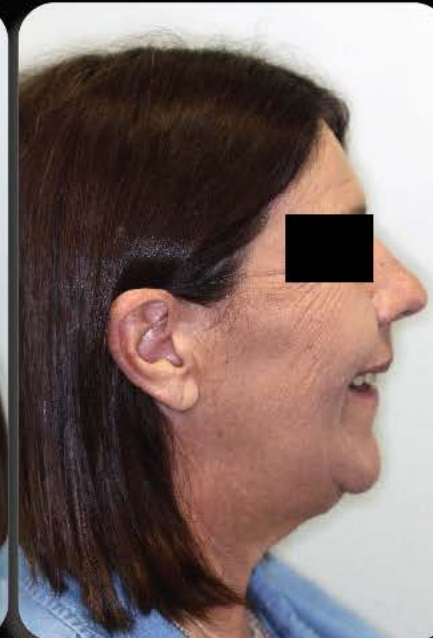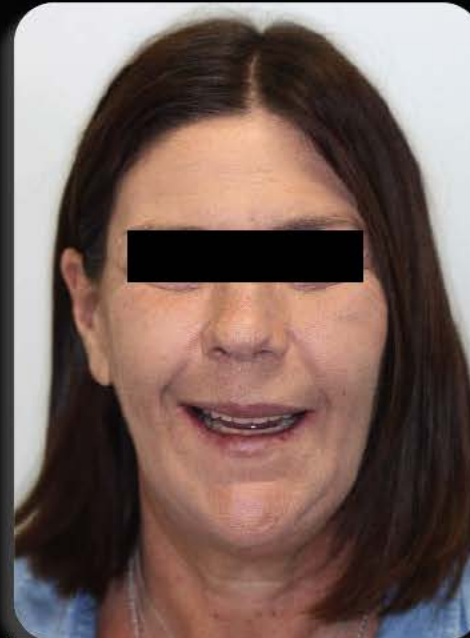1.20 Management plan – Definitive phase

- **Extractions (' /2019)**
 - Md – 31, 32, 33, 41, 42, 43
 - Mx – 11, 13, 21, 22, 23, 24
 - Luxation of all teeth, extraction with forceps of intact teeth
 - Curettage – 24, 32, 33 (teeth with radiolucencies)
 - Exo sites checked for sharp bony protuberances
 - Sockets squeezed buccal-lingually
 - Haemostasis achieved
 - Post-op instructions
- **Insert of acrylic F/P (' /2019)**
 - F/- did not require adjustment
 - -/P required adjustment for full seating and occlusal adjustment
 - Excellent fit, retention, stability and aesthetics
 - Post-op instructions



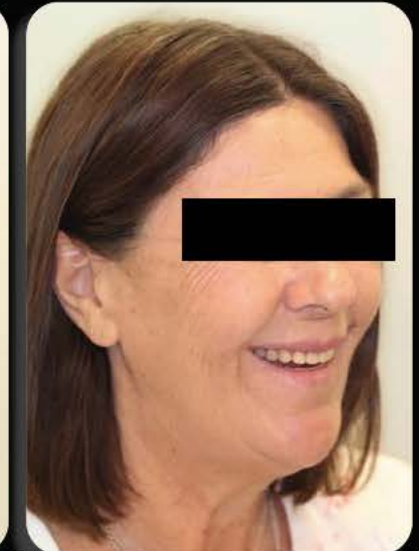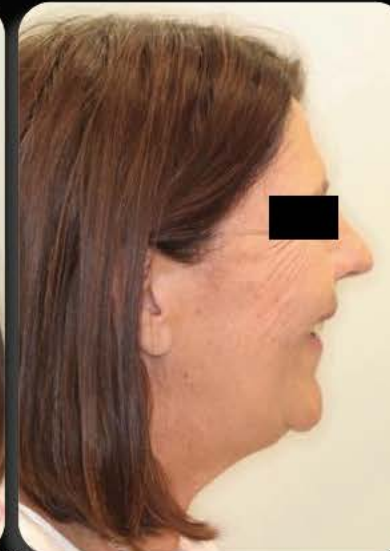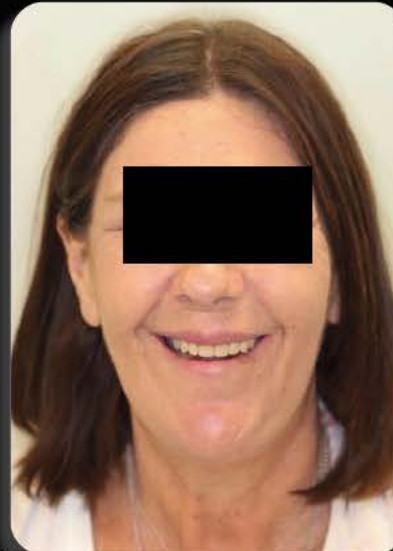1.20 Management plan – Definitive phase

- 24hr review (2019)
 - Pt returned sore and swollen
 - Extremely pleased with aesthetic result
 - Adjusted sore spots and occlusion
 - Re-emphasised home care routine for the next week



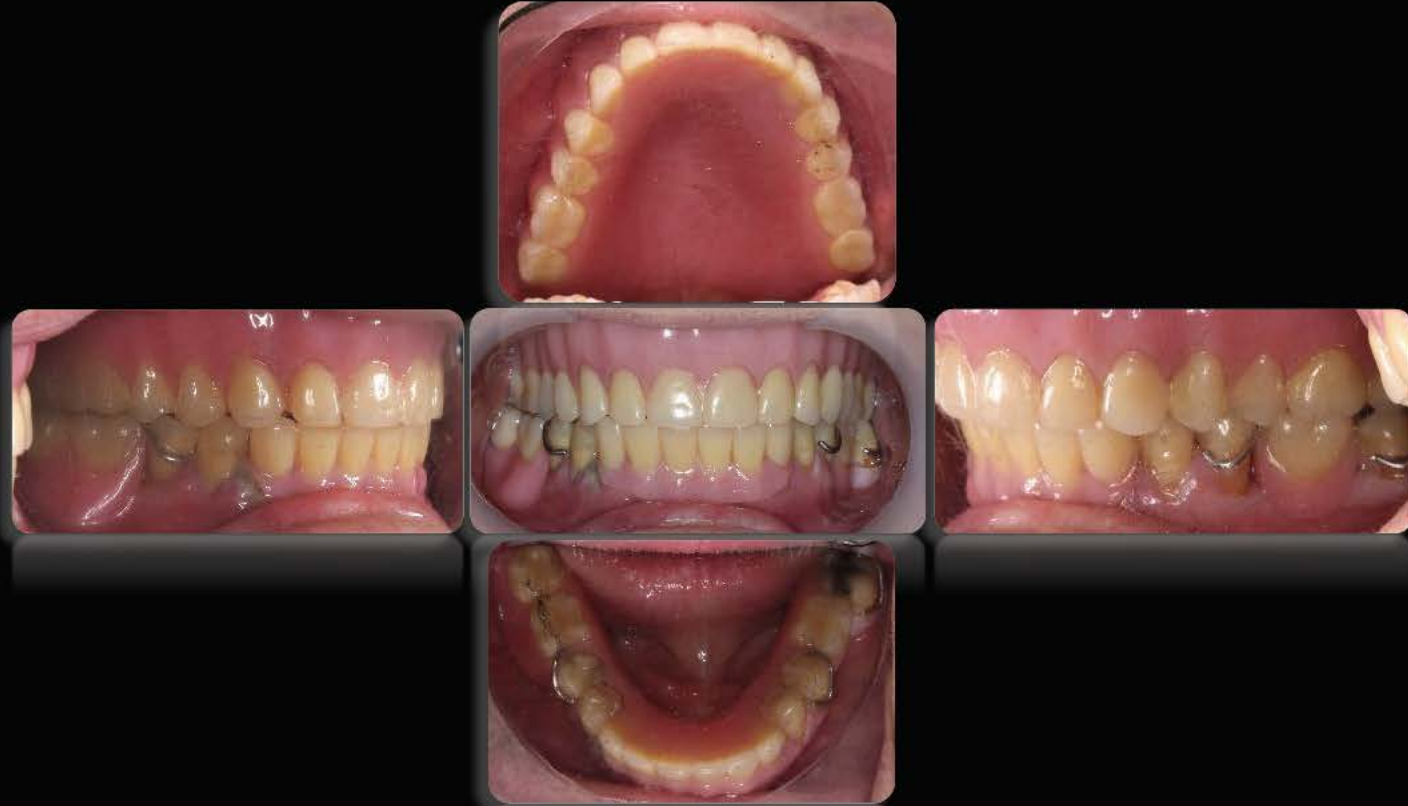1.20 Management plan – Definitive phase

- 1wk review (12/2019)
 - Pt remained extremely pleased with the aesthetic result
 - Compliments from friends, family, colleagues
 - Adjusted to relieve sore spots
 - Reinforced home care routine, and that acrylic F/P will become “loose” over the next few weeks as bone remodels



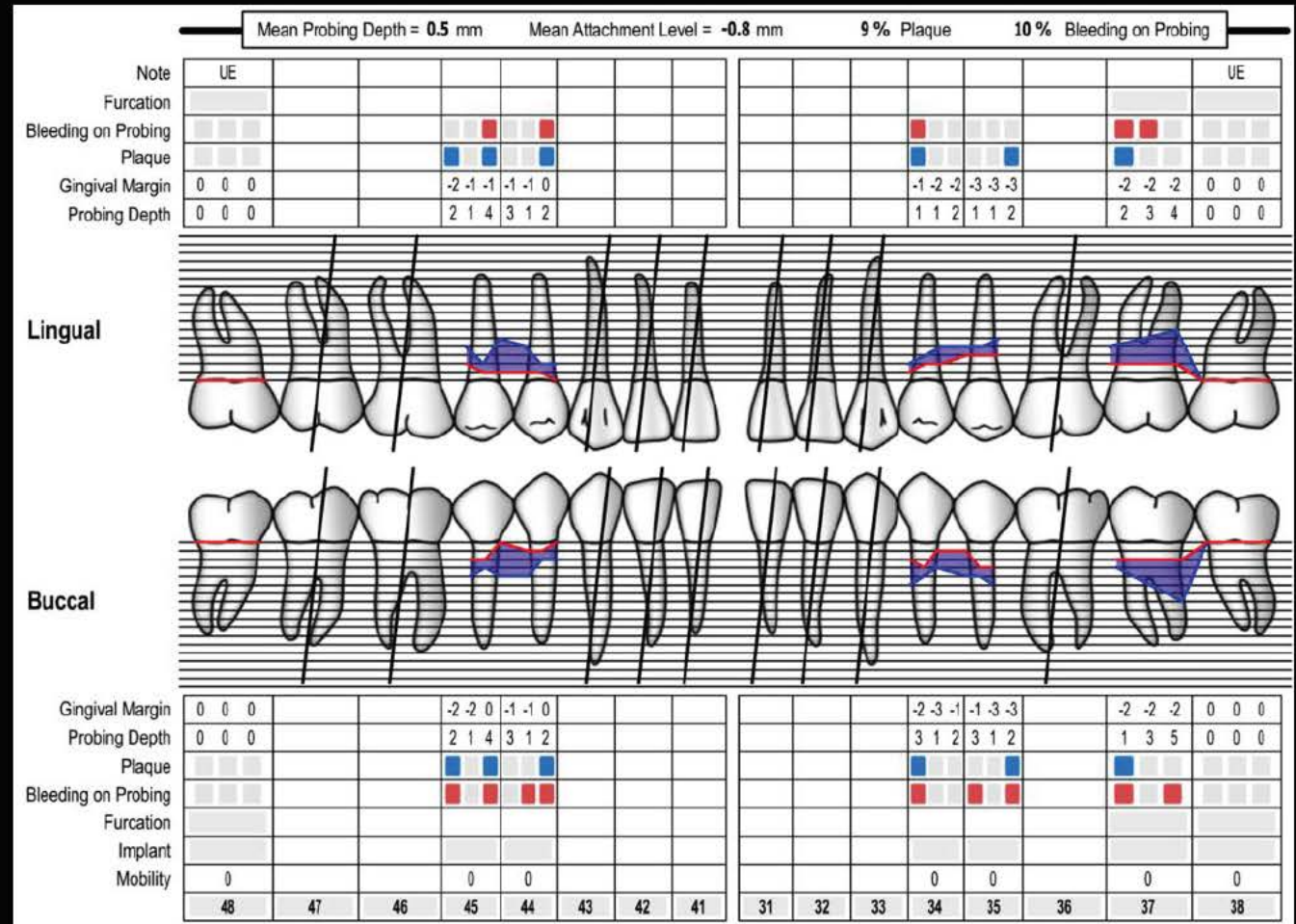
1.20 Management plan – Definitive phase

- 1wk review (/2019)
 - Pt remained extremely pleased with the aesthetic result
 - Compliments from friends, family, colleagues
 - Adjusted to relieve sore spots
 - Reinforced home care routine, and that acrylic F/P will become “loose” over the next few weeks as bone remodels



1.20 Management plan – Definitive phase

- Perio review (/2019)
 - Significant improvements in oral hygiene
 - PPDs remain
 - SRD
 - Reinforced lifestyle changes and OHI
 - Pt remains in **HIGH RISK** category

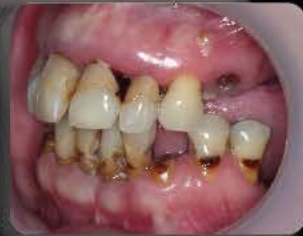
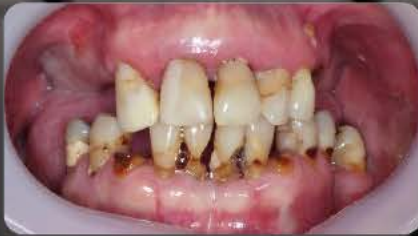
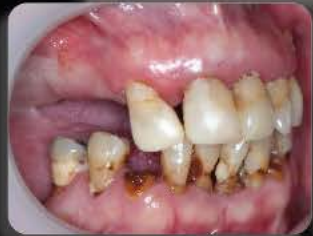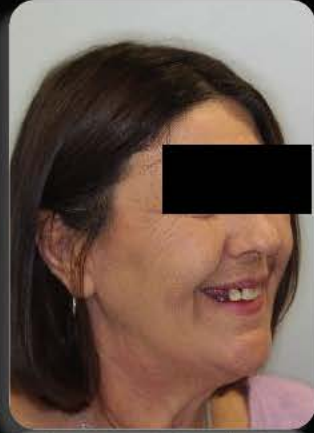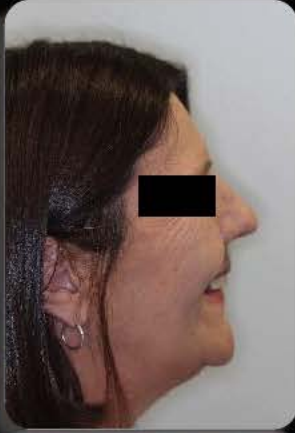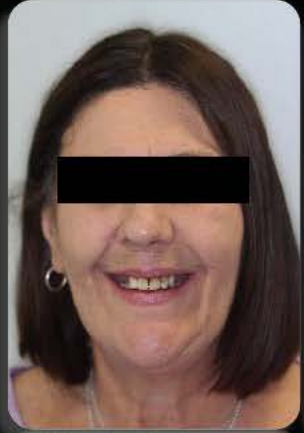1.20 Management plan – Definitive phase

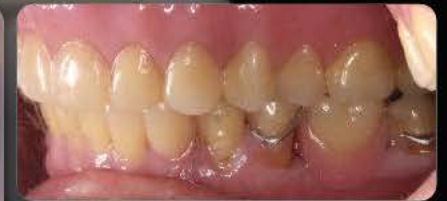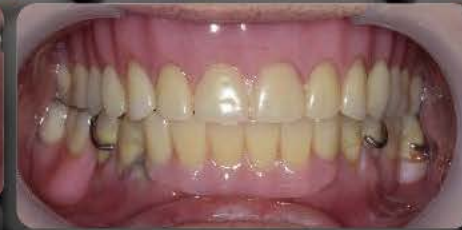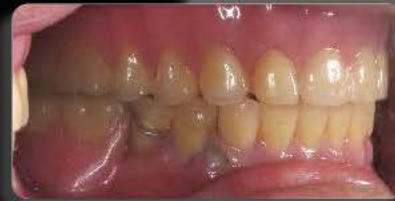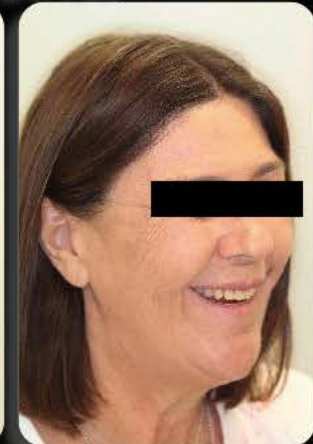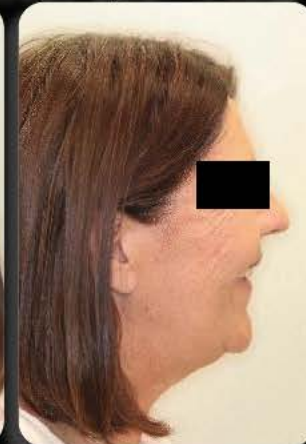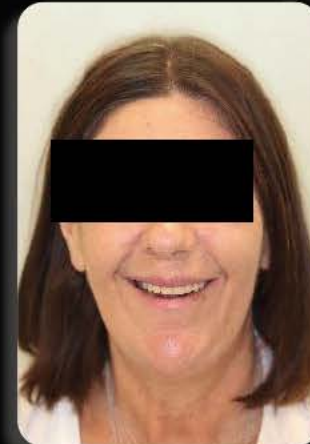- **First 3-4wk review (12/2019)**
 - **F/P starting to feel loose**
 - **Chairside reline with Viscogel soft liner**
- **Second 3-4wk review (1/19 and 2/19)**
 - **Pt adapting well to F/P, some looseness again**
 - **Chairside reline with Viscogel soft liner**
- **Third 3-4wk review (3/19)**
 - **Delayed review appt due to pt travelling**
 - **Pt reports minimal looseness of F/P, very happy w/ dentures**
 - **Final chairside reline with Viscogel liner**
 - **Informed pt definitive F/P reline can now take place, need to schedule 3 days for pt to be without dentures**

1.21 Before and after treatment photographs

Before (2018)



After (2018)



1.22 References

1. Abbott, P. V. (2004). Classification, diagnosis and clinical manifestations of apical periodontitis. *Endod Topics*, 8: 36-54.
2. Abbott, P. V., Yu, C. (2007). A clinical classification of the status of the pulp and the root canal system. *Aust Dent J*, 52(1 Suppl): S17-S31.
3. Armitage, G. C. (1999). Development of a classification system for periodontal diseases and conditions. *Ann Periodontol* 4(1): 1-6.
4. Australian Medicines Handbook (AMH). (2019). Clozapine. Retrieved from: <https://amhonline-amh-net-au.ezproxy.library.uwa.edu.au/chapters/psychotropic-drugs/antipsychotics/clozapine>
5. Australian Medicines Handbook (AMH). (2019). Fenofibrate. Retrieved from: <https://amhonline-amh-net-au.ezproxy.library.uwa.edu.au/chapters/cardiovascular-drugs/drugs-dyslipidaemia/fibrates/fenofibrate>
6. Australian Medicines Handbook (AMH). (2019). Levothyroxine. Retrieved from: <https://amhonline-amh-net-au.ezproxy.library.uwa.edu.au/search?q=levothyroxine>
7. Australian Medicines Handbook (AMH). (2019). Zopiclone. Retrieved from: <https://amhonline-amh-net-au.ezproxy.library.uwa.edu.au/chapters/psychotropic-drugs/drugs-anxiety-sleep-disorders/other-drugs-anxiety-sleep-disorders/zopiclone>
8. Campagna, S. J. (1968). An impression technique for immediate dentures. *J Pros Dent*, 20(3): 196-203.
9. Celebic, A., Knezovic-Zlatic, D. (2003). A comparison of patient's satisfaction between complete and partial removable denture wearers. *J Dent*, 31: 445-451.
10. Evans, R. W., Pakdaman, A., Dennison, P. J., Howe, E. L. C. (2008). The Caries Management System: an evidence-based preventive strategy for dental practitioners. Application for adults. *Aust Dent J*, 53: 83-92.
11. Jogežai, U., Laverty, D., Walmsley, A. D. (2018). Immediate dentures part 1: Assessment and treatment planning. *Dent Update*, 45: 617-624.
12. Jogežai, U., Laverty, D., Walmsley, A. D. (2018). Immediate dentures part 2: Denture construction. *Dent Update*, 45: 720-726.
13. Lang, N. P., Tonetti, M. S. (2003). Periodontal risk assessment (PRA) for patients in supportive periodontal therapy (SPT). *Oral Health Prev Dent*, 1: 7-16.
14. McGarry, T. J., Nimmo, A., Skiba, J. F., Ahlstrom, R. H., Smith, C. R., Koumjian, J. H., Arbree, N. S. (2002). Classification system for partial edentulism. *J Prosthodont*, 11(3): 181-193.
15. Papapanou, P. N., Sanz, M., Buduneli, N., Dietrich, T., Feres, M., Fine, D. H., ... Tonetti, M. S. (2018). Periodontitis: Consensus report of workgroup 2 of the 2017 World Workshop on the Classification of Periodontal and Peri-Implant Diseases and Conditions. *J Clin Periodontol*, 45(Suppl 20): S162-S170.
16. Samet, N., Jotkowitz, A. (2009). Classification and prognosis evaluation of individual teeth - A comprehensive approach. *Quintessence Int*, 40: 377-387.
17. Therapeutic Guidelines. (2012). Dental management of patients with medical conditions. Retrieved from: https://tgldcdp-tg-org-au.ezproxy.library.uwa.edu.au/viewTopic?topicfile=dental-management-of-patients-with-medical-conditions&guidelineName=Oral%20and%20Dental#toc_d1e731
18. The Royal Australian College of General Practitioners (RACGP). (2019). The 5A's structure for smoking cessation. Retrieved from: <https://www.racgp.org.au/clinical-resources/clinical-guidelines/key-racgp-guidelines/view-all-racgp-guidelines/supporting-smoking-cessation/the-5as-structure>
19. Wolff, A., Joshi, R. K., Ekstrom, J., Aframian, D., Pedersen, A. M. L., Proctor, G., ... Dawes, Colin. (2017). A guide to medications inducing salivary gland dysfunction, xerostomia, and subjective sialorrhea: A systematic review sponsored by the World Workshop on Oral Medicine VI. *Drugs R D*, 17: 1-28.