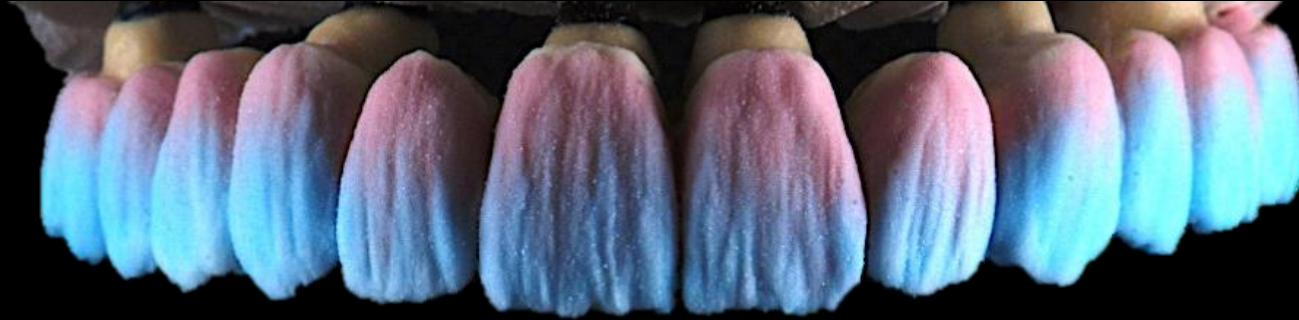
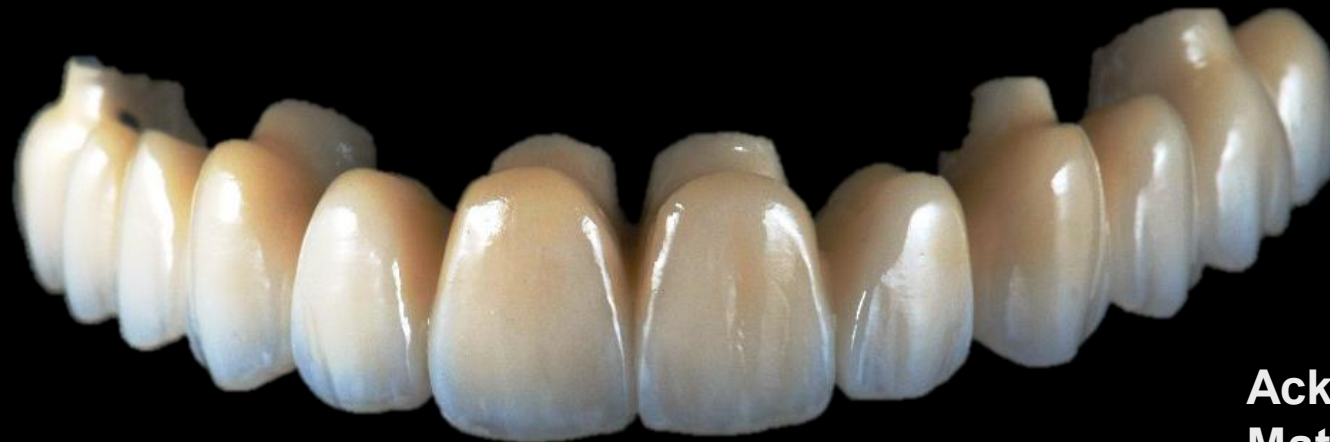


Fixed Dental Prosthesis

COMPONENTS



Acknowledgements to Dr
Matsubara

Before we begin

Going over DMD2 single unit indirect restoration exam answers

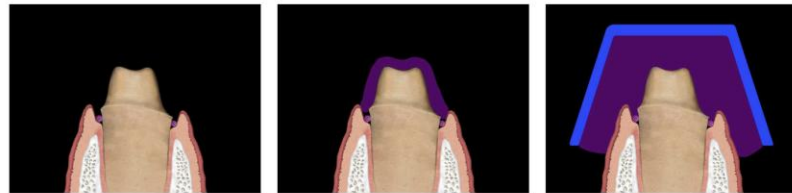
- Overall exam was completed well, good understanding of some dental materials
- Some incorrect answers regarding the steps of impressions
- Answers also need to be clearer

1. Please outline in dot points the clinical steps of **EACH** pair of two different impression techniques. For each listed **PAIR** of impression techniques, also state which technique is more accurate?
 - a. PVS Monophase vs PVS Dual phase
 - a. Putty wash 1-step vs Putty wash 2-step

Please only write 4-6 dot points per sub-section.

Before we begin

Monophase



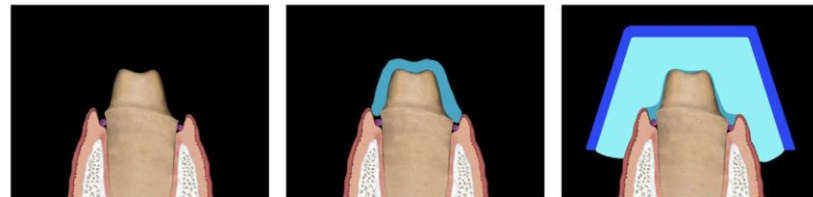
preparation with
retraction cord

preparation covered with
impression material

tray inserted with the same
impression material

NOT RECCOMENDED DUE TO LOWER DEFINITION

Dualphase – “Putty Wash”



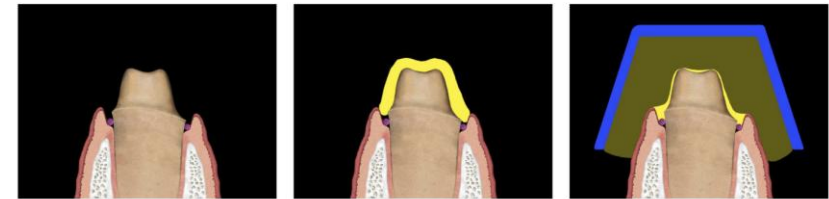
preparation with
retraction cord

preparation covered with
lightbody (LB) material

tray inserted with
putty material

One-step putty impressions can have significantly lower accuracy compared to two step impressions

Dualphase – Lightbody & Heavybody

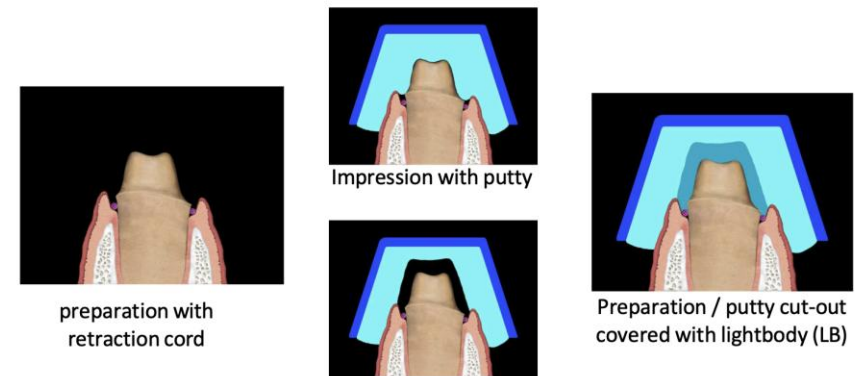


preparation with
retraction cord

preparation covered with
lightbody (LB) material

tray inserted with
heavy body (HB) material

Two-step impression with Putty



preparation with
retraction cord

Impression with putty

Putty cut-out

Preparation / putty cut-out
covered with lightbody (LB)

Good accuracy

Before we begin

1. Please outline in dot points the clinical steps of **EACH** pair of two different impression techniques. For each listed **PAIR** of impression techniques, also state which technique is more accurate?
 - PVS Monophase vs PVS Dual phase
 - Putty wash 1-step vs Putty wash 2-step

Please only write 4-6 dot points per sub-section.

Answer I was looking for:

PVS Monophase: **Medium/Heavy body PVS** material in the **tray** + on the **preparation**

PVS Dualphase: **Heavy/medium body PVS** material in the **tray**, **Lightbody PVS** material expressed on the **tooth**

Putty wash 1-step: **Putty mixed and placed into tray**, **light body PVS** expressed onto the prepared **tooth** and **tray immediately inserted**.

Putty wash 2-step: **Putty mixed and placed into tray**. **Tray inserted** into the mouth, impression taken and removed from mouth. **Cut out area** around prepared tooth. **Light body PVS** applied on prepared tooth, impression taken using putty/tray unit.

Before we begin

Answer I was looking for:

PVS Monophase: **Medium/Heavy body PVS** material in the **tray** + on the **preparation**

PVS Dualphase: **Heavy/medium body PVS** material in the **tray**, **Lightbody PVS** material expressed on the **tooth**

Putty wash 1-step: **Putty mixed and placed into tray**, **light body PVS** expressed onto the prepared **tooth** and **tray immediately inserted**.

Putty wash 2-step: **Putty mixed and placed into tray**. **Tray inserted** into the mouth, impression taken and removed from mouth. **Cut out area** around prepared tooth. **Light body PVS** applied on prepared tooth, impression taken using putty/tray unit.

Not able to award full marks if you:

- Did not specify the impression material used. “impression material placed on tooth” (*what impression materials? Light body? Heavy body? Alginate?*)

Confusion seems to exist regarding the Putty wash 1-step vs Putty wash 2-step. Some answers said you take impression with the putty, then apply the light body onto the putty.

Module Overview



THE UNIVERSITY OF
**WESTERN
AUSTRALIA**



Oral Health Centre
of Western Australia

- Practical assessment: Bridge preparation + provisional bridge (marking rubric will be released to you later)
 - Formative assessment: 13/04/26
(No weighting)
 - Summative assessment: 11/05/26 (the timetable columns seem to be jumbled up)
(50% of module)
- Workbook to be completed
- Theoretical exam: Held at main campus, main round exam time.
(50% of module)
 - MCQs and SAQs
 - Likely as combined exam with FPD

Please note both the summative assessment and theoretical exams need to be passed (50%+) to successfully pass the module. The summative assessment is made of TWO components, which must be independently passed (50%+ must be achieved on both tasks).

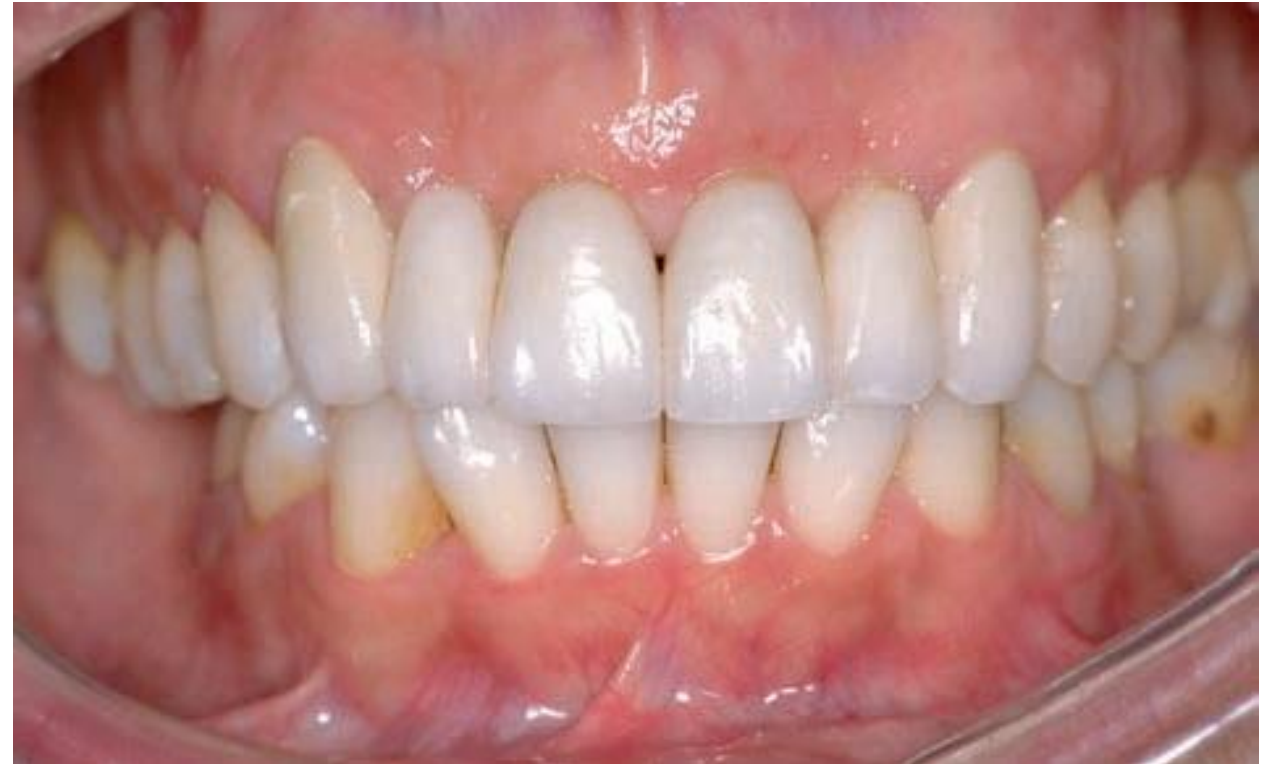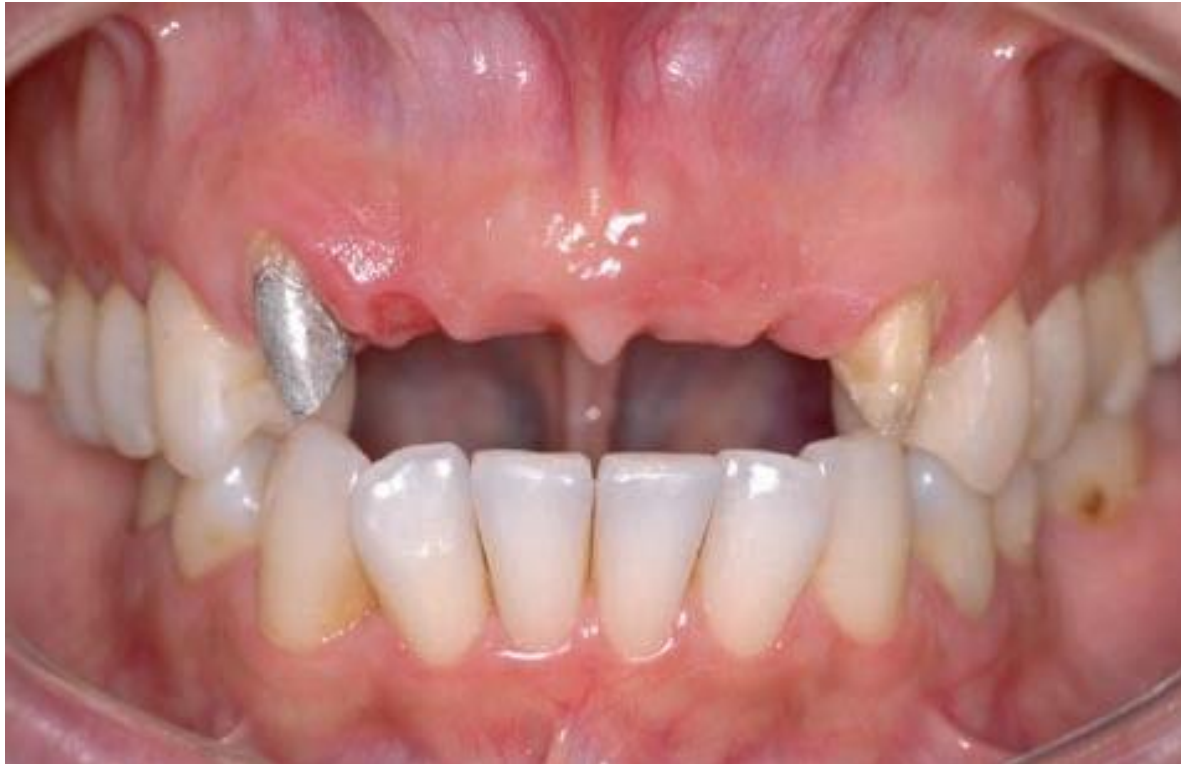Learning outcomes

Learning outcomes:

- Discuss the components of a fixed partial prosthesis
- Discuss the principles of tooth preparation: Biological, Aesthetic and Mechanical
- Understand the concept of Path of Insertion
- Discuss different designs of retainers
- Discuss different designs of pontics
- Discuss different types of connectors
- Understand the concept of Cantilever

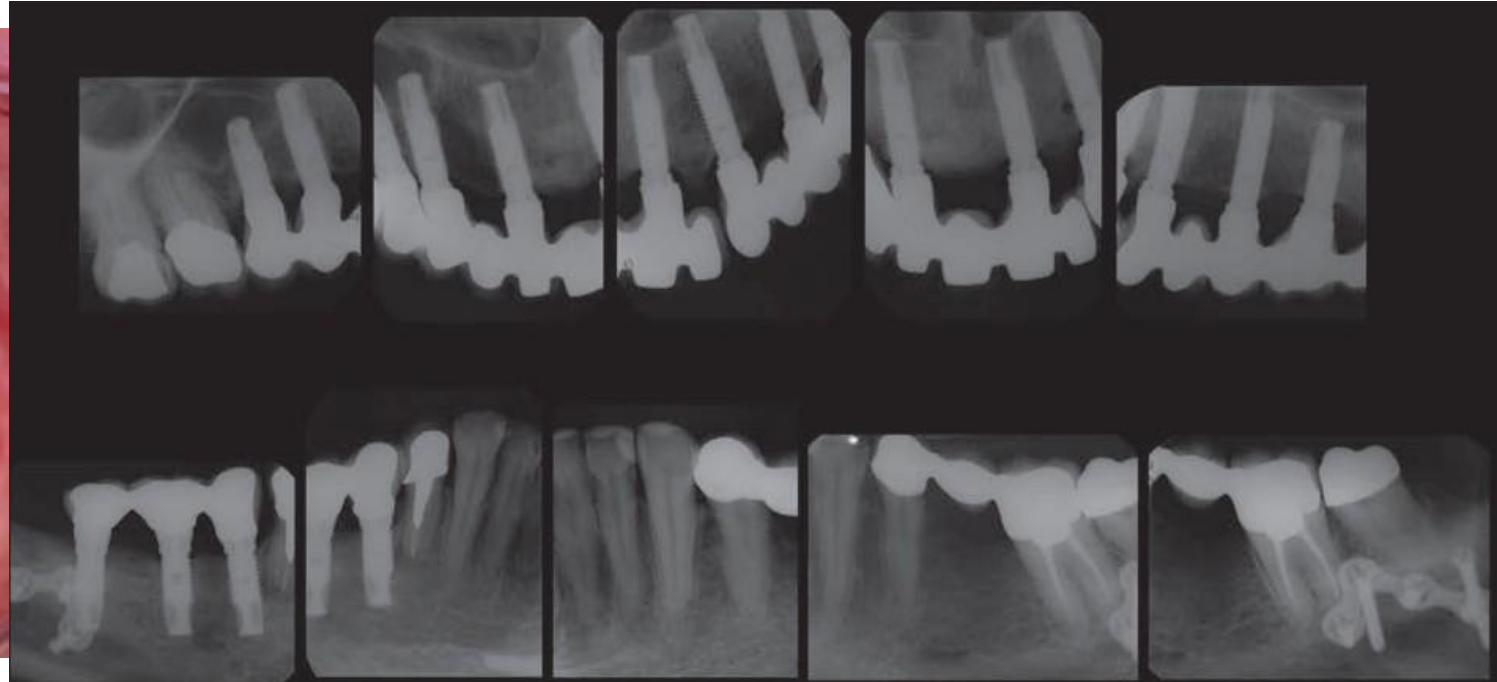
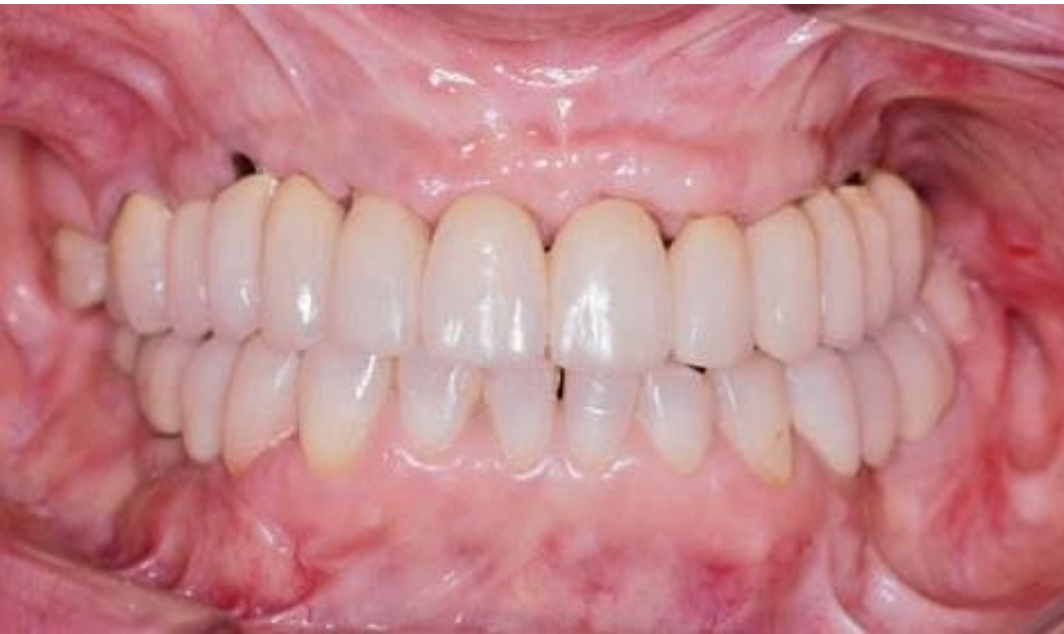Reading: Contemporary Fixed Prosthodontics: Chapter 20 Pontic Design

Tooth Supported Bridgework (Fixed partial prosthesis)





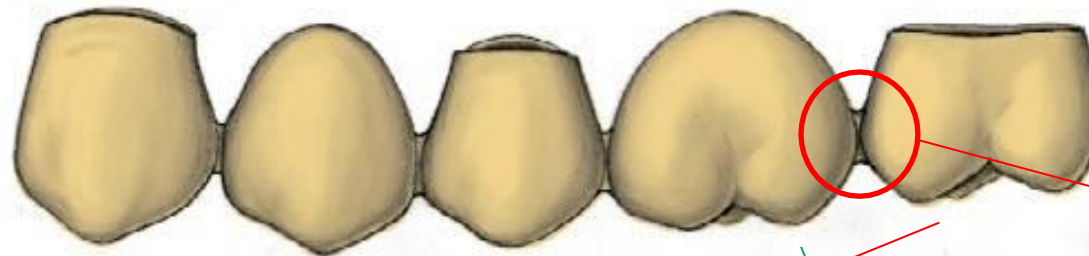
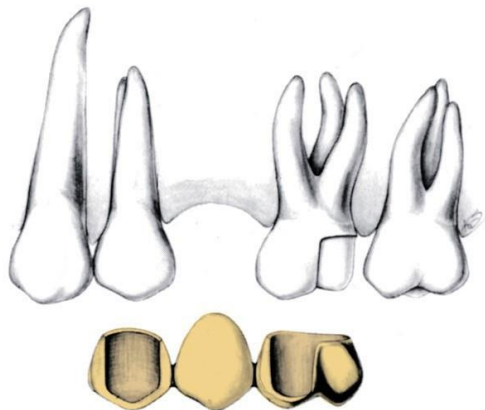
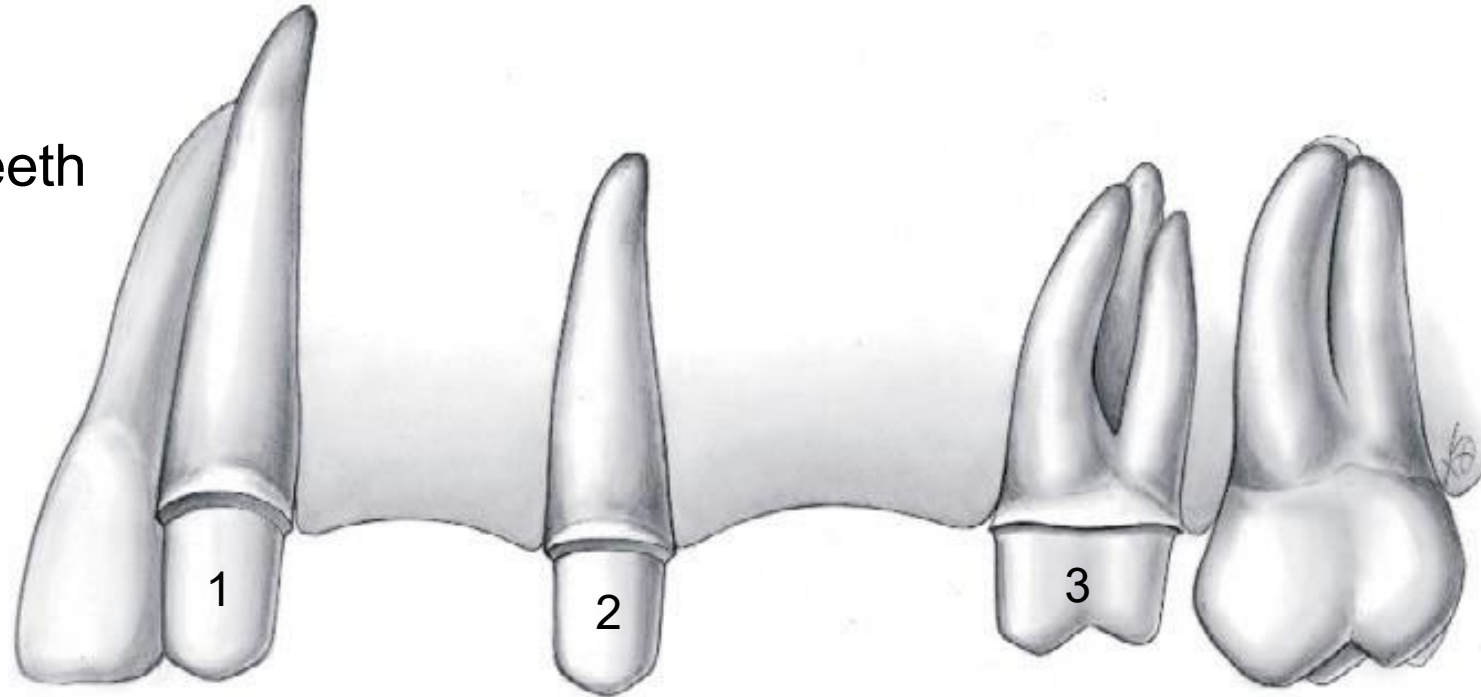
Implant Supported Bridgework



Components



1, 2, 3: Abutment teeth

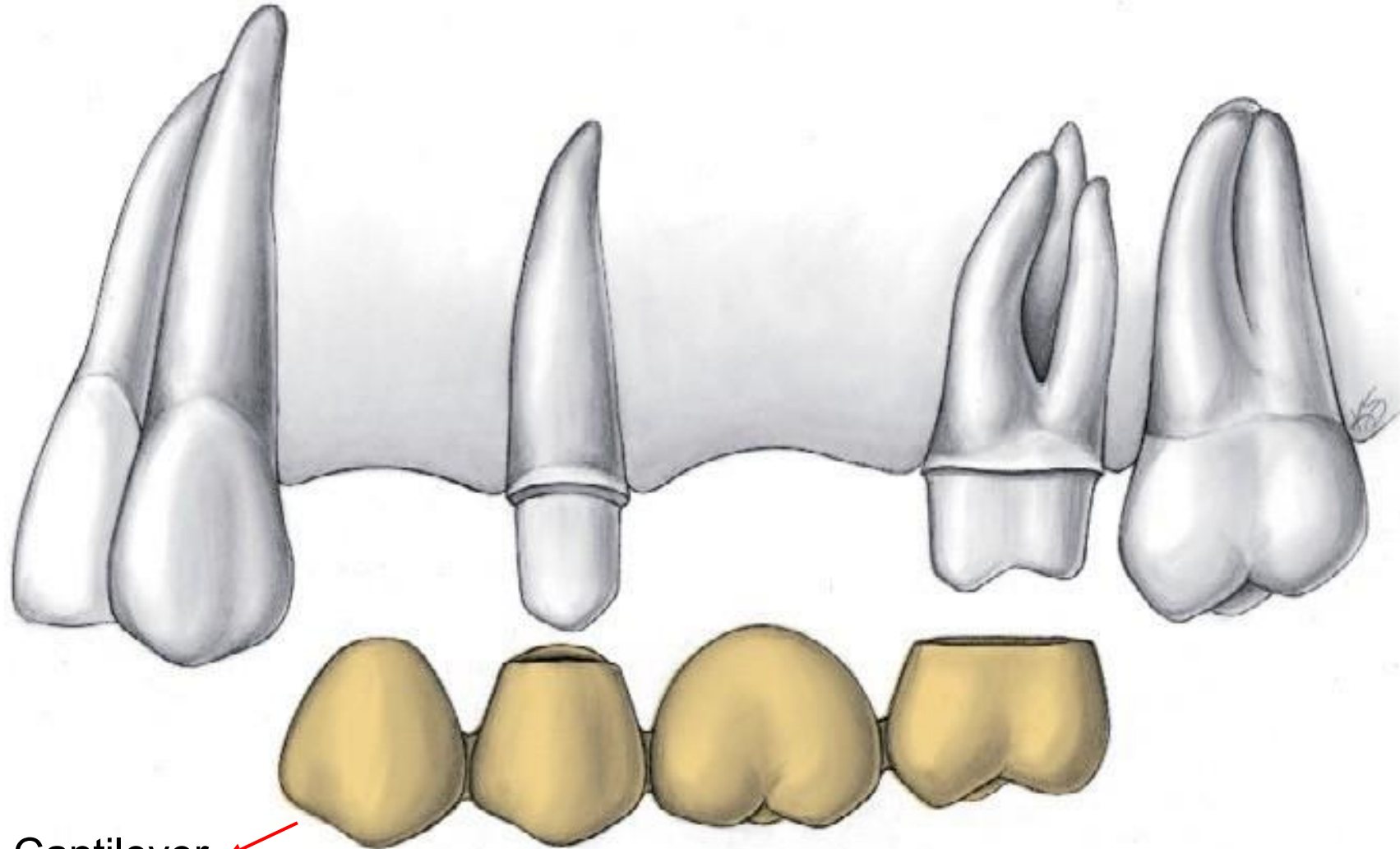


Connectors

Retainers

Pontics

Components



Cantilever

Components

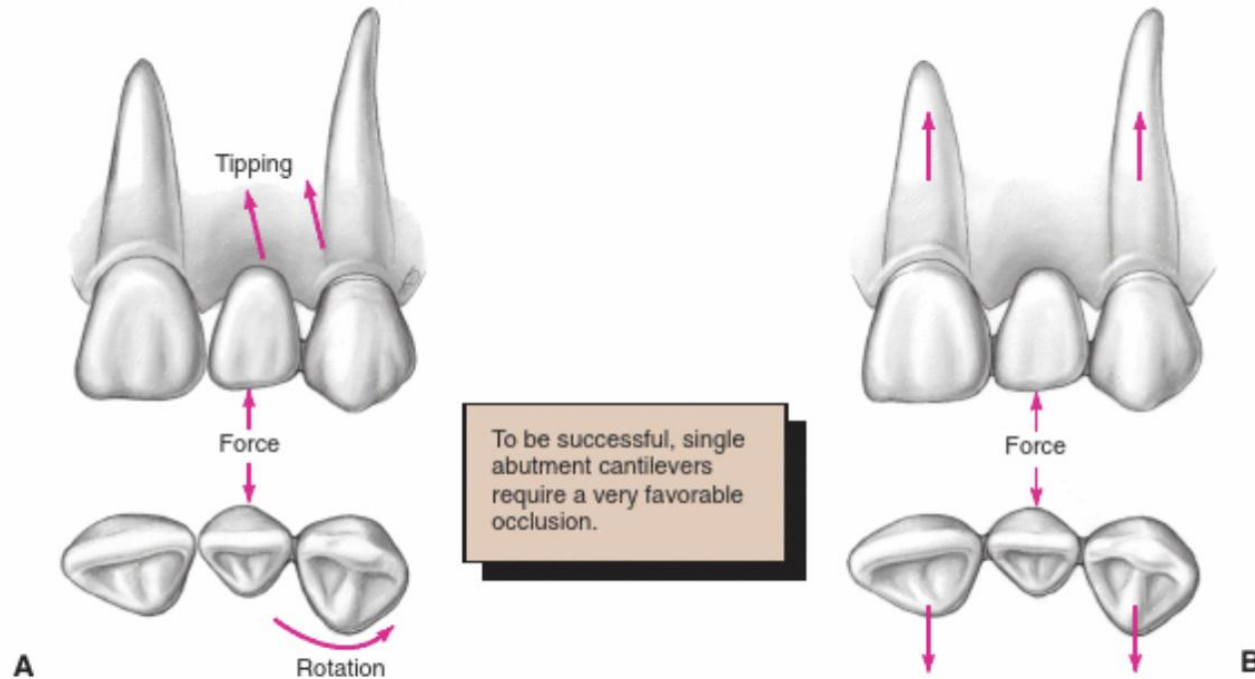
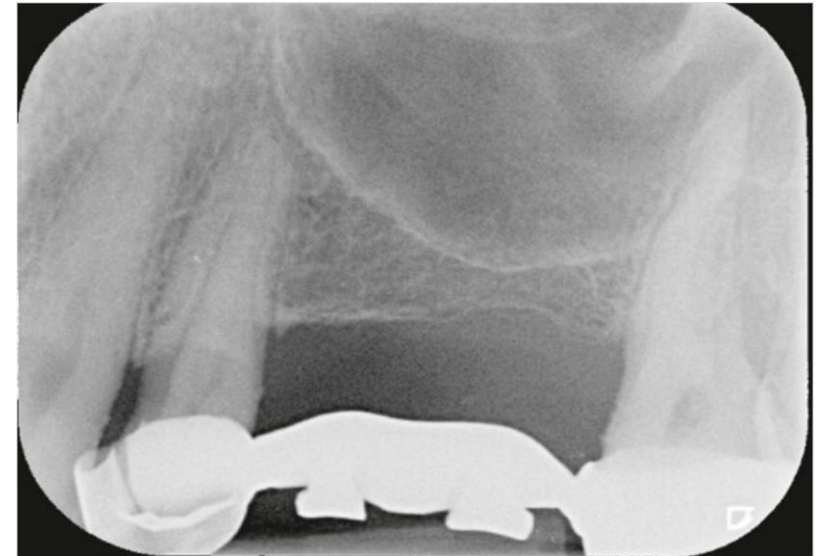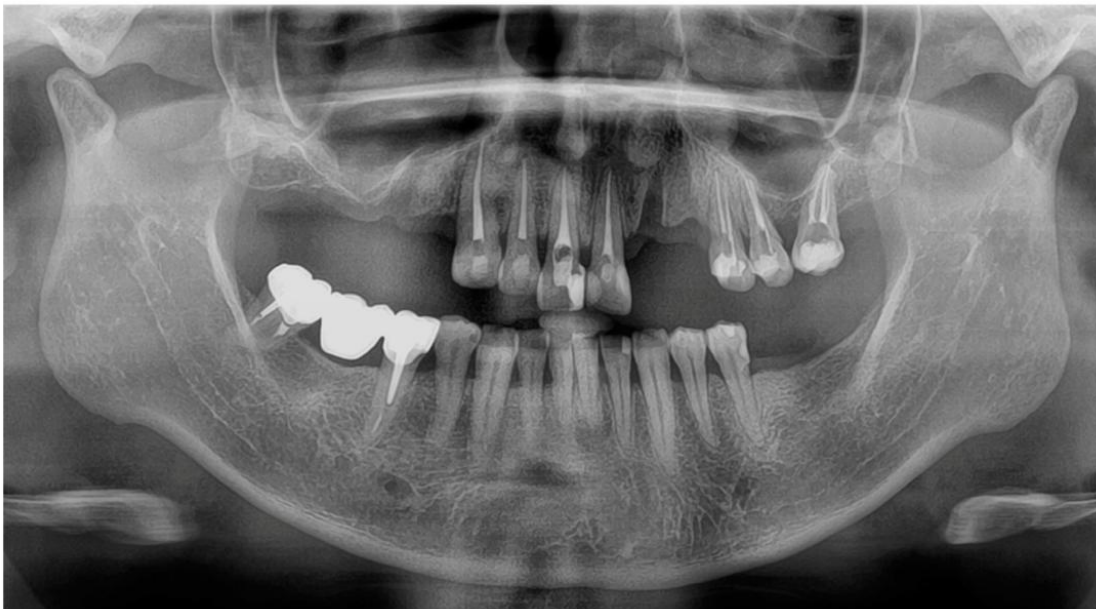


FIGURE 3-16 ■ **A**, Forces applied to a cantilever fixed dental prosthesis are resisted on only one side, which leads to imbalance. Vertical forces can cause tipping, and horizontal forces can cause rotation, of abutment teeth. **B**, By including both adjacent teeth in the prosthesis, it is possible to resist forces much better because the teeth have to be moved bodily rather than merely rotated or tipped. (Redrawn from Rosenstiel SF: Fixed bridgework—the basic principles. In Rayne J, ed: General Dental Treatment. London, Kluwer Publishing, 1983.)

Indications

When would we consider restoring teeth via FPDs?

- Patient unable/unwilling to accept removable options.
- Orthodontic reasons (replacement of missing lateral incisors)
- When adjacent teeth would also benefit from indirect restorations
- Patient not suited for implants (eg. Bone)
- Splinting teeth (Mentioned in textbooks, but I would suggested to proceed with care)



Insufficient bone height/dimensions for implant

Contra-indications



THE UNIVERSITY OF
**WESTERN
AUSTRALIA**



Oral Health Centre
of Western Australia

What do we have to be wary of?

- Poor periodontal status of abutments (Crown root ratio, Ante's law etc).
- Absence of distal abutment in posterior sections
- Long span bridges
- Poor OH
- Extremely tilted teeth (not firm contra-indication, but needs to be carefully assessed)

Recap: Components



ABUTMENT TOOTH

- Principles of tooth preparation
- Partial or complete preparation

BIOLOGICAL

- Conservation of tooth structure
- Avoidance of overcontouring
- Supragingival margins
- Harmonious occlusion
- Protection against tooth fracture

MECHANICAL

- Retention form
- Resistance form
- Deformation

AESTHETIC

- Minimum display of metal
- Maximum thickness of porcelain
- Porcelain occlusal surfaces
- Subgingival margins

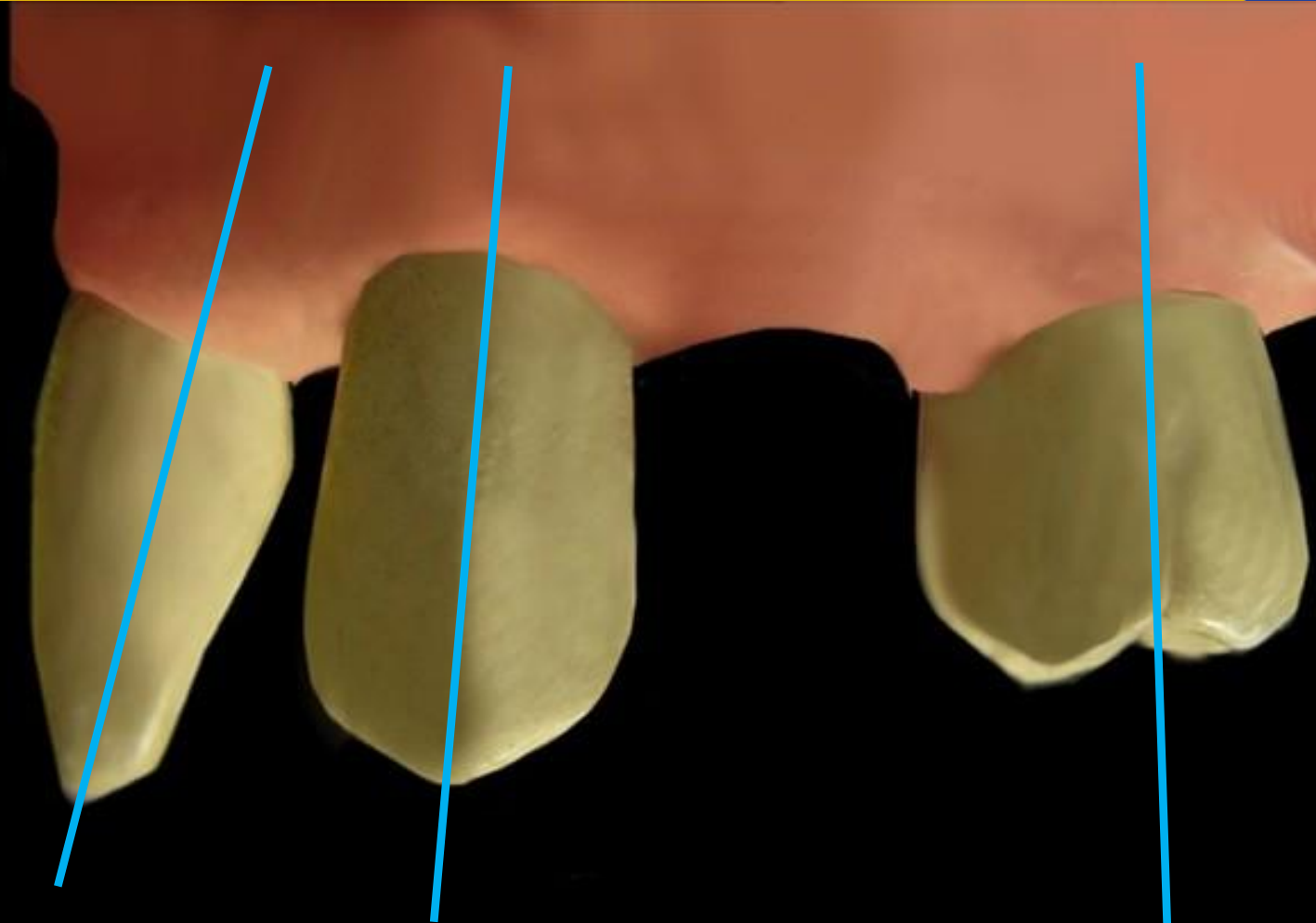
Components



THE UNIVERSITY OF
**WESTERN
AUSTRALIA**



Oral Health Centre
of Western Australia



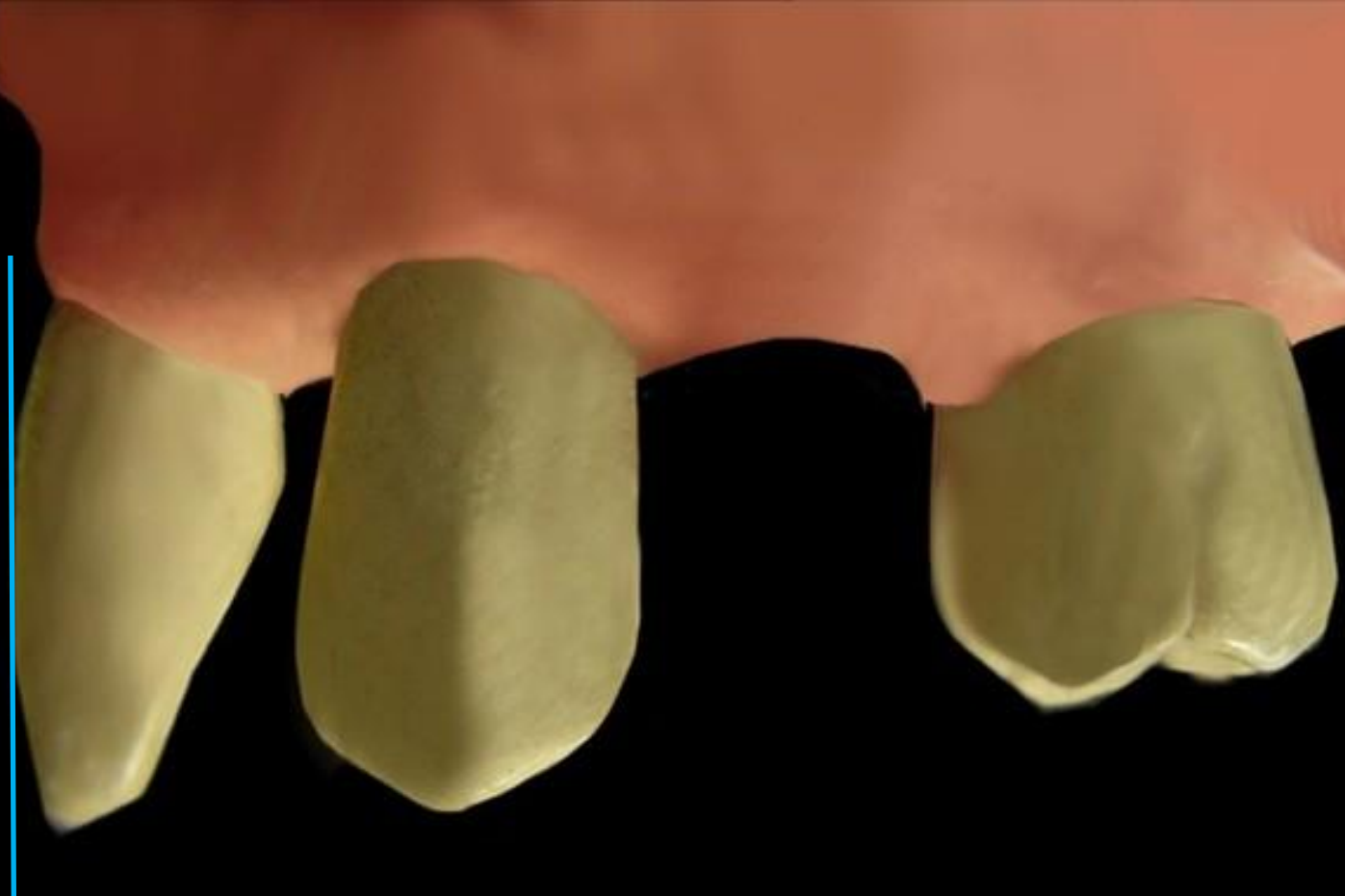
Components



THE UNIVERSITY OF
**WESTERN
AUSTRALIA**



Oral Health Centre
of Western Australia



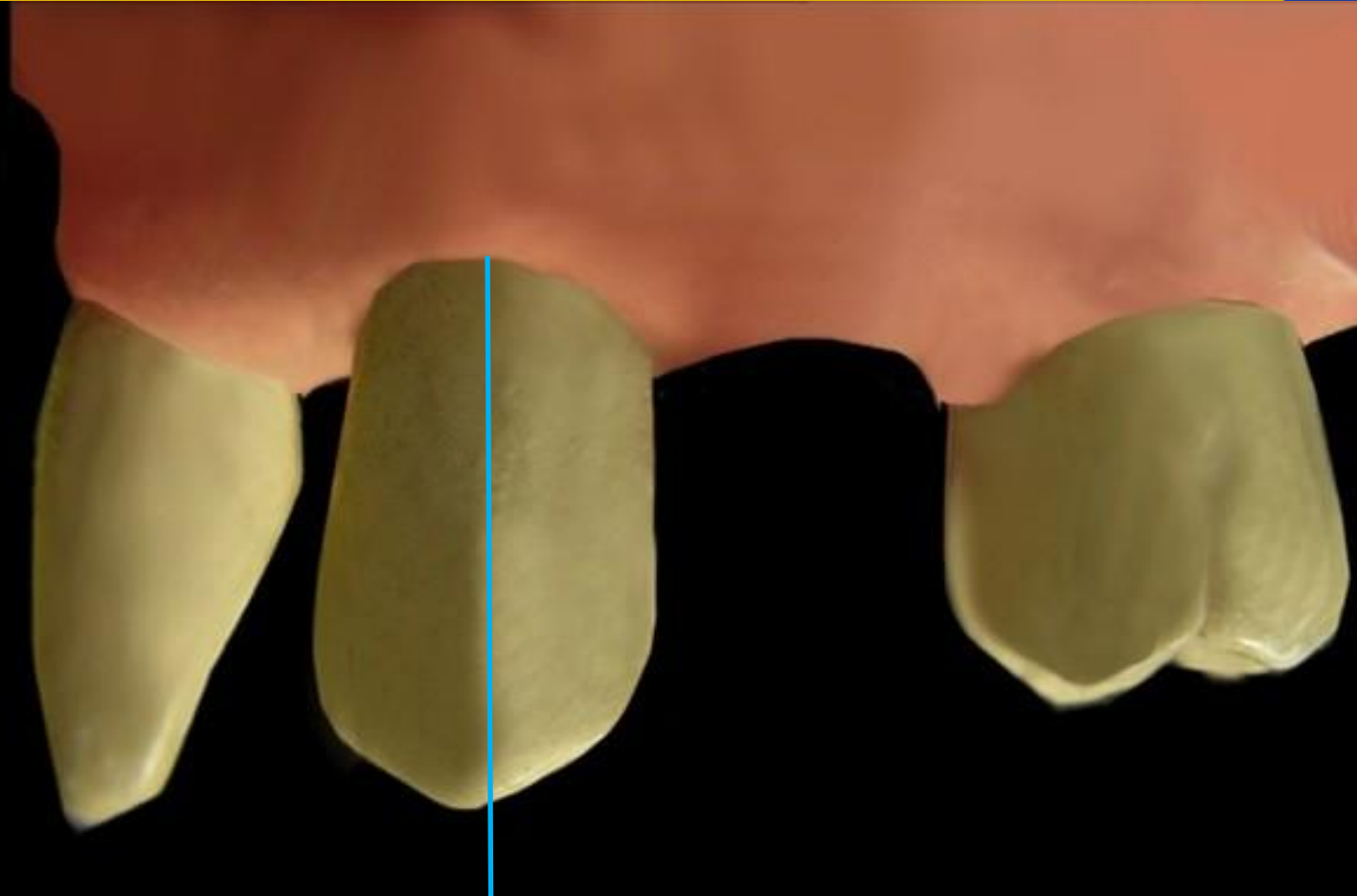
Components



THE UNIVERSITY OF
**WESTERN
AUSTRALIA**



Oral Health Centre
of Western Australia



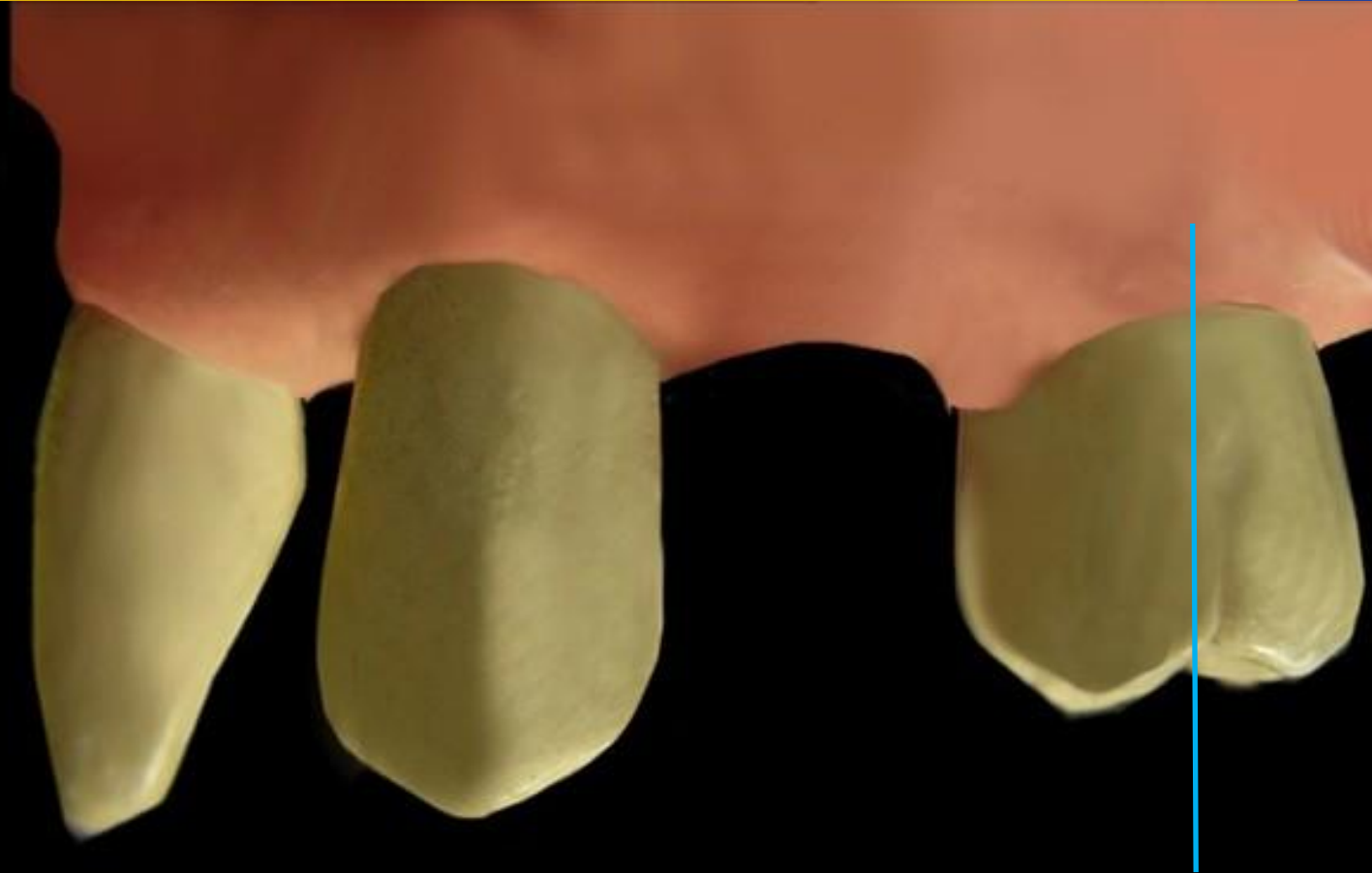
Components



THE UNIVERSITY OF
**WESTERN
AUSTRALIA**



Oral Health Centre
of Western Australia



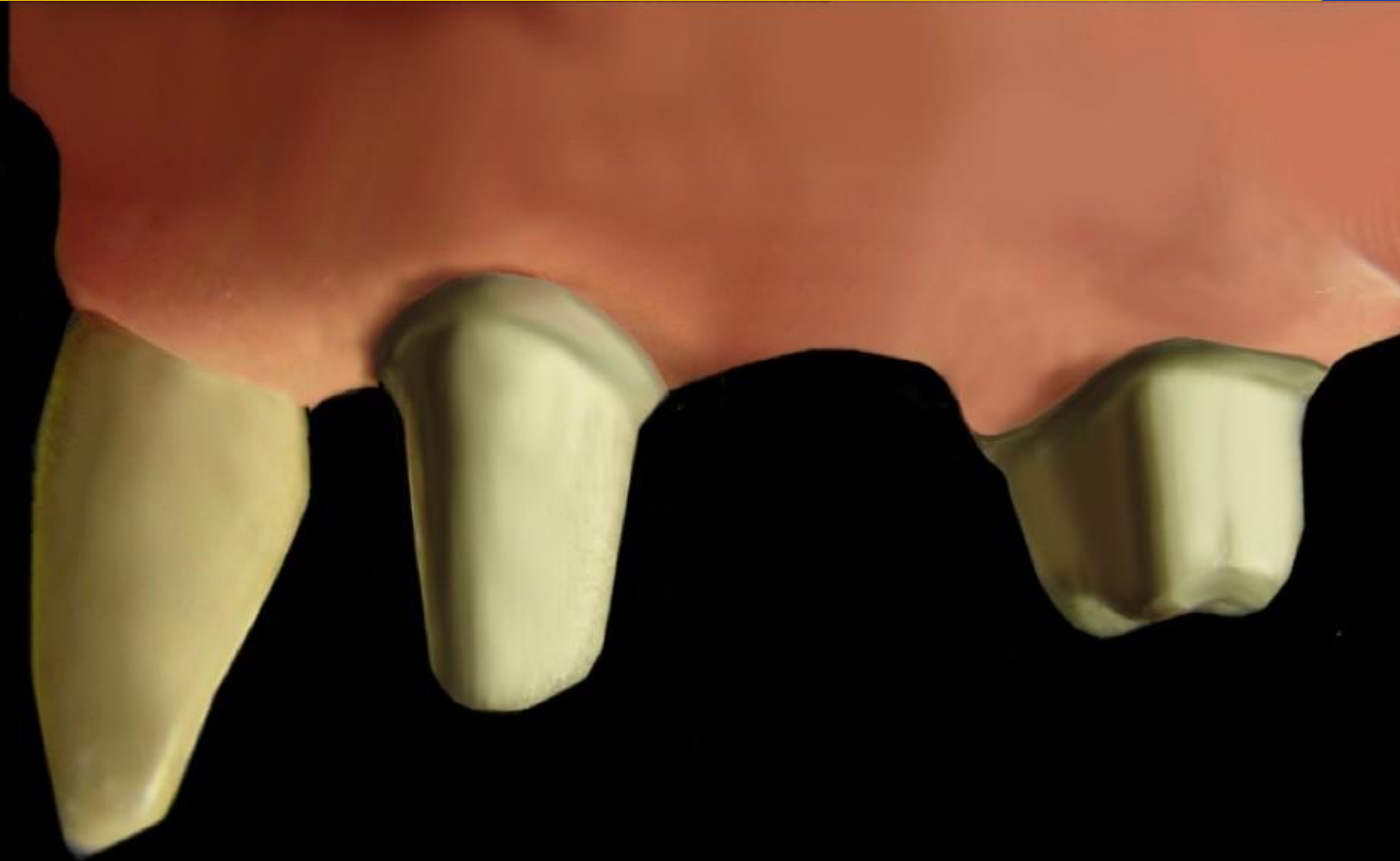Components



THE UNIVERSITY OF
**WESTERN
AUSTRALIA**



Oral Health Centre
of Western Australia



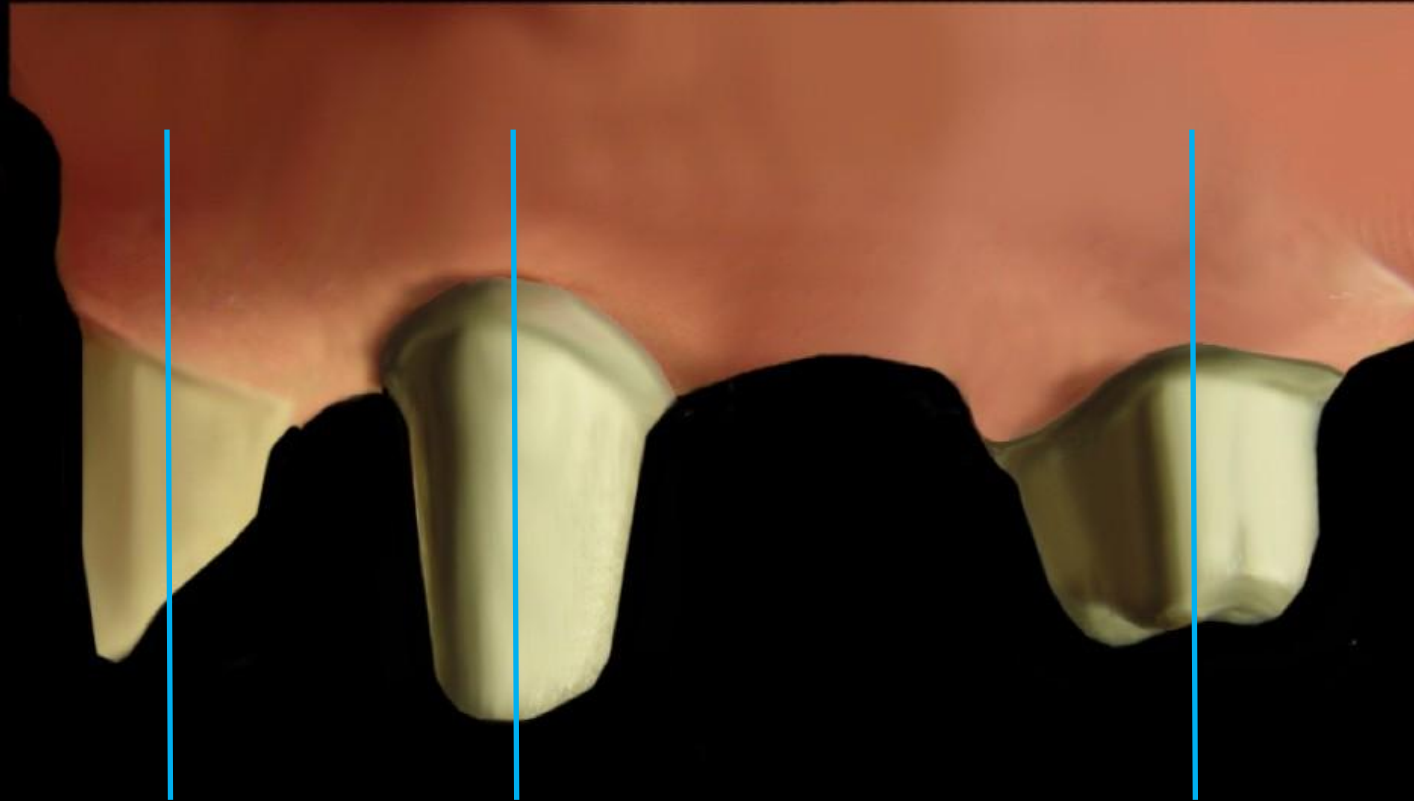
Components



THE UNIVERSITY OF
**WESTERN
AUSTRALIA**



Oral Health Centre
of Western Australia



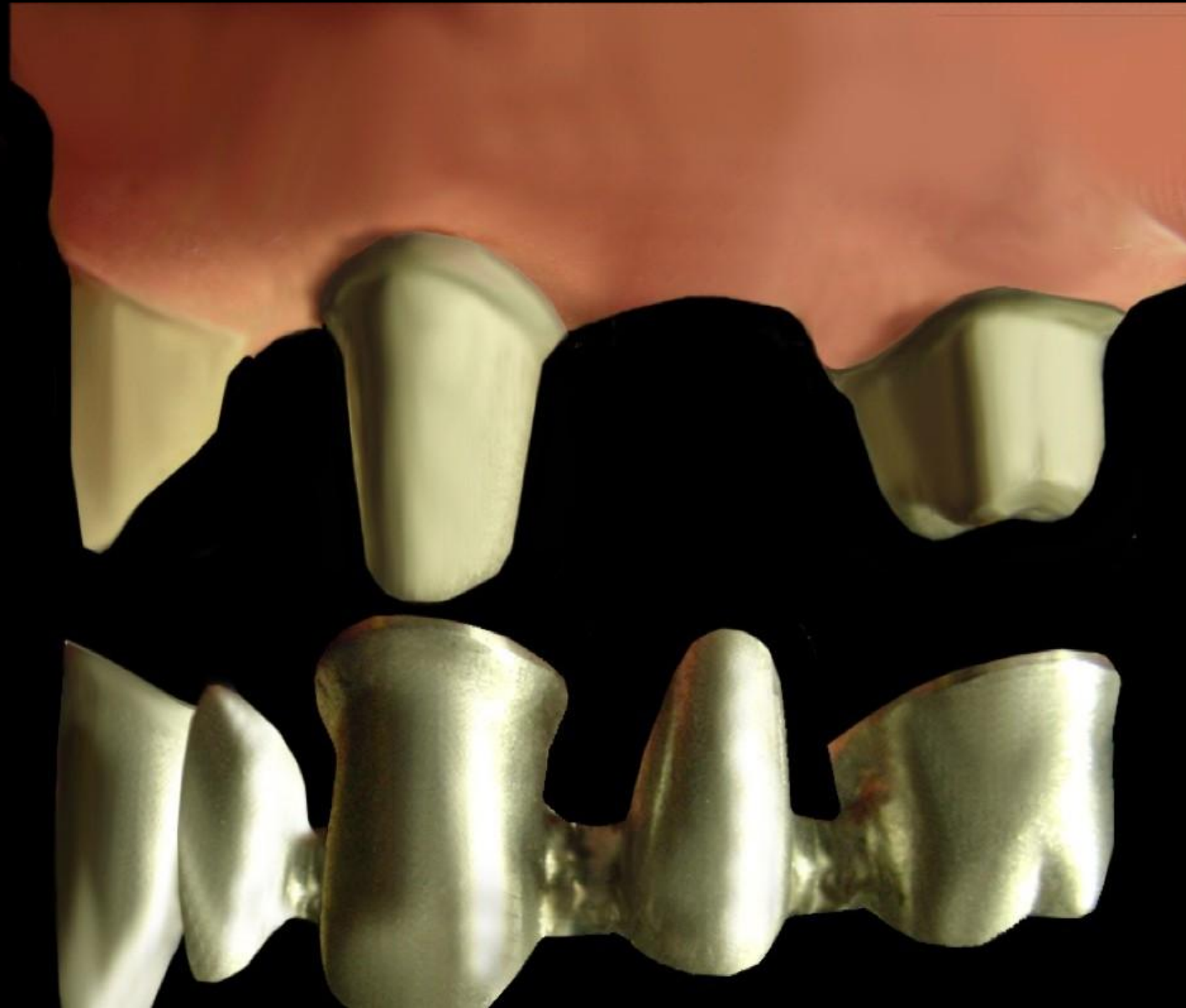Components



THE UNIVERSITY OF
**WESTERN
AUSTRALIA**



Oral Health Centre
of Western Australia



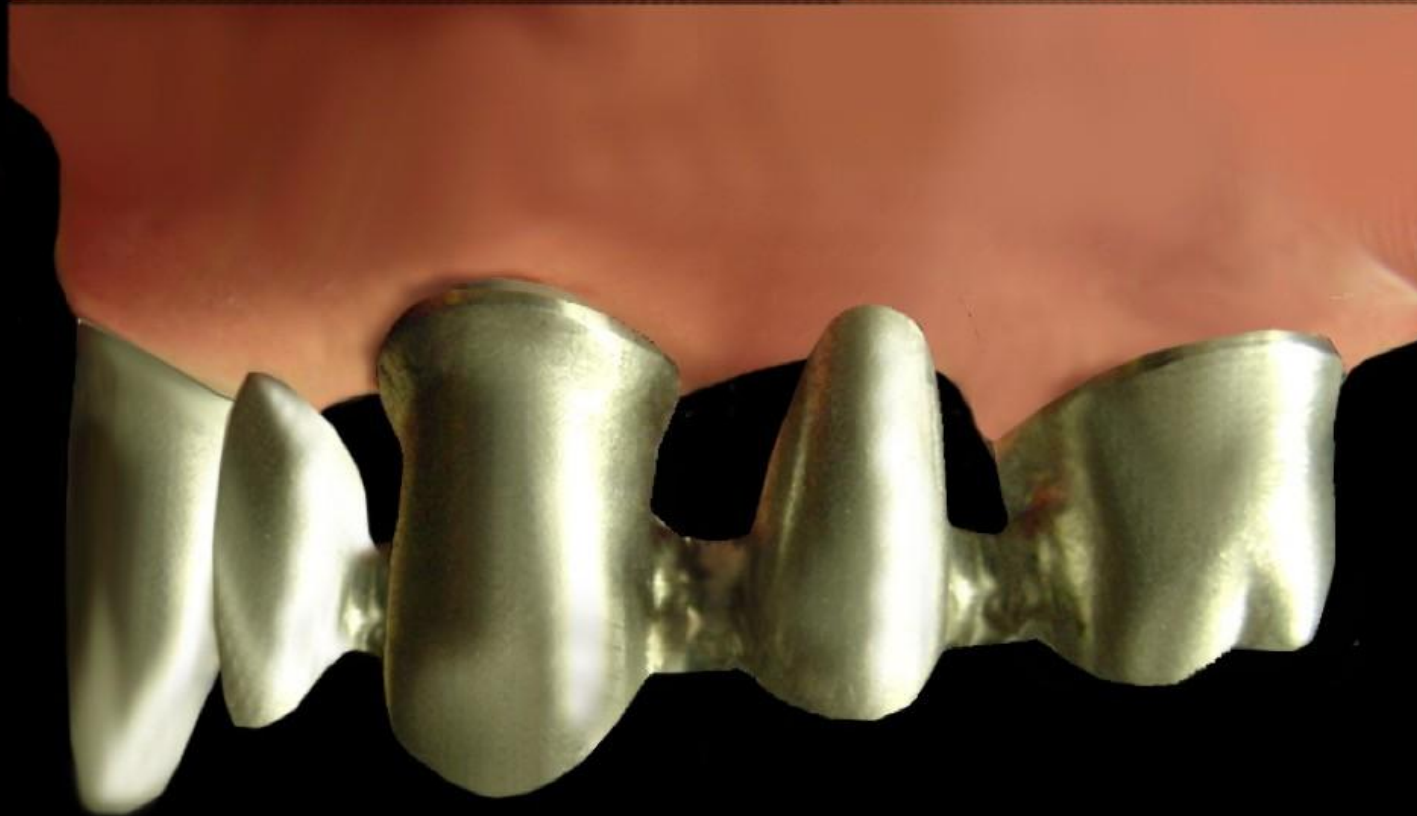Components



THE UNIVERSITY OF
**WESTERN
AUSTRALIA**



Oral Health Centre
of Western Australia



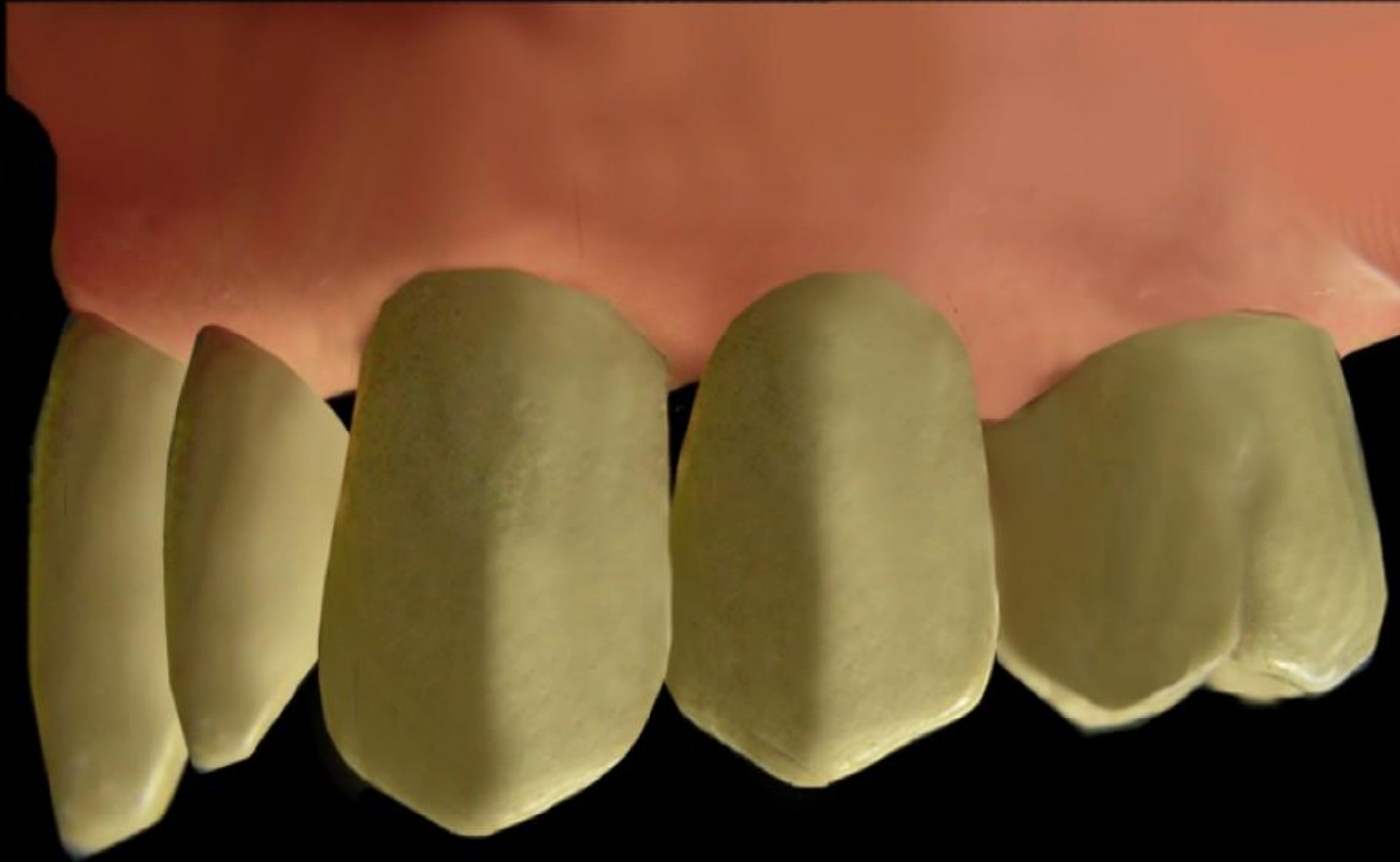
Components



THE UNIVERSITY OF
**WESTERN
AUSTRALIA**



Oral Health Centre
of Western Australia



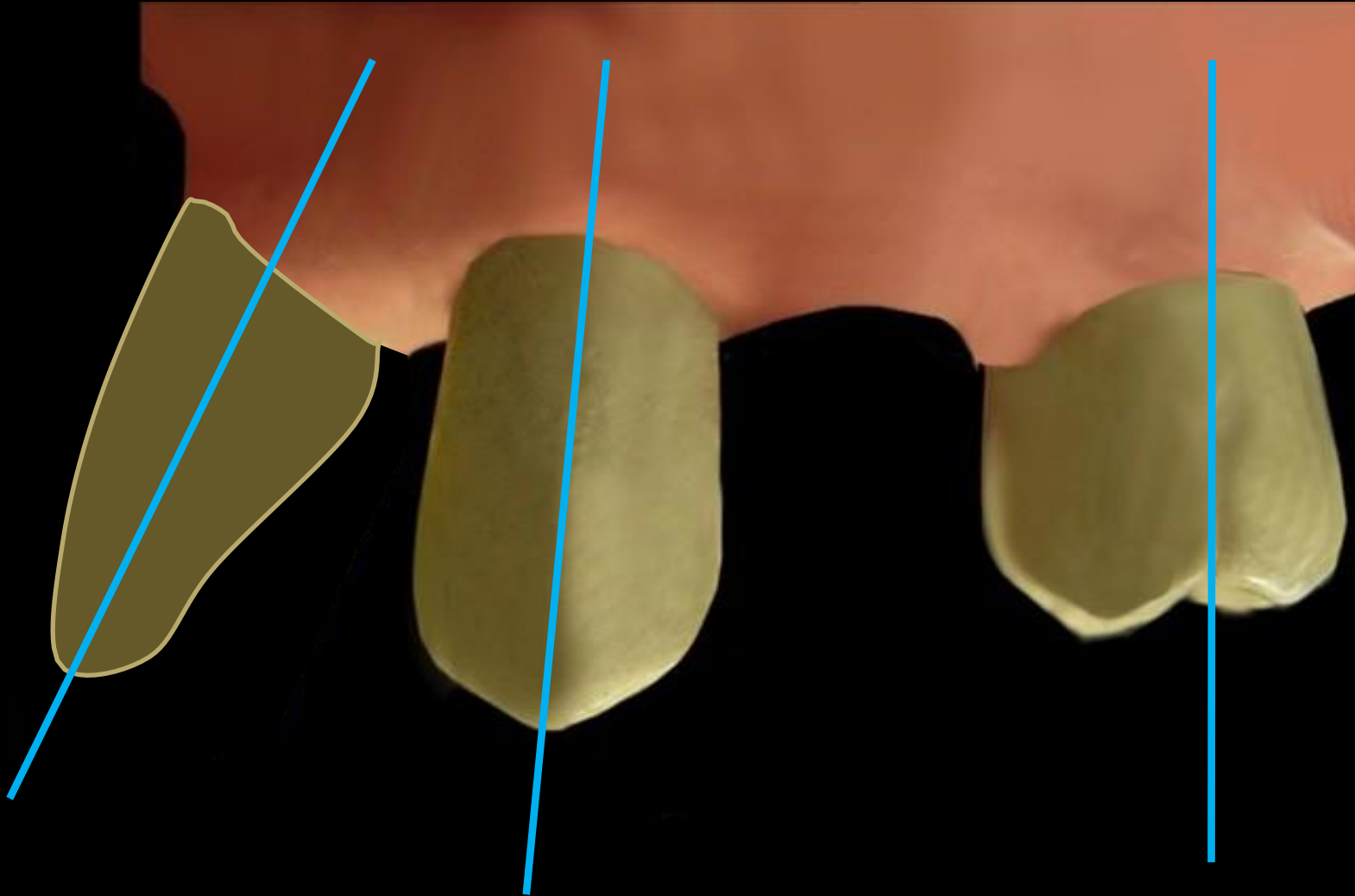
Components



THE UNIVERSITY OF
**WESTERN
AUSTRALIA**



Oral Health Centre
of Western Australia



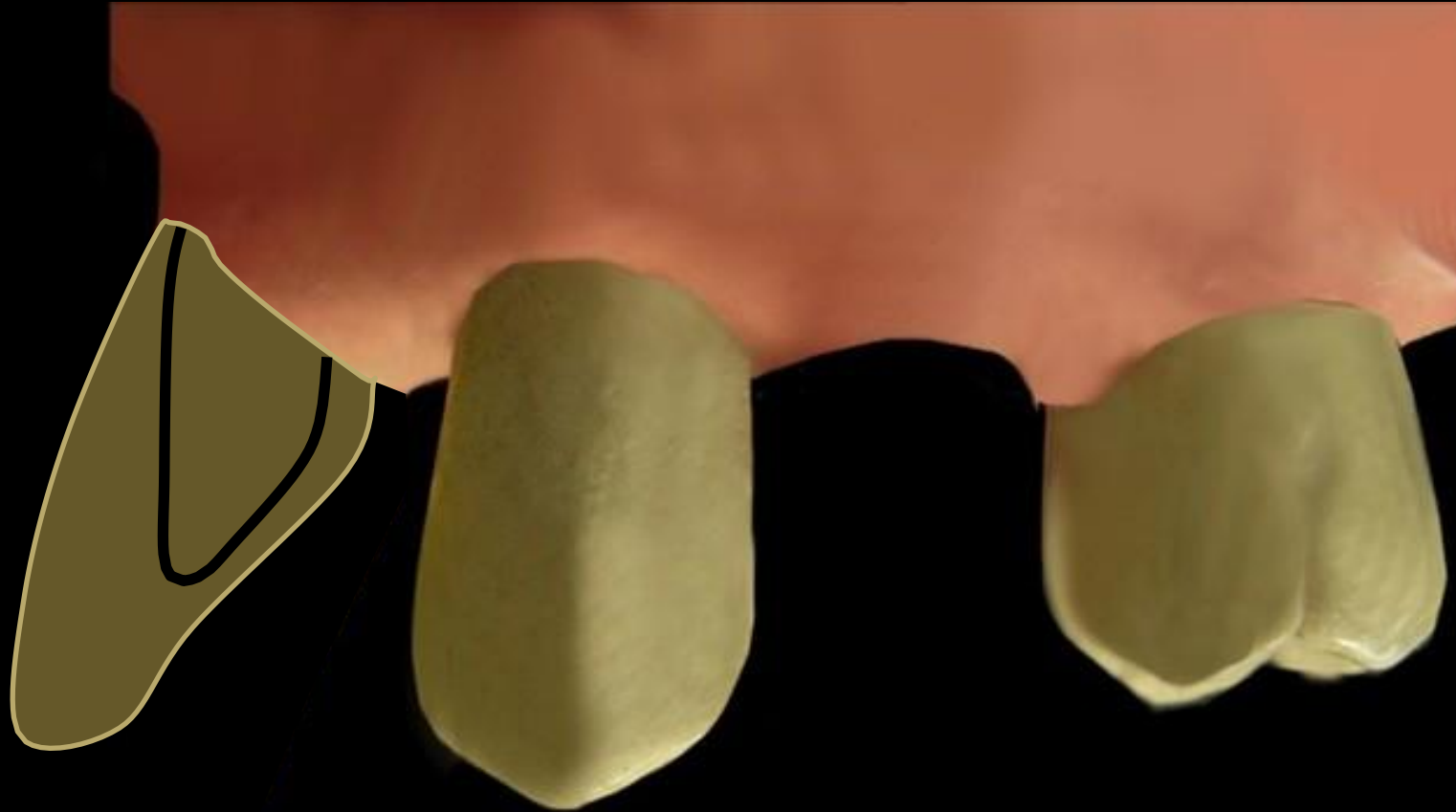
Components



THE UNIVERSITY OF
**WESTERN
AUSTRALIA**



Oral Health Centre
of Western Australia



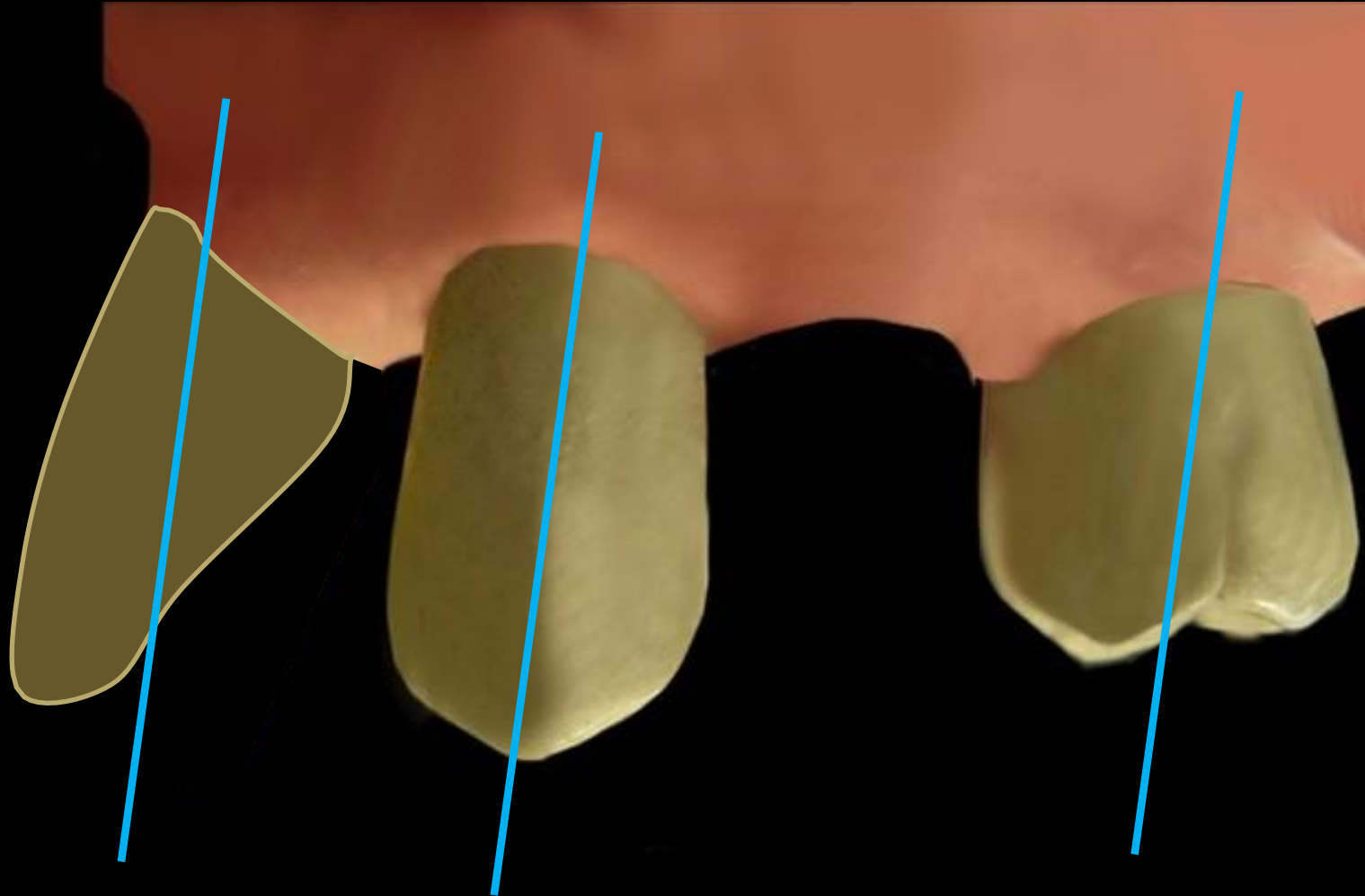
Components



THE UNIVERSITY OF
**WESTERN
AUSTRALIA**



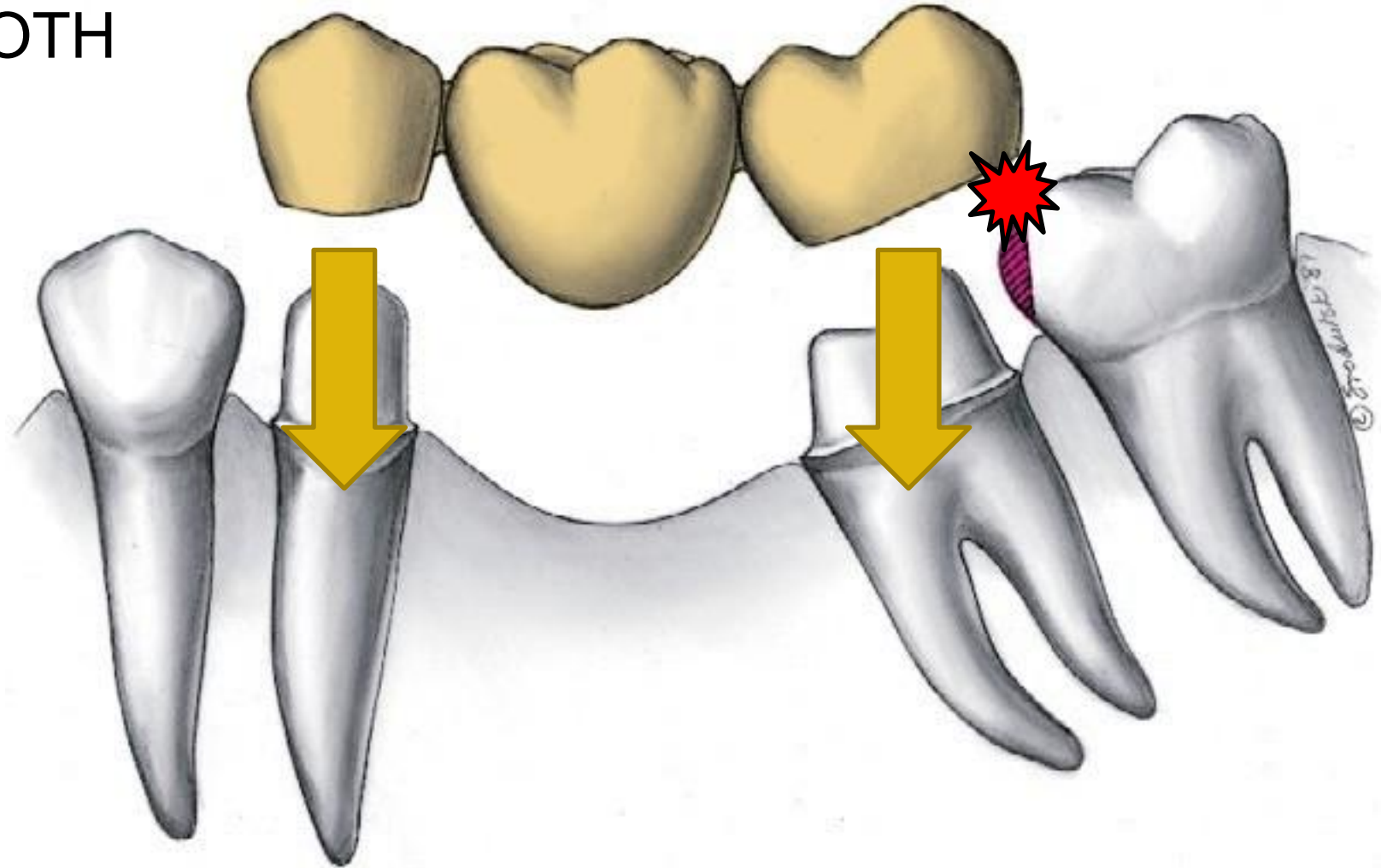
Oral Health Centre
of Western Australia



Components



ABUTMENT TOOTH



Components

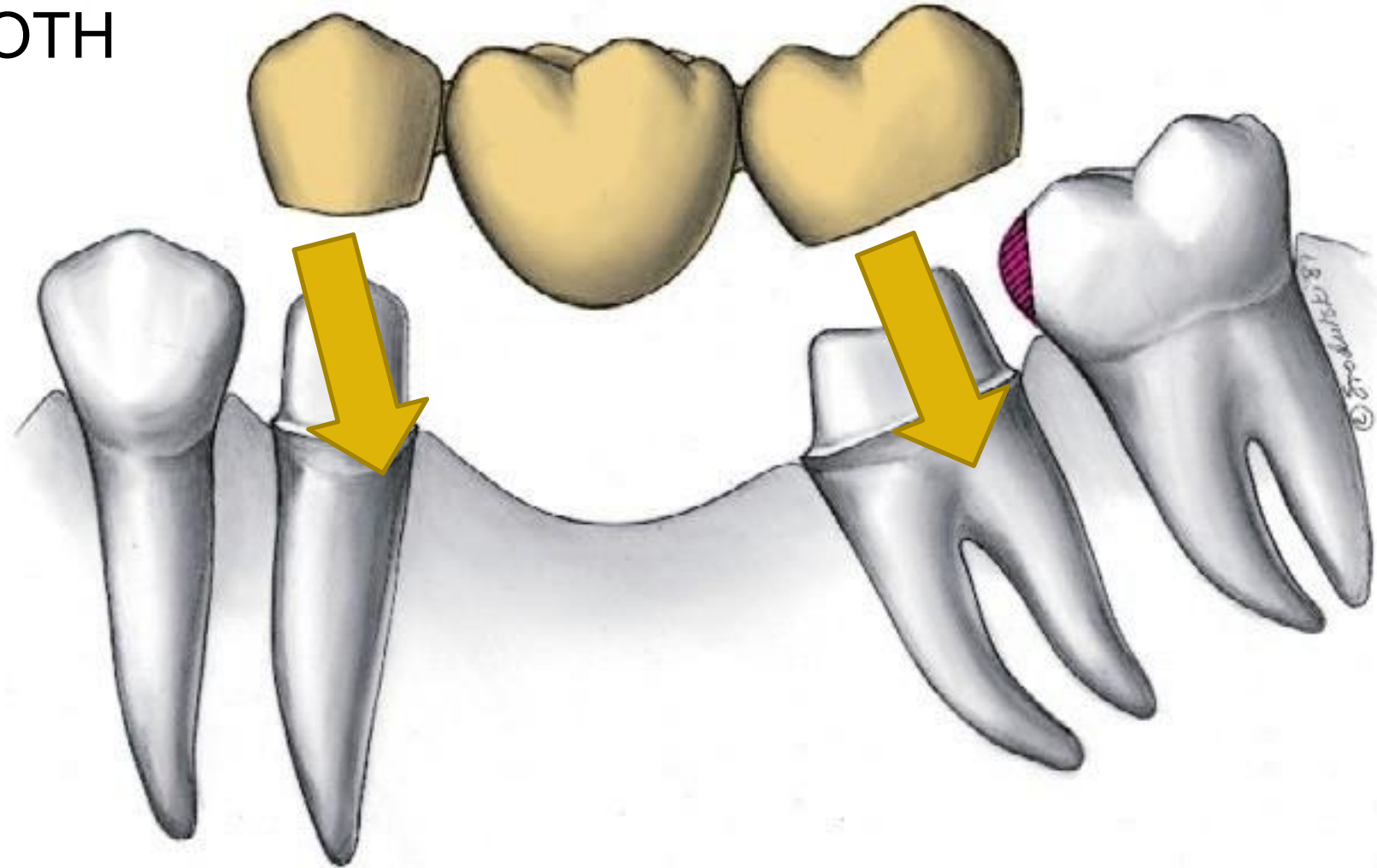


THE UNIVERSITY OF
**WESTERN
AUSTRALIA**



Oral Health Centre
of Western Australia

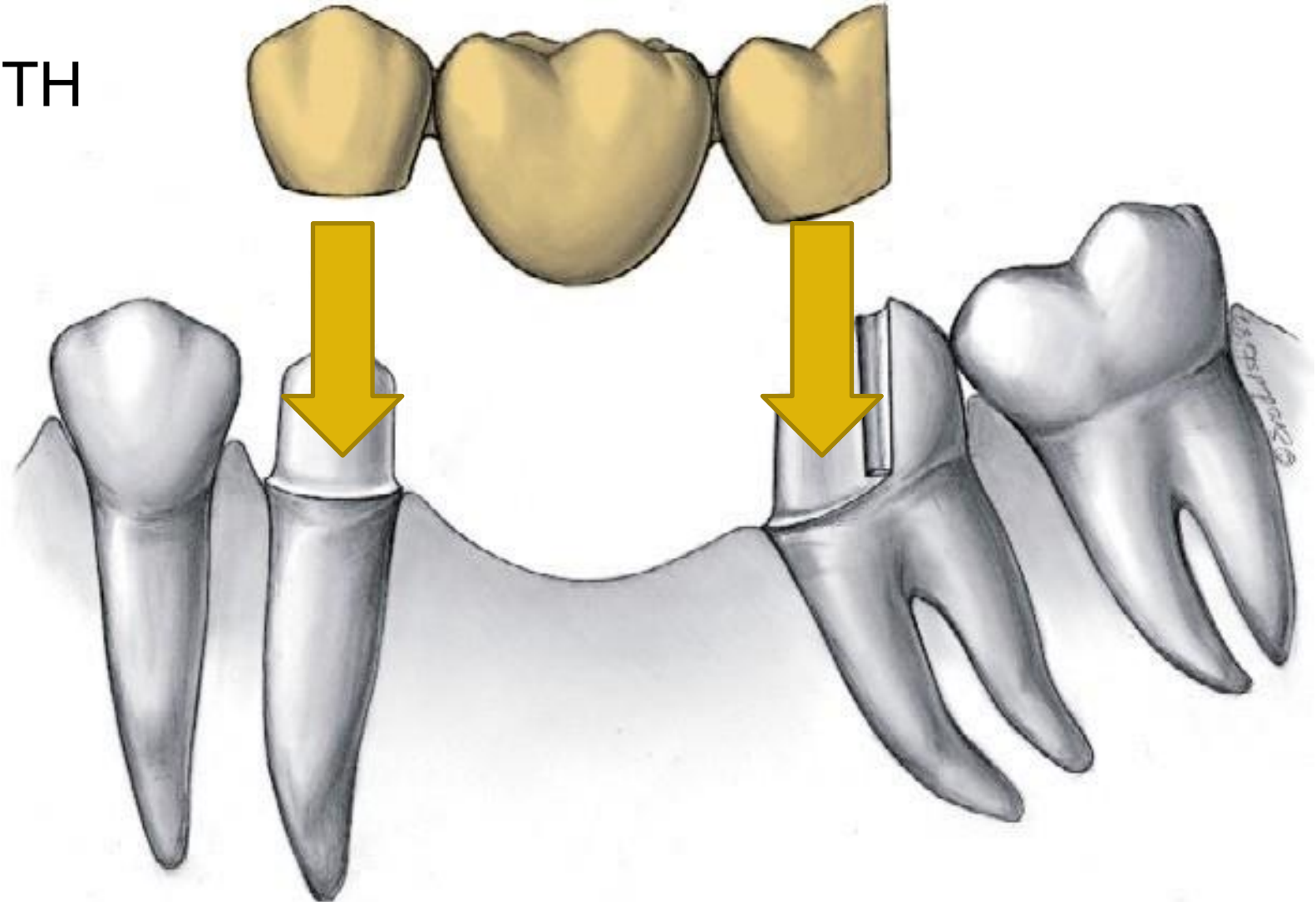
ABUTMENT TOOTH



Components



ABUTMENT TOOTH



Components

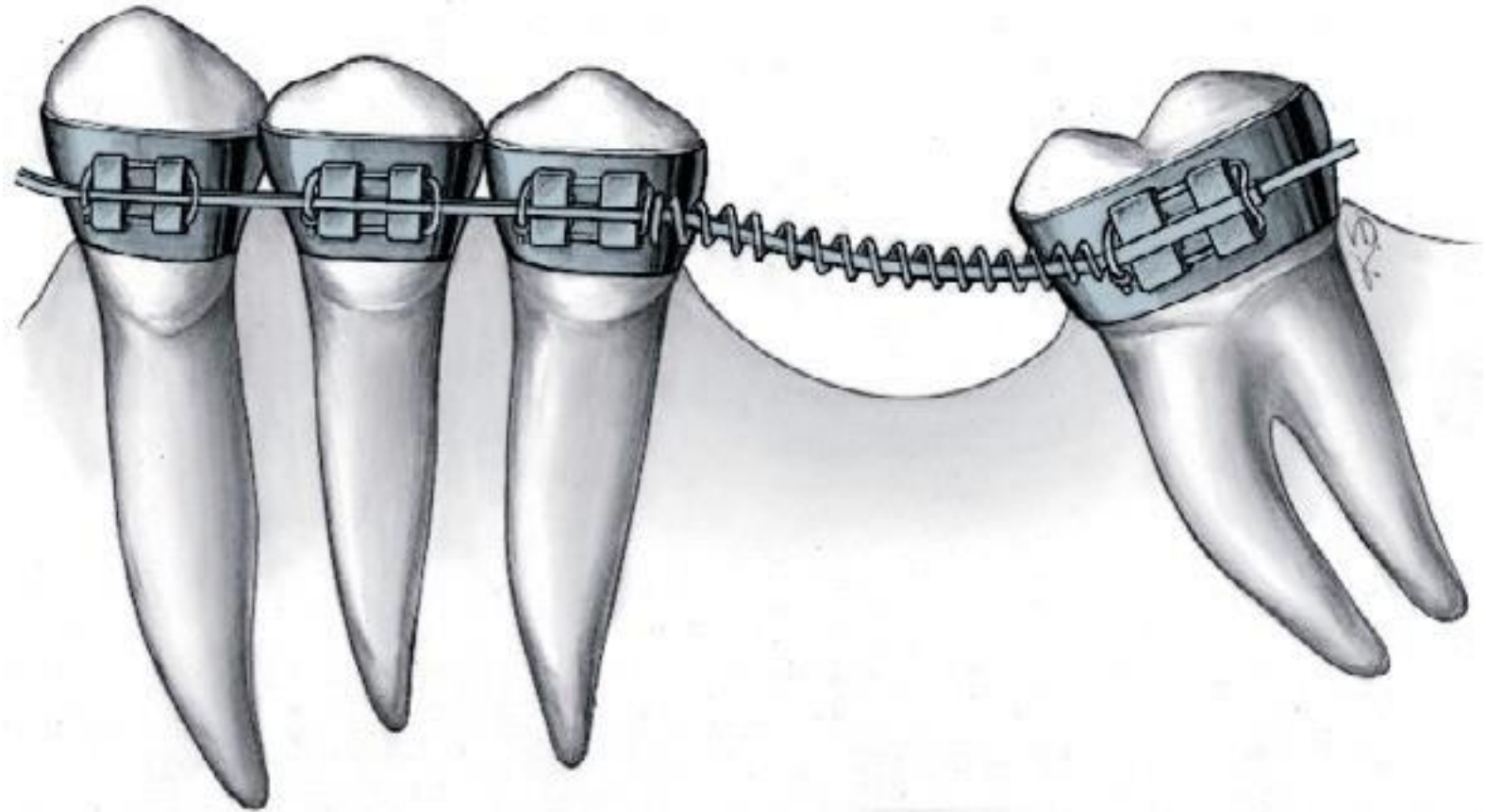


THE UNIVERSITY OF
**WESTERN
AUSTRALIA**



Oral Health Centre
of Western Australia

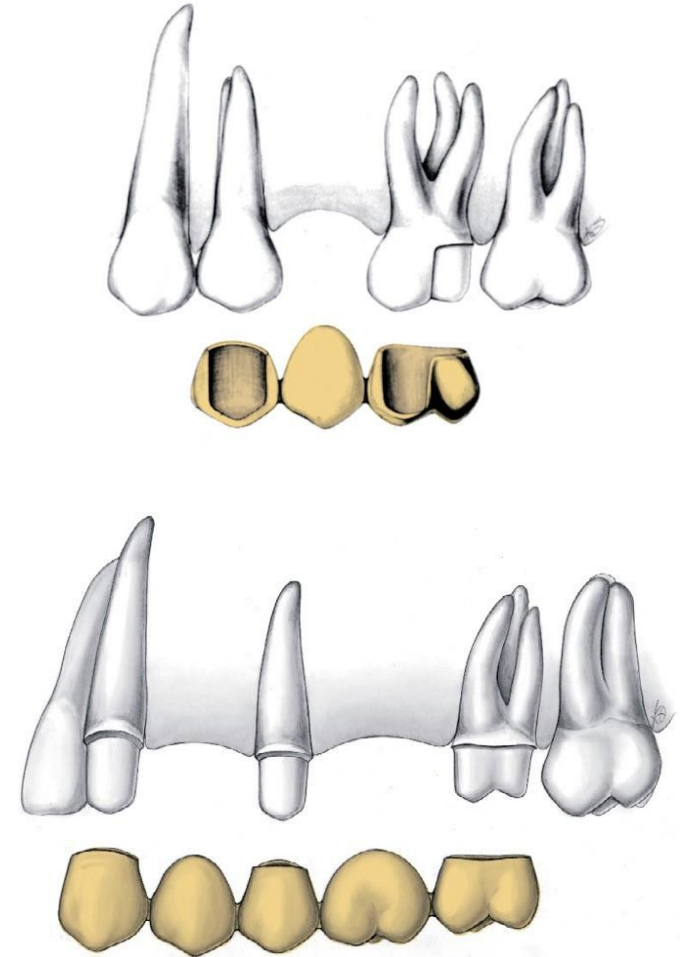
ABUTMENT TOOTH



RETAINERS

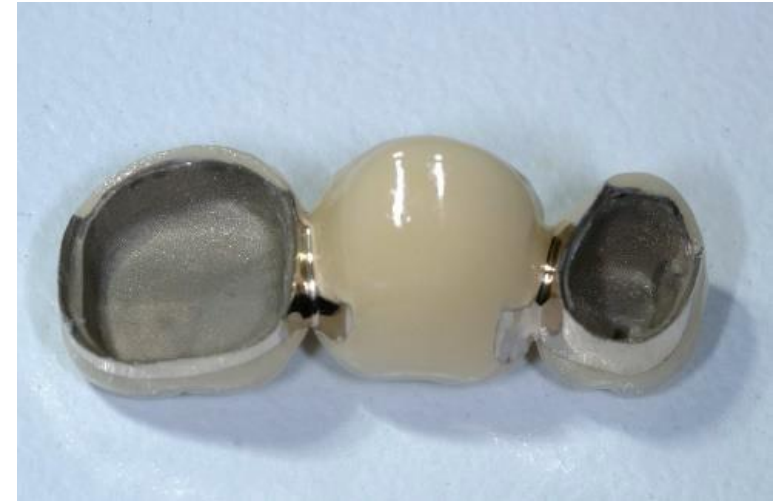- Full coverage restoration: All metal, PFM, All ceramic crowns
- Partial coverage restoration: 4/5, 7/8

Give stability and retention to the dental bridge



PONTICS

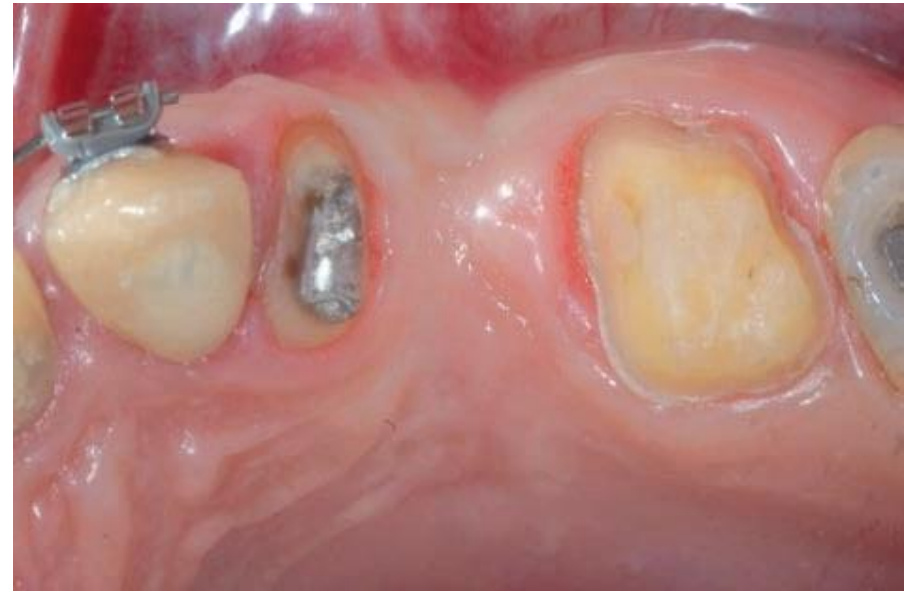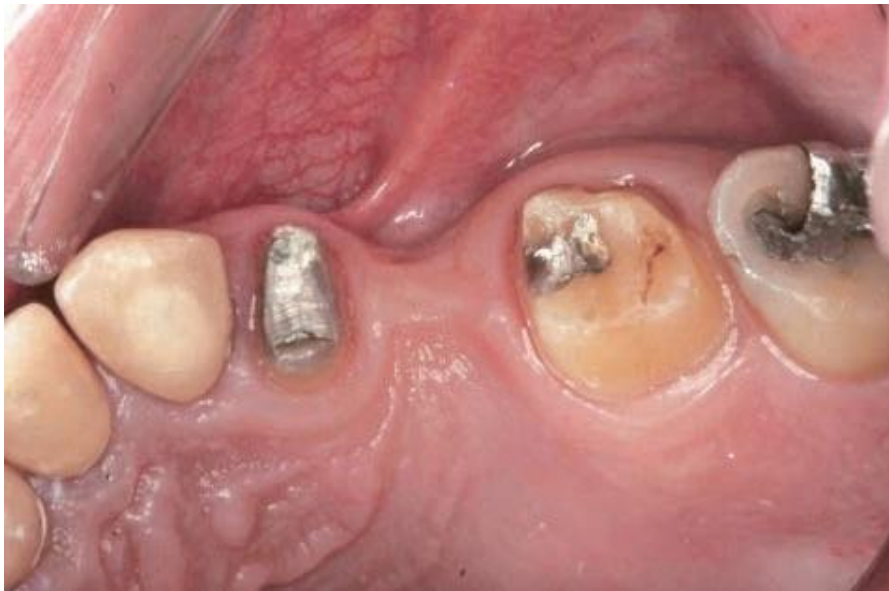- Artificial tooth that replaces a missing natural tooth
- Suspended: tooth supported
- Restore aesthetic and function
- Prevent tilting and drifting of adjacent teeth and super-eruption of opposing teeth



PONTICS

Design parameters of pontics involve:

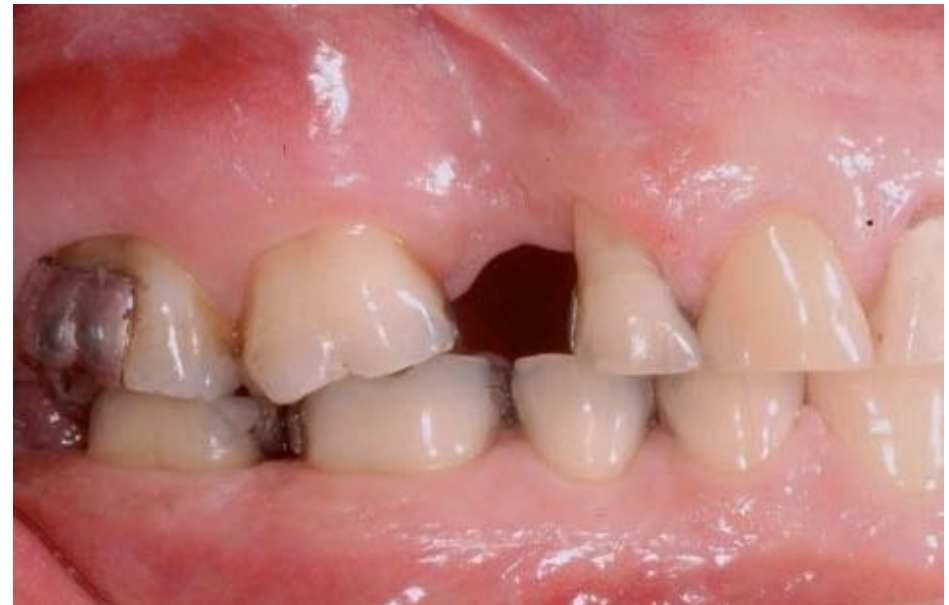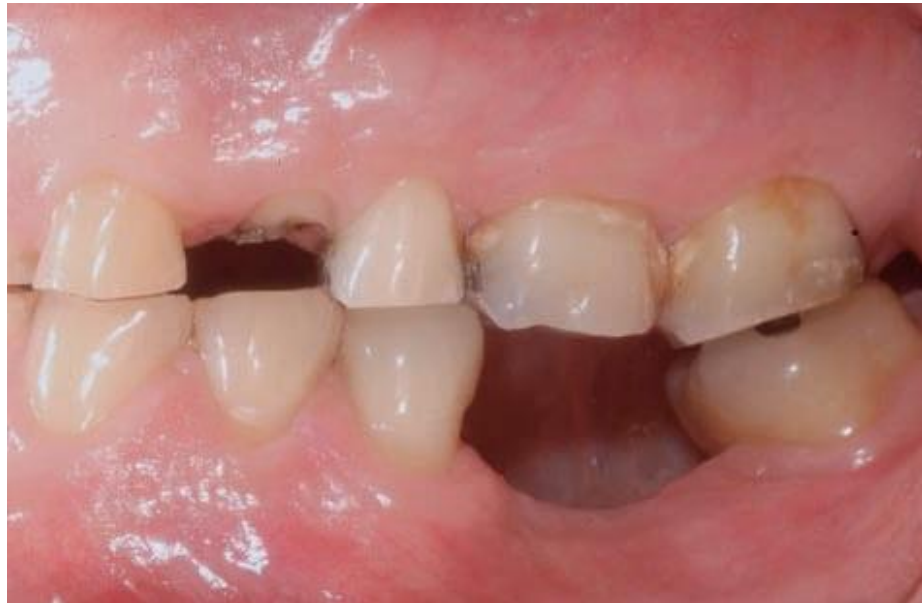- Height and width of the residual ridge



PONTICS

Design parameters of pontics involve:

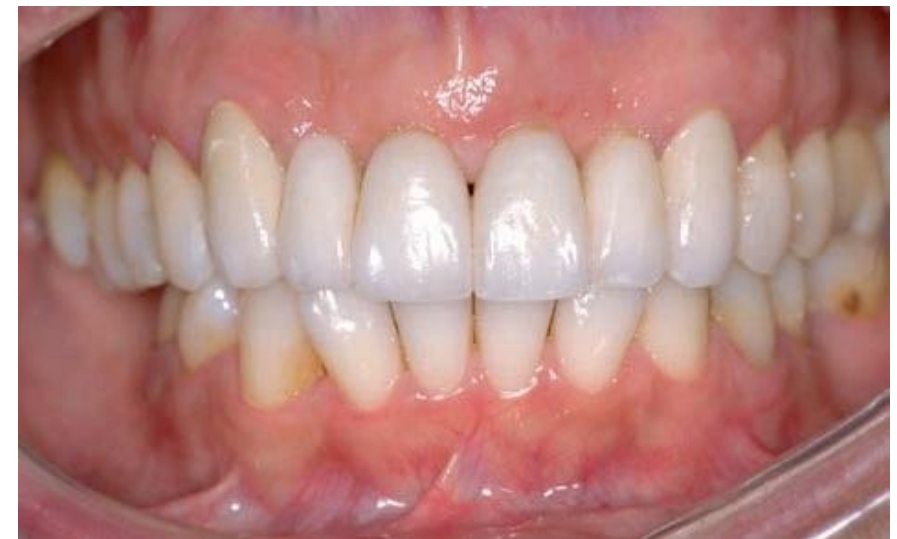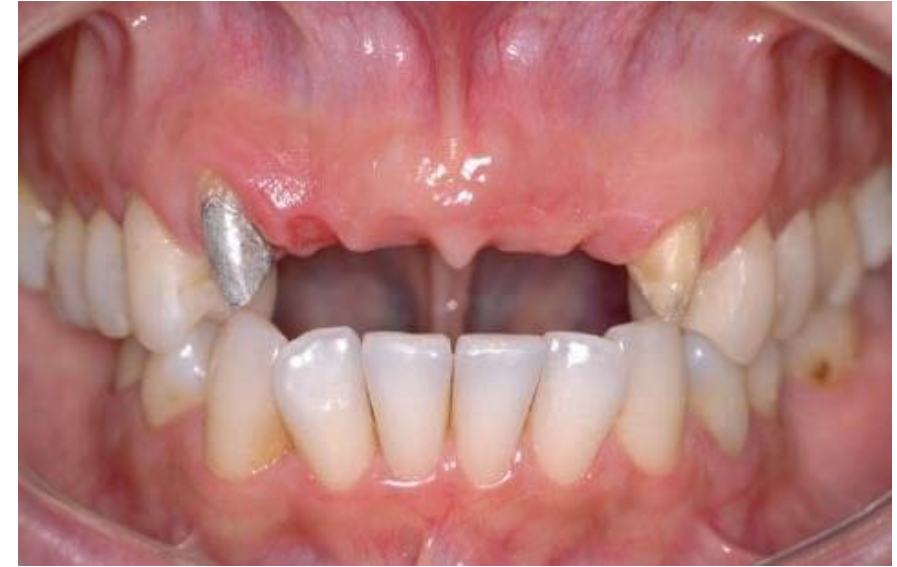- Height and width of the residual ridge
- Dimensions of the edentulous space



PONTICS

Design parameters of pontics involve:

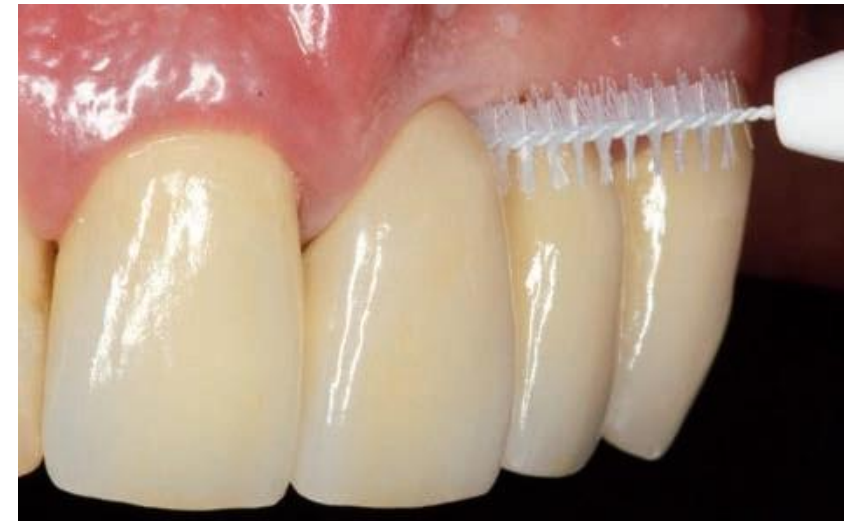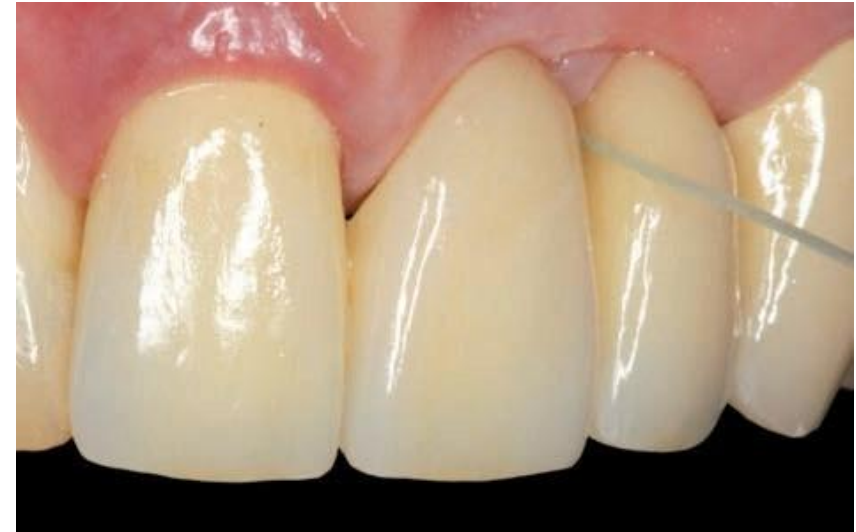- Height and width of the residual ridge
- Dimensions of the edentate space
- Shape and texture of the soft tissues
- Comfort and support the adjacent tissues
- Aesthetic requirements



PONTICS

Design parameters of pontics involve:

- Height and width of the residual ridge
- Dimensions of the edentate space
- Shape and texture of the soft tissues
- Comfort and support the adjacent tissues
- Aesthetic requirements
- Access for oral hygiene



Components

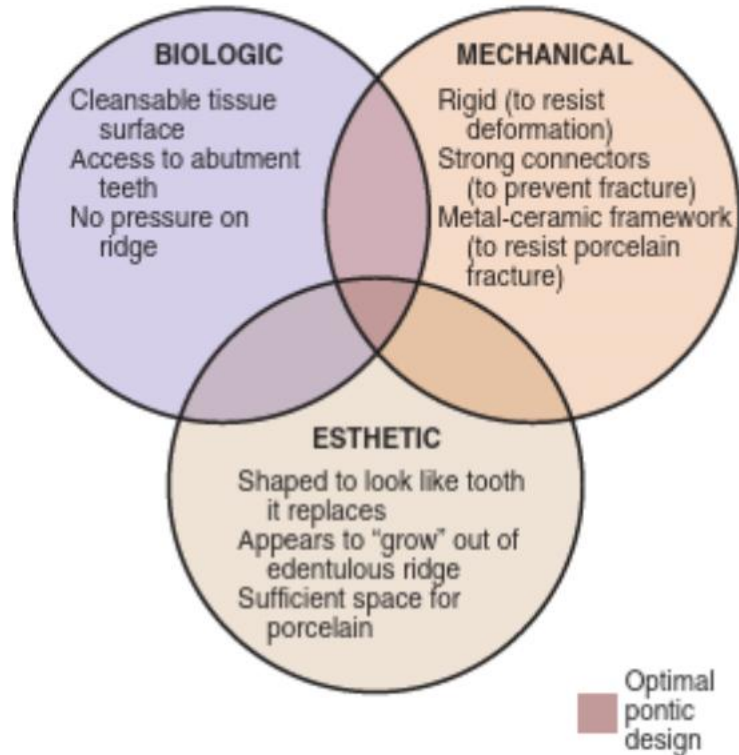


FIGURE 20-2 ■ Biologic, mechanical, and esthetic considerations for successful pontic design.

BOX 20-1

Pontic Design Classification

MUCOSAL CONTACT

Ridge-lap
Modified ridge-lap
Ovate
Conical

NO MUCOSAL CONTACT

Sanitary (hygienic)
Modified sanitary (hygienic)

PONTICS

Classification:

1) SADDLE / RIDGE LAP

- Concave tissue surface
- Overlap the residual ridge bucco-lingually
- Contraindicated under all circumstances

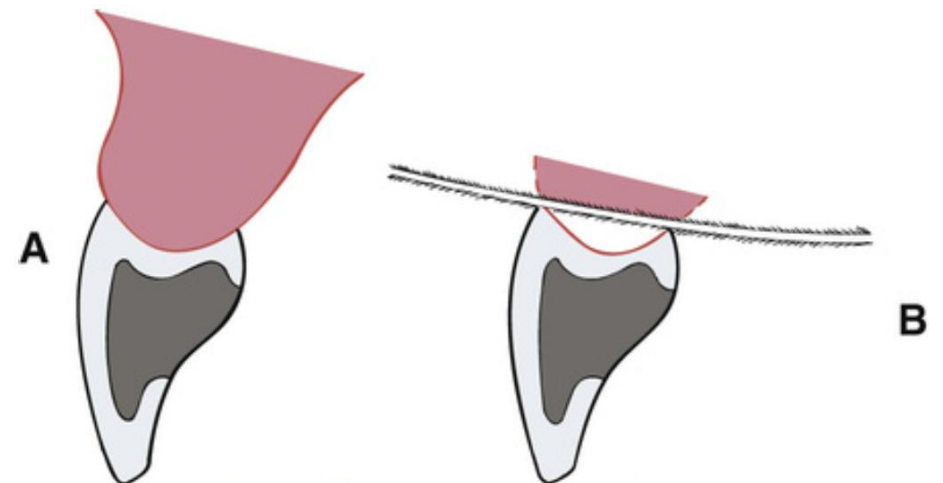
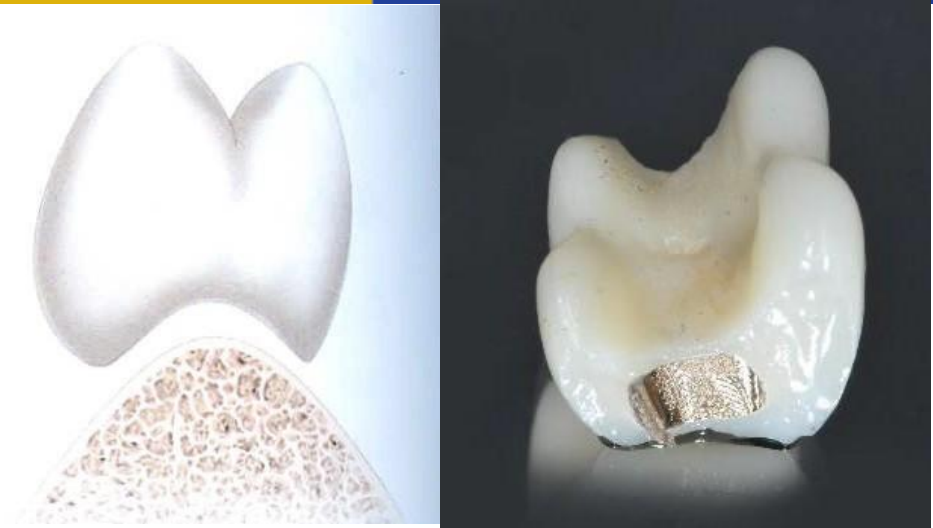

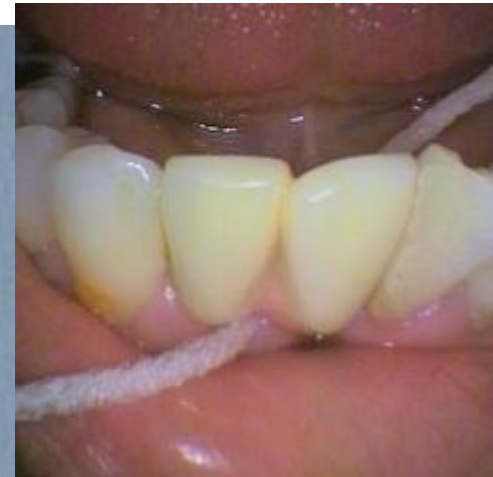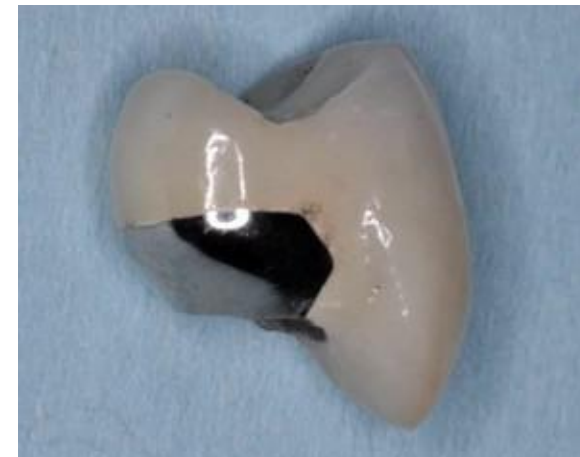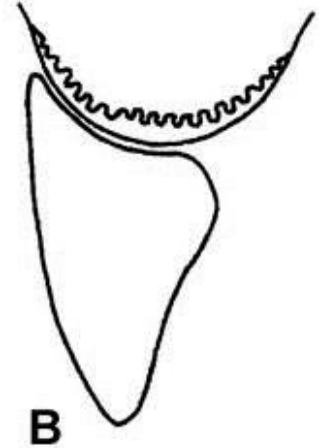
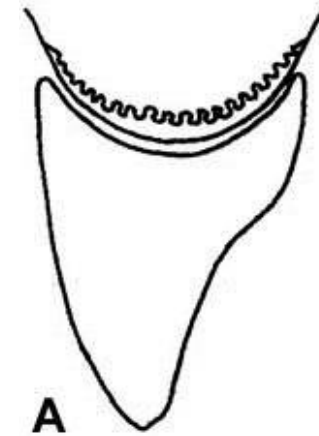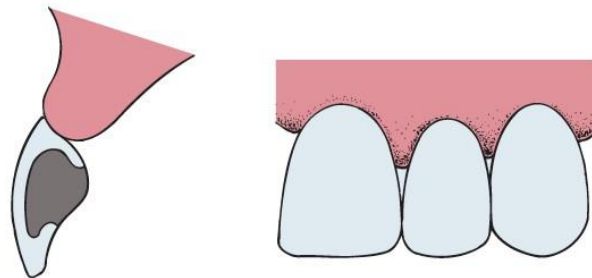
FIGURE 20-14 A, Cross-sectional view of ridge-lap pontic. B, The tissue surface is inaccessible to cleaning devices.

PONTICS

Classification:

2) MODIFIED RIDGE LAP

- Lingual modification to open cervical embrasures and facilitate the hygiene
- Gentle concavity linguo-facially but is always convex mesio-distally.
- Ideally suitable for "convex" gingiva profile with no concavities
- High aesthetic

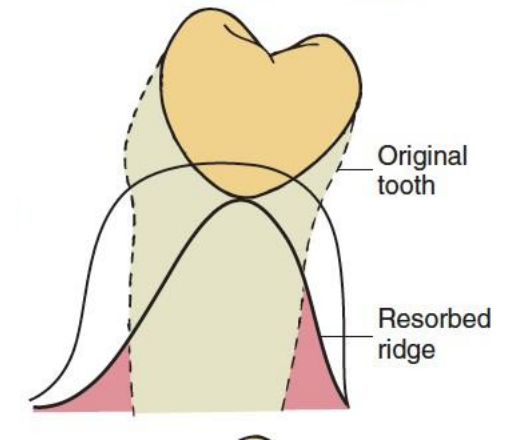
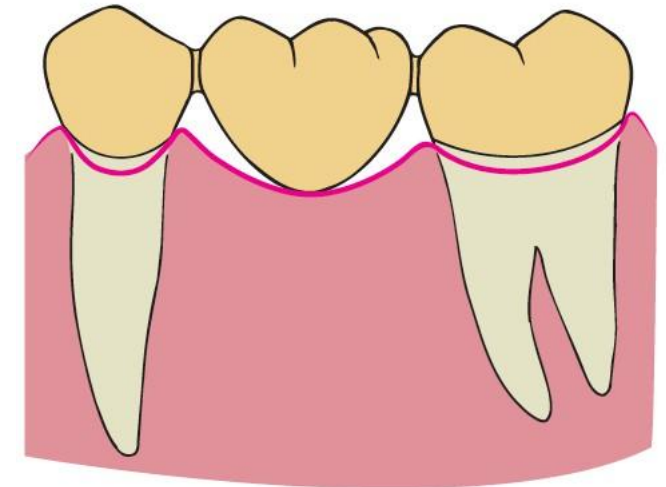
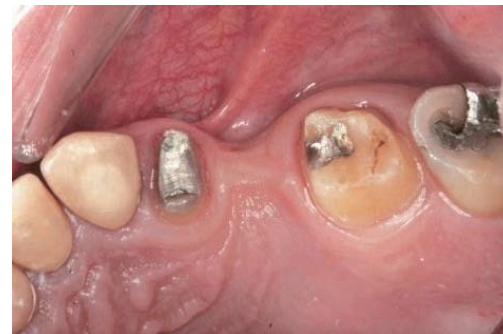

PONTICS

Classification:

3) CONICAL

- Bullet-shape, egg-shape
- Convex with only one point of contact with residual ridge
- Posterior region
- Not as suitable for broad residual ridges due to food trapping



PONTICS

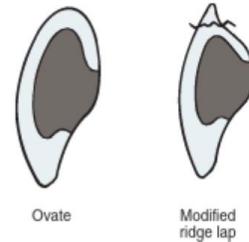
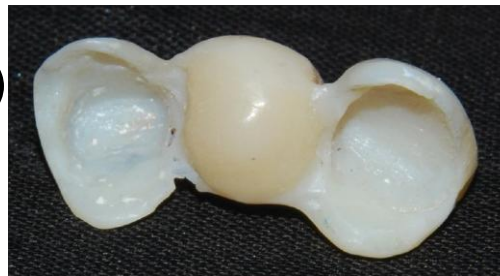
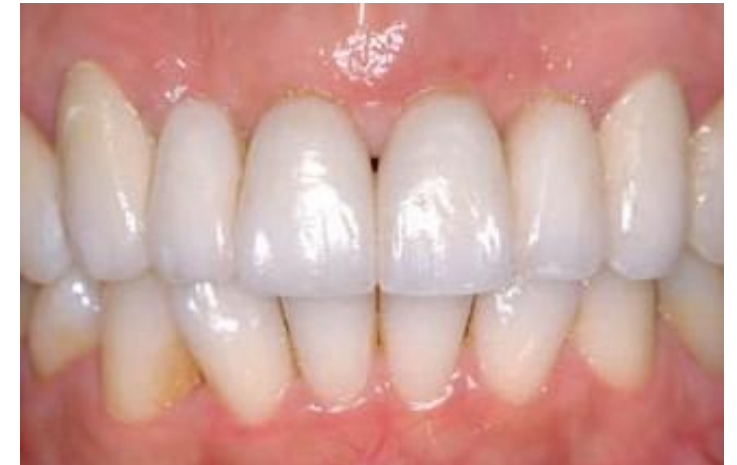
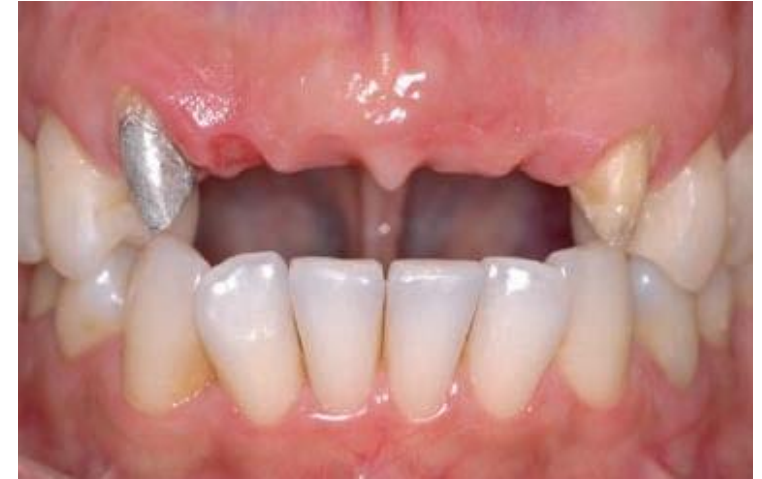FIGURE 20-22 ■ The ovate pontic design eliminates the potential for unsupported porcelain in the cervical portion of an anterior pontic.

Classification:

4) Ovate / Spheroidal

- Best aesthetic, appears to be emerging from the ridge
- Relative ease of hygiene (large tissue contact area)
- Convex tissue surface buccal-lingual and mesio-distal directions
- May need surgical augmentation (Costly)
- Strong pontic design (supported ceramic)

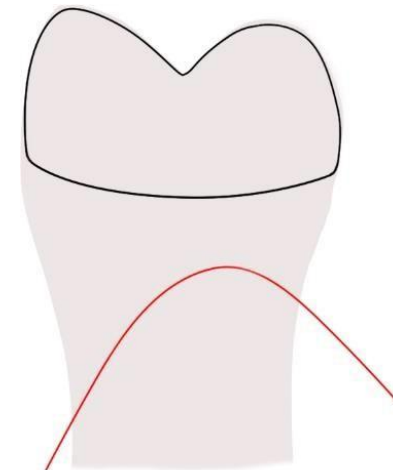
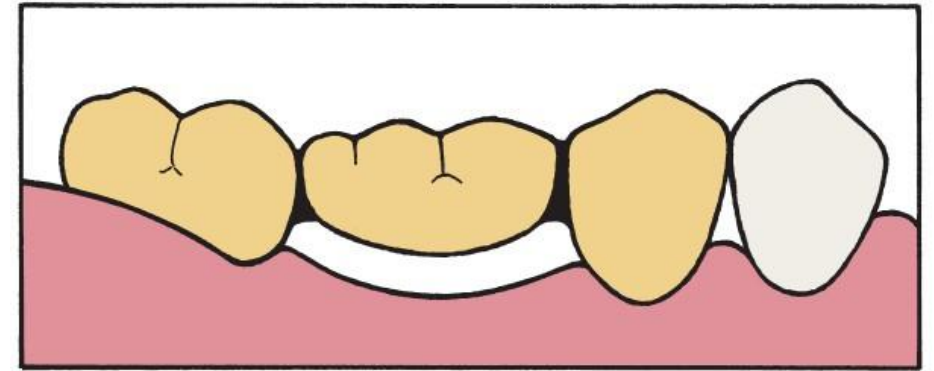


PONTICS

Classification:

5) Sanitary / Hygienic

- 2-3 mm clearance off the ridge
- Easy cleaning
- Posterior regions
- Disadvantages: poor aesthetic, entrapment of food, sharp line angle

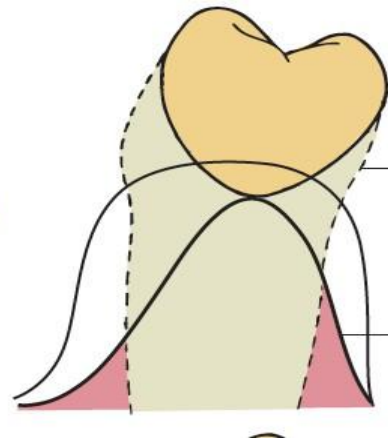
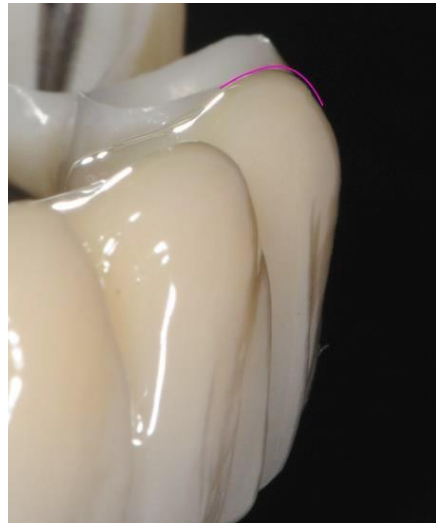
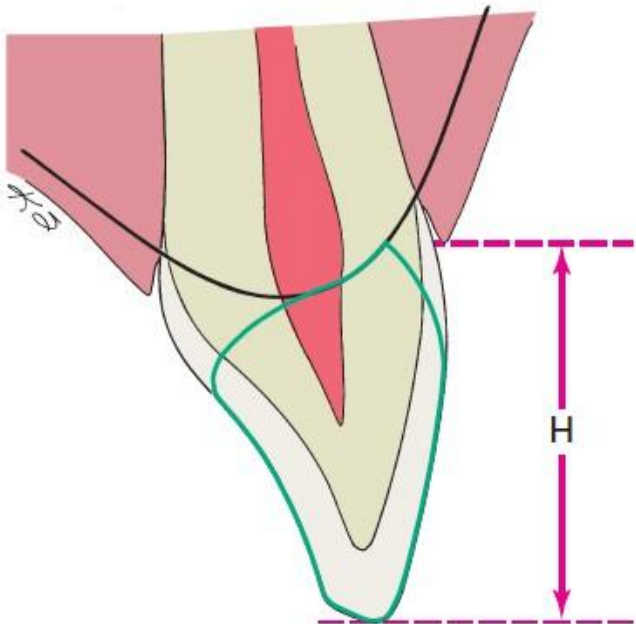


Interproximal view

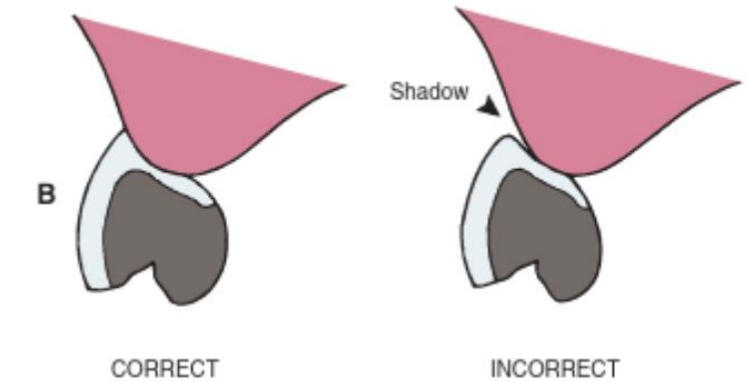
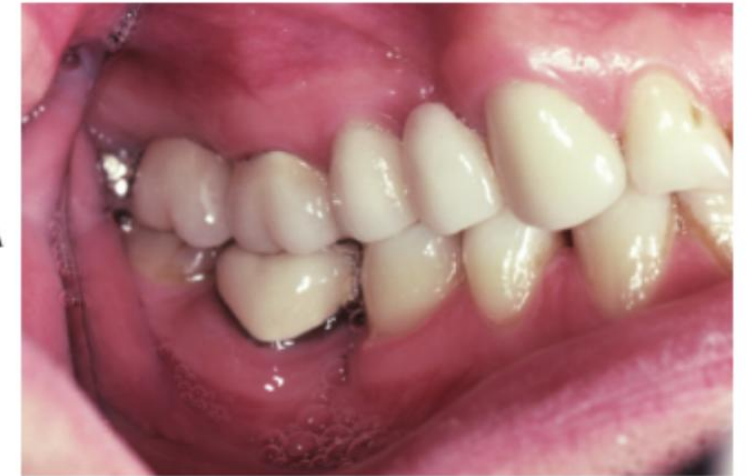PONTICS

Aesthetic considerations

- Modified Ridge Lap and Ovate pontics



Rounded facial line angle creates a shadow effect

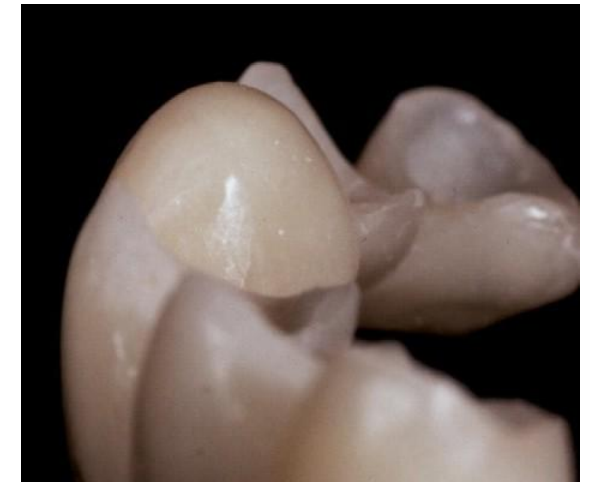
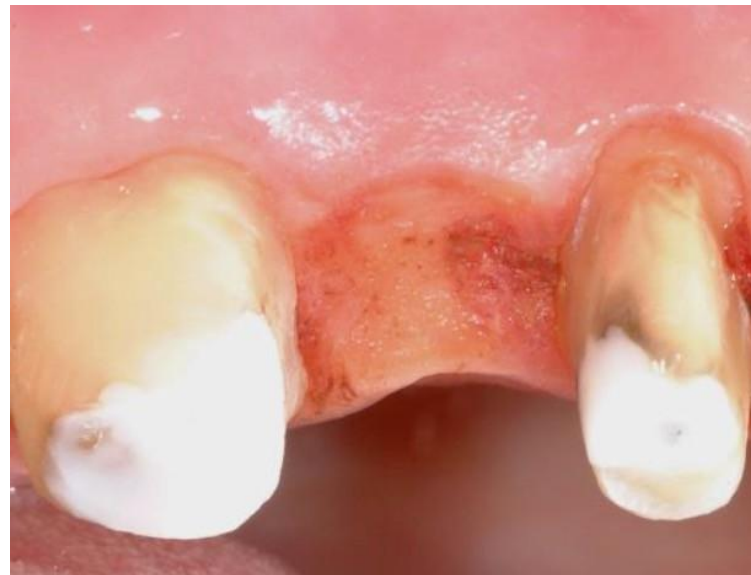
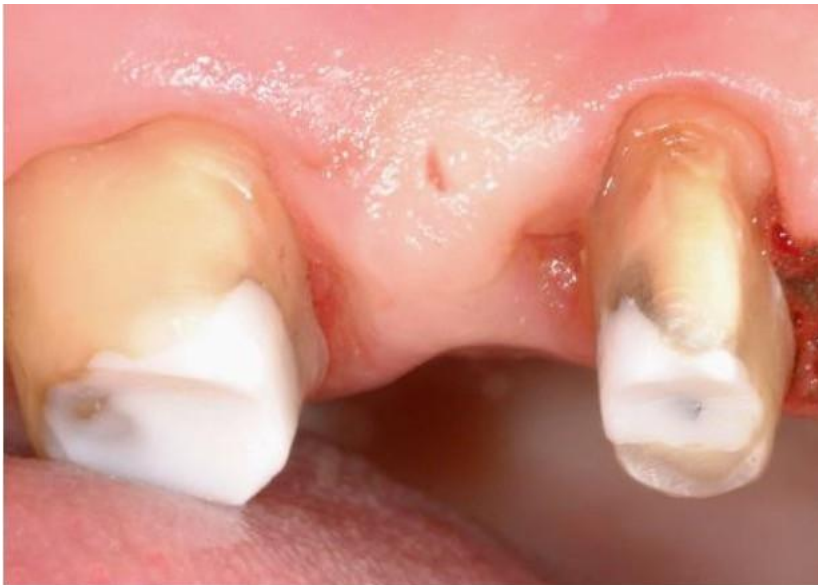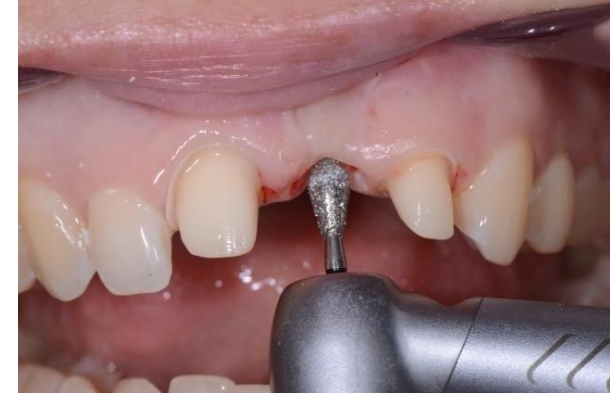PONTICS

Aesthetic considerations

- Modified Ridge Lap and Ovate pontics

Soft tissue management



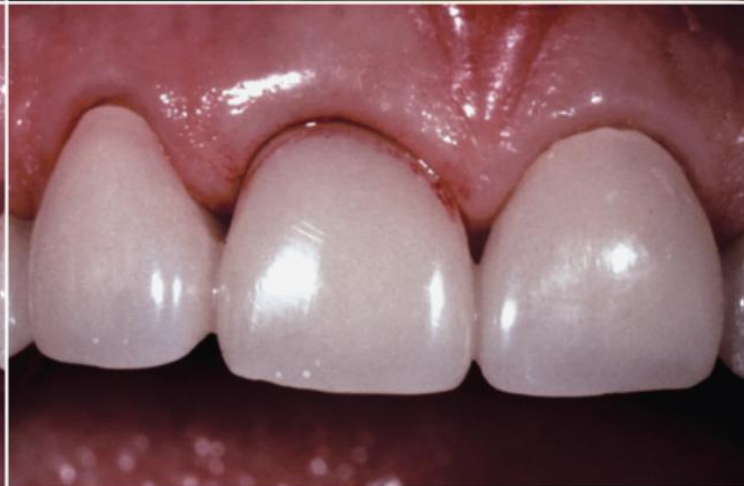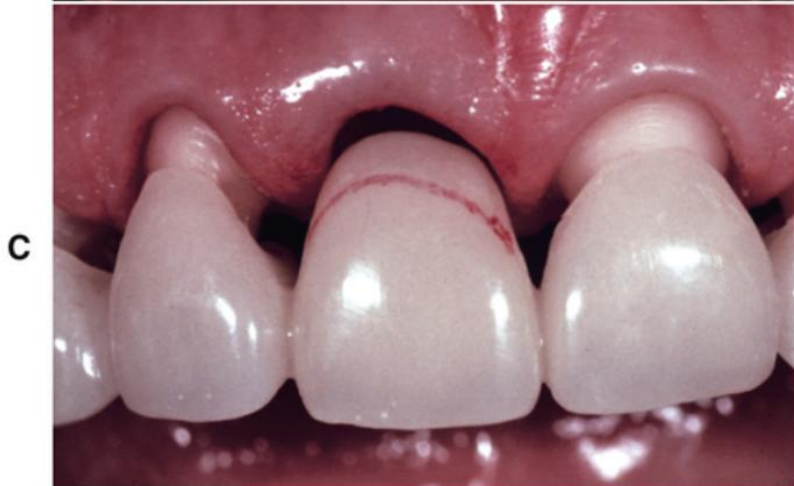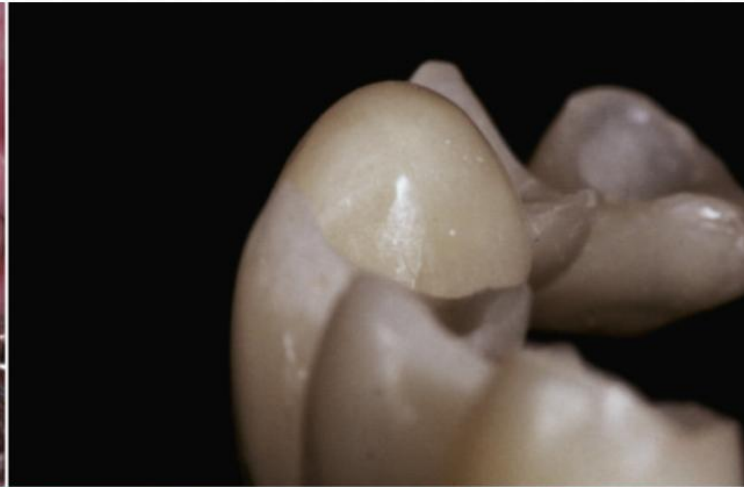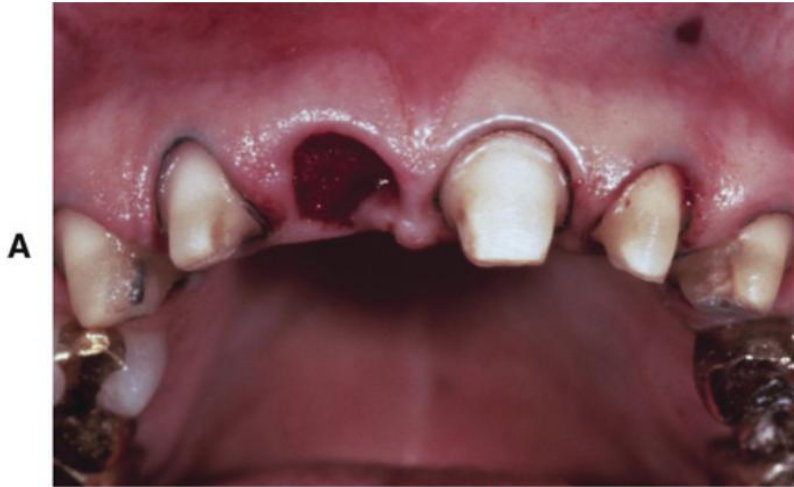Components



THE UNIVERSITY OF
**WESTERN
AUSTRALIA**



Oral Health Centre
of Western Australia



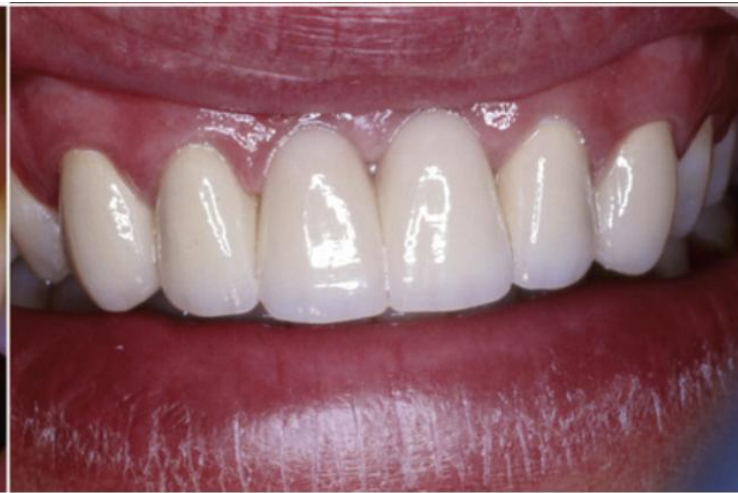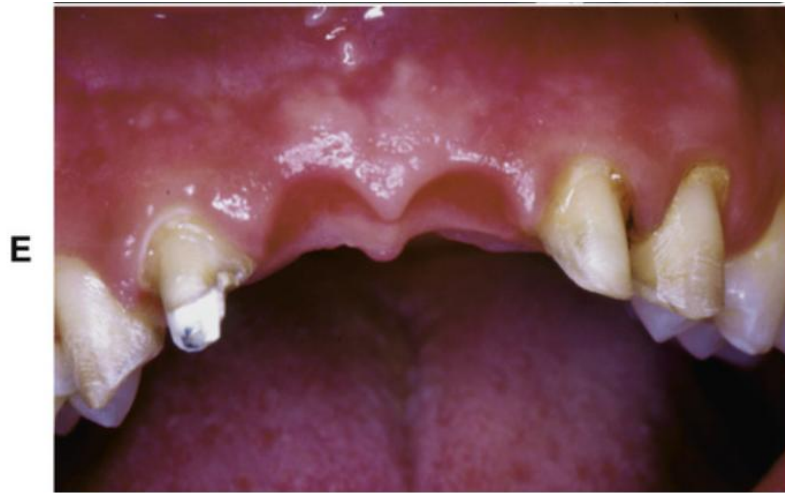Components



THE UNIVERSITY OF
**WESTERN
AUSTRALIA**



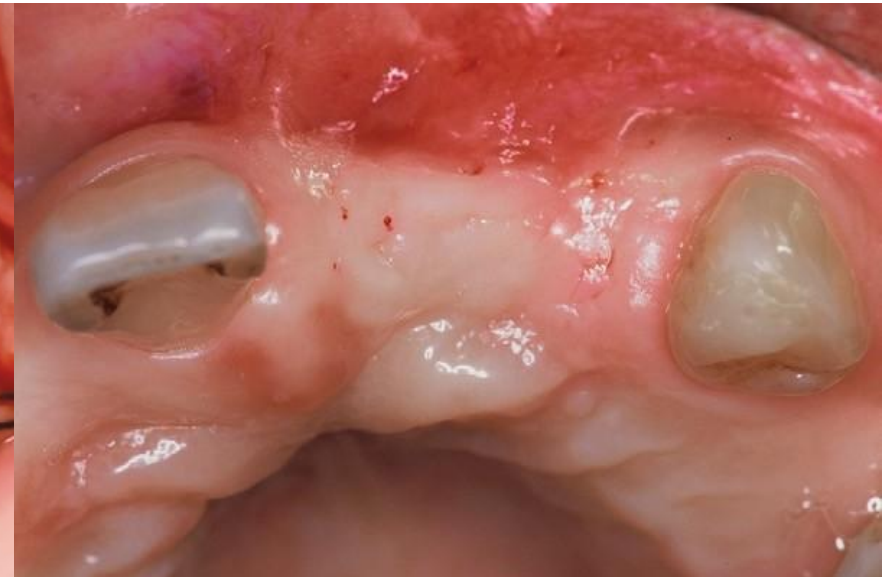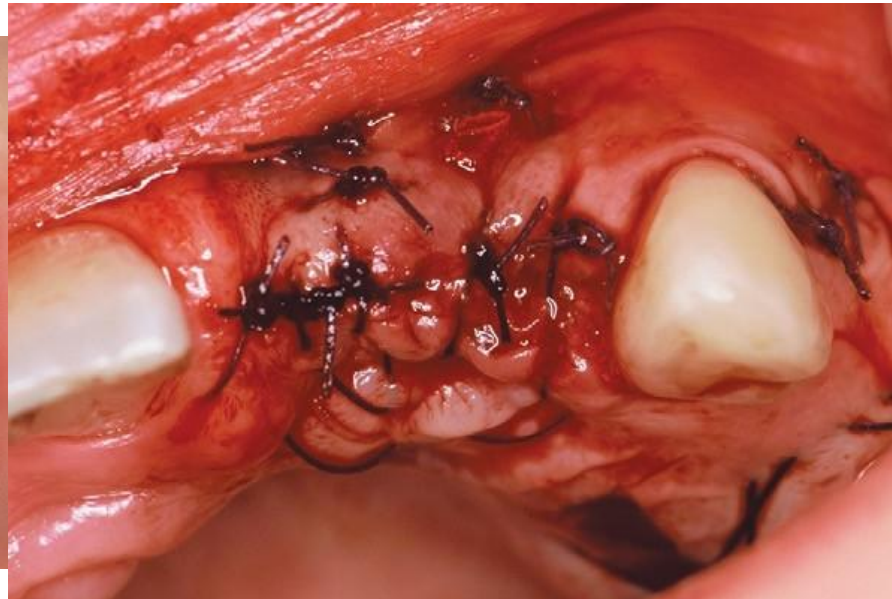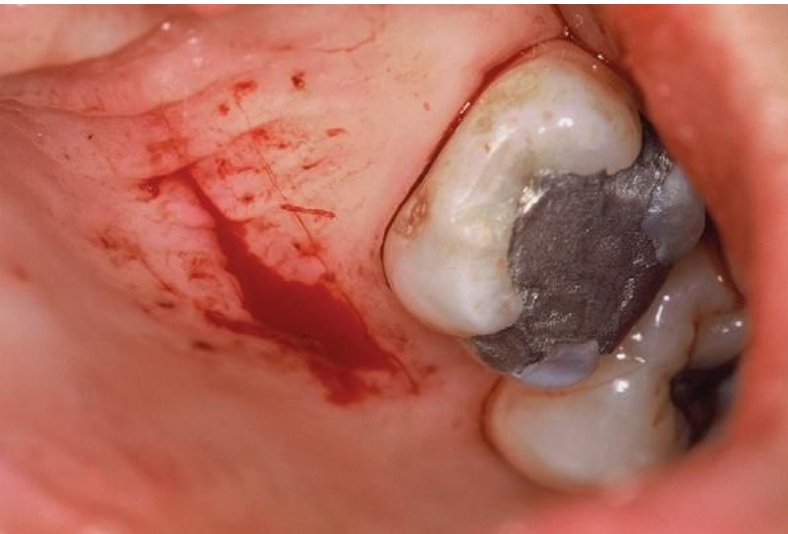Oral Health Centre
of Western Australia



PONTICS

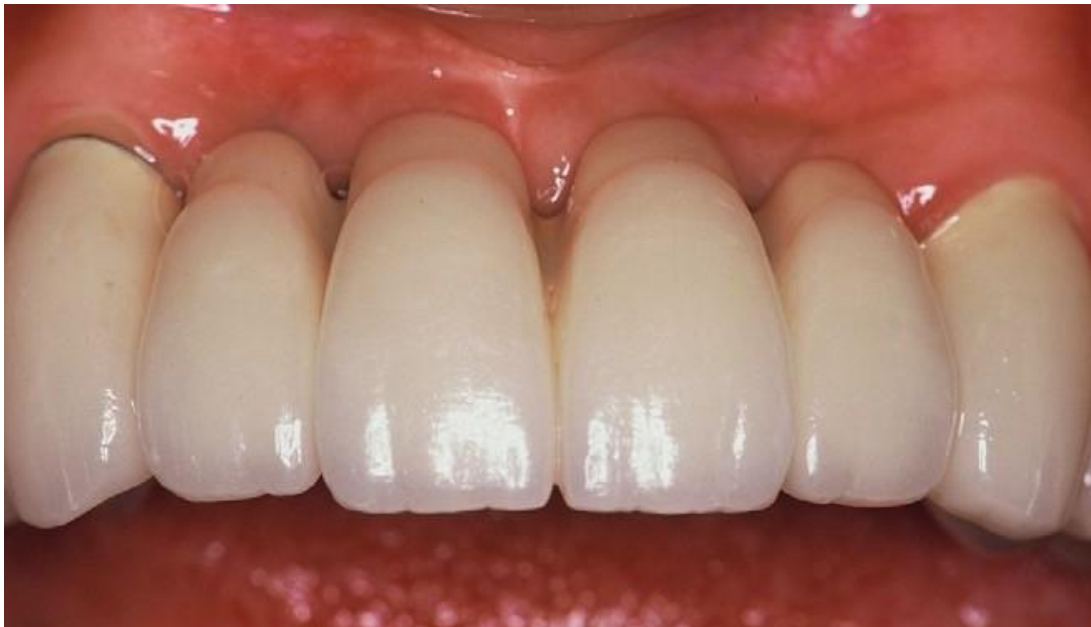Aesthetic considerations

- Soft tissue ridge augmentation

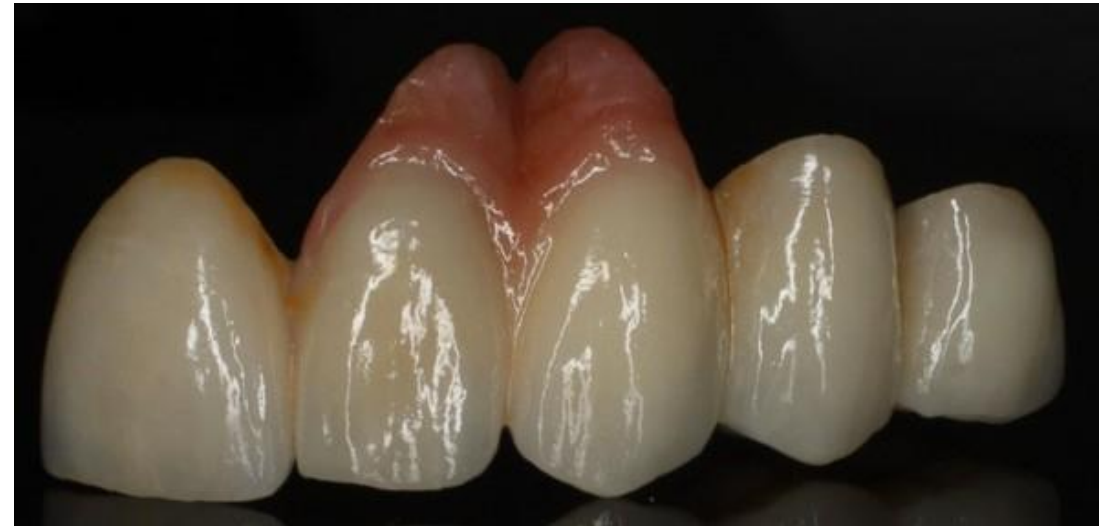

PONTICS

Aesthetic considerations



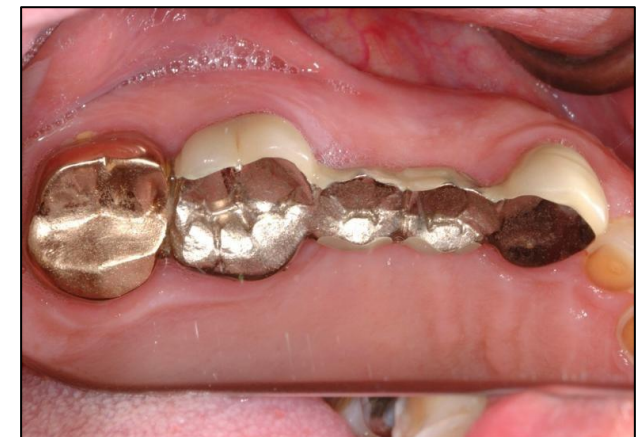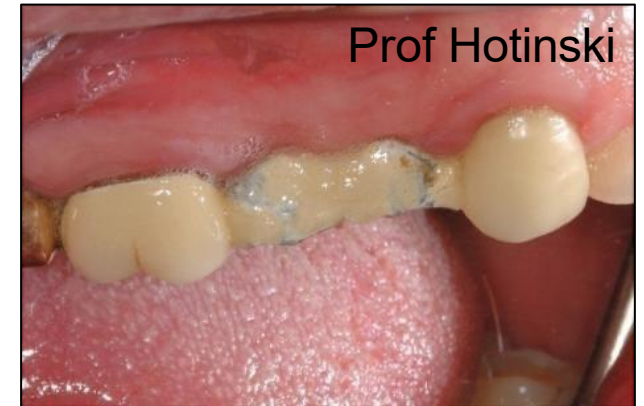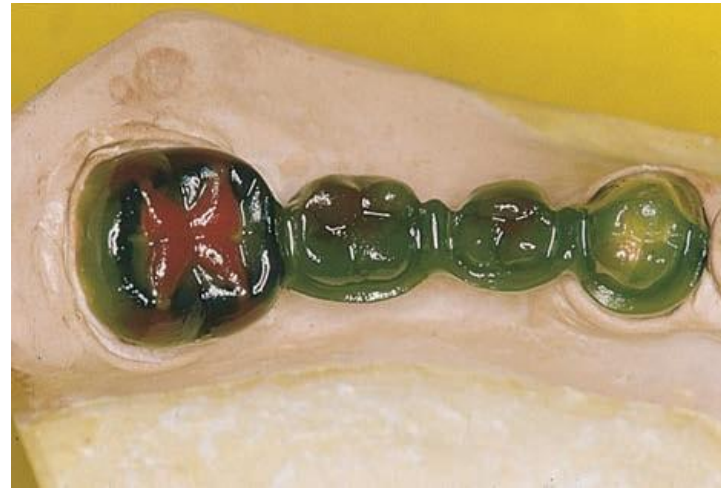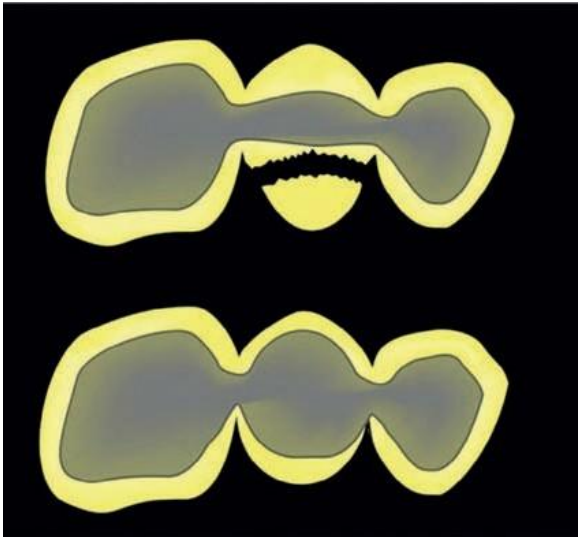
Root surface simulation



Soft tissue simulation

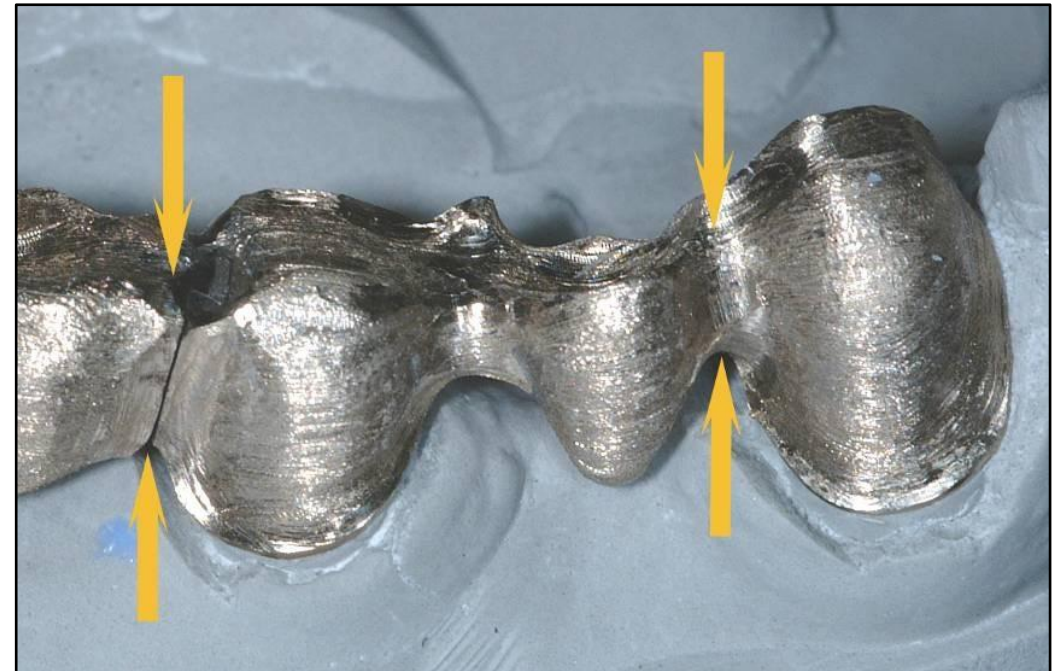
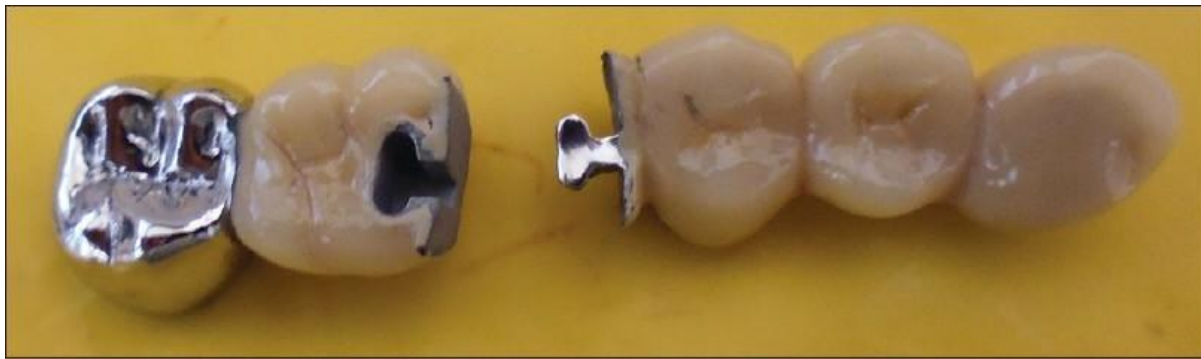PONTICS

- Correct configuration of the metallic or ceramic substructure in the pontic area

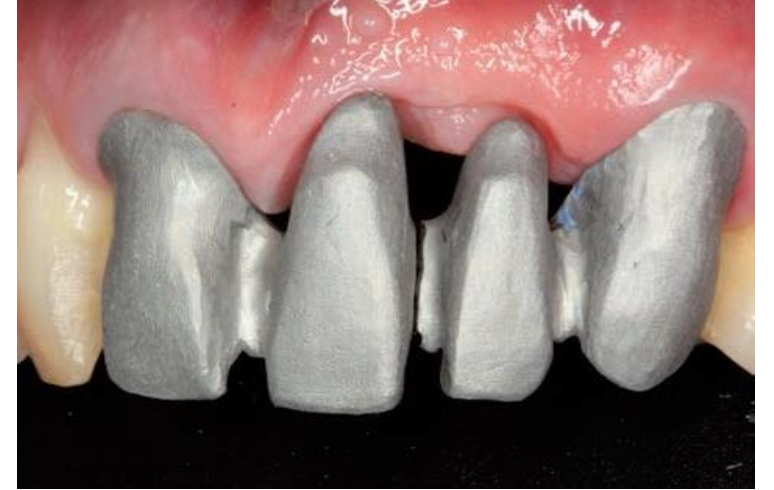
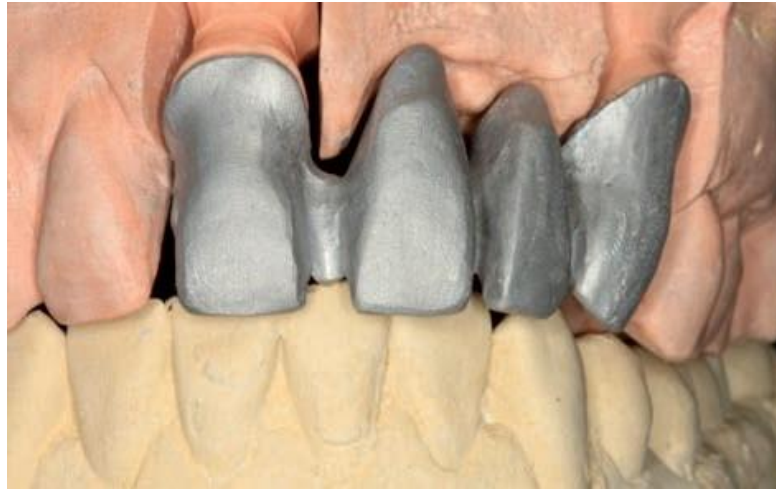
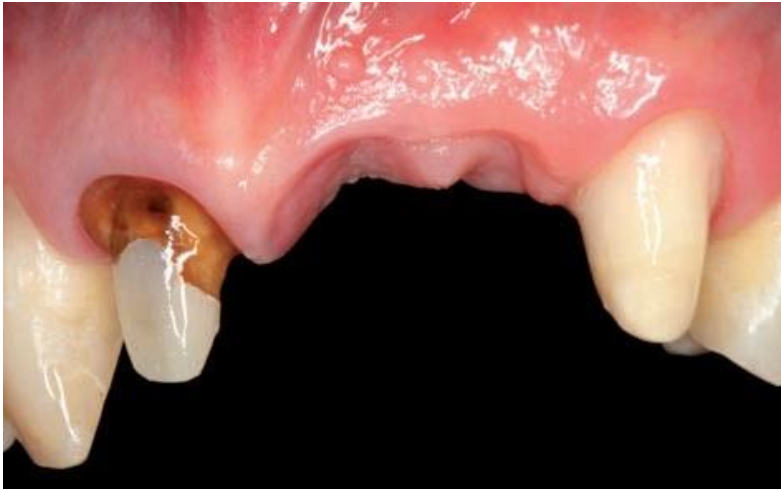CONNECTORS

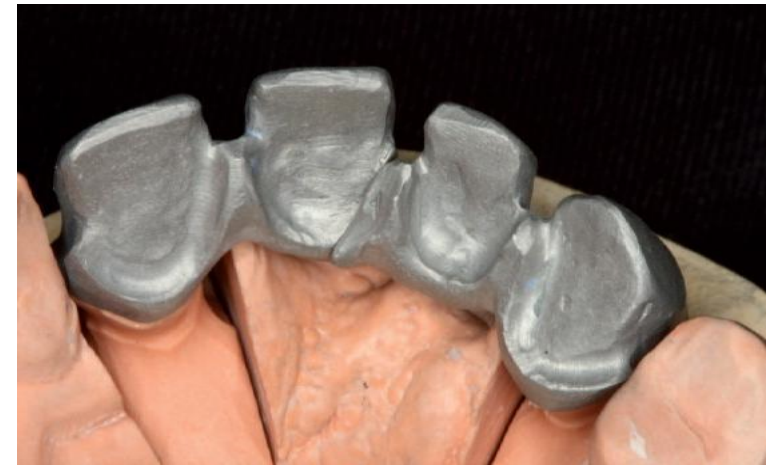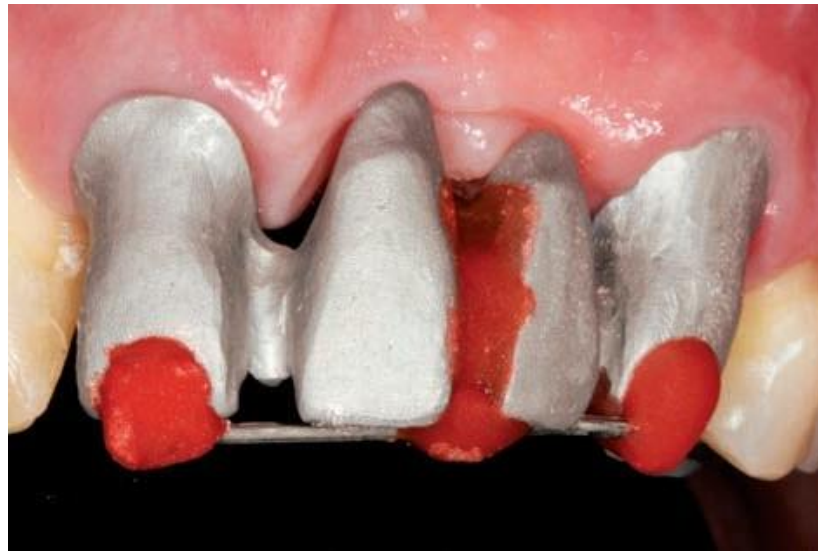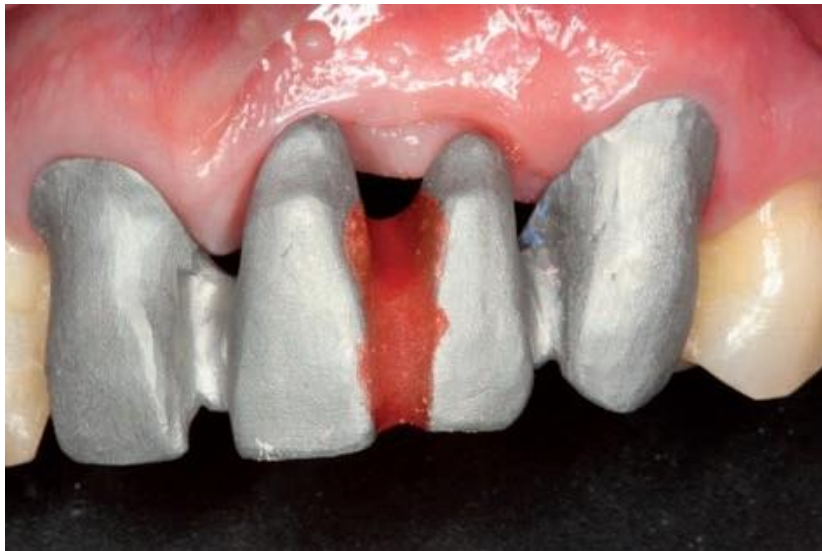- Join individual retainers and pontics together
- Easy to clean, strong
- Types: - rigid: cast or soldered
- non-rigid



CONNECTORS

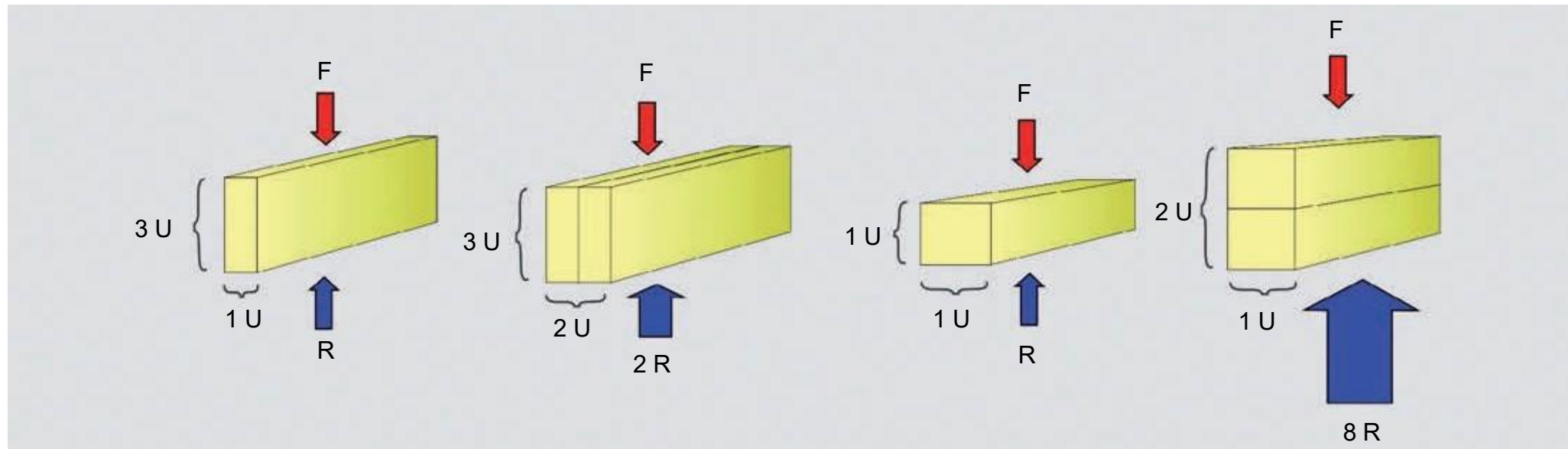


CONNECTORS



CONNECTORS

Law of beams:



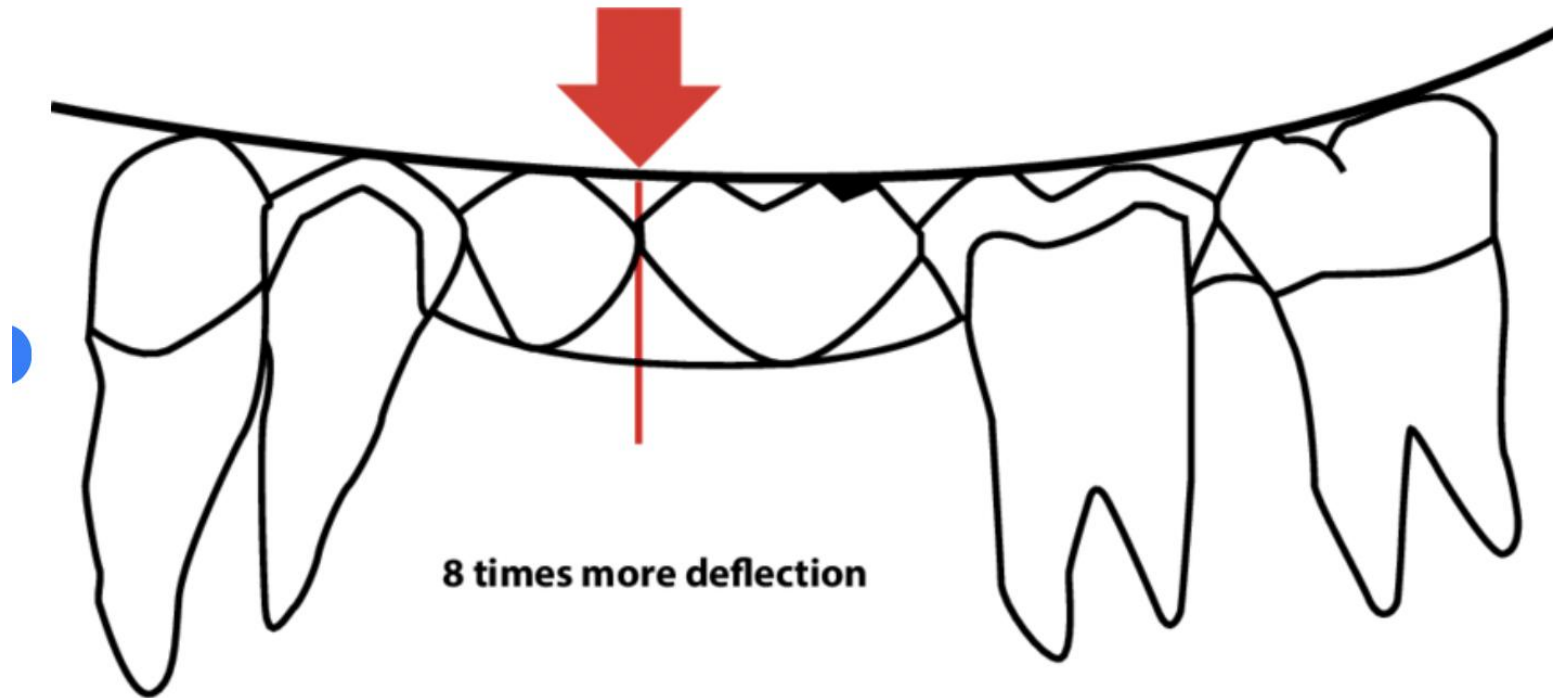
Components



THE UNIVERSITY OF
**WESTERN
AUSTRALIA**



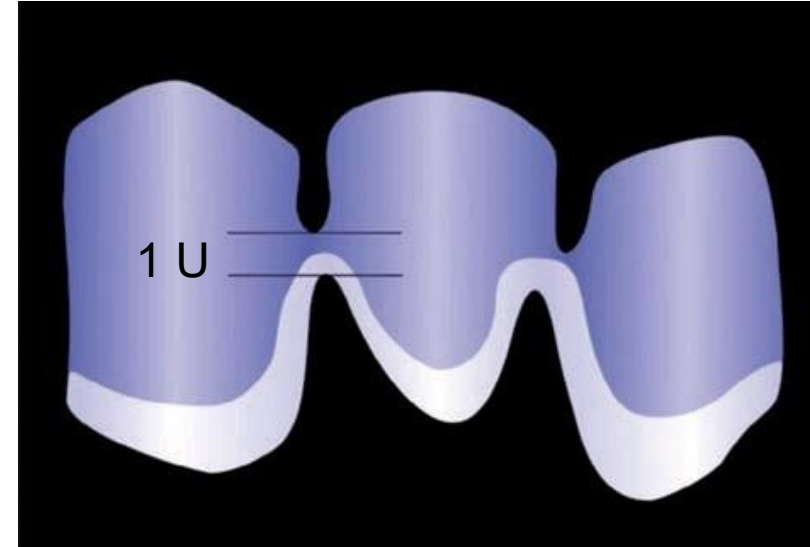
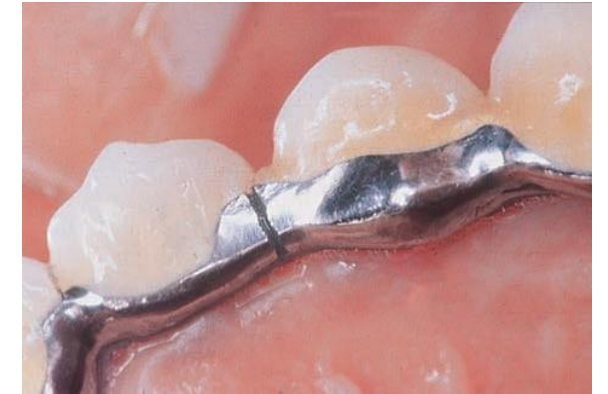
Oral Health Centre
of Western Australia



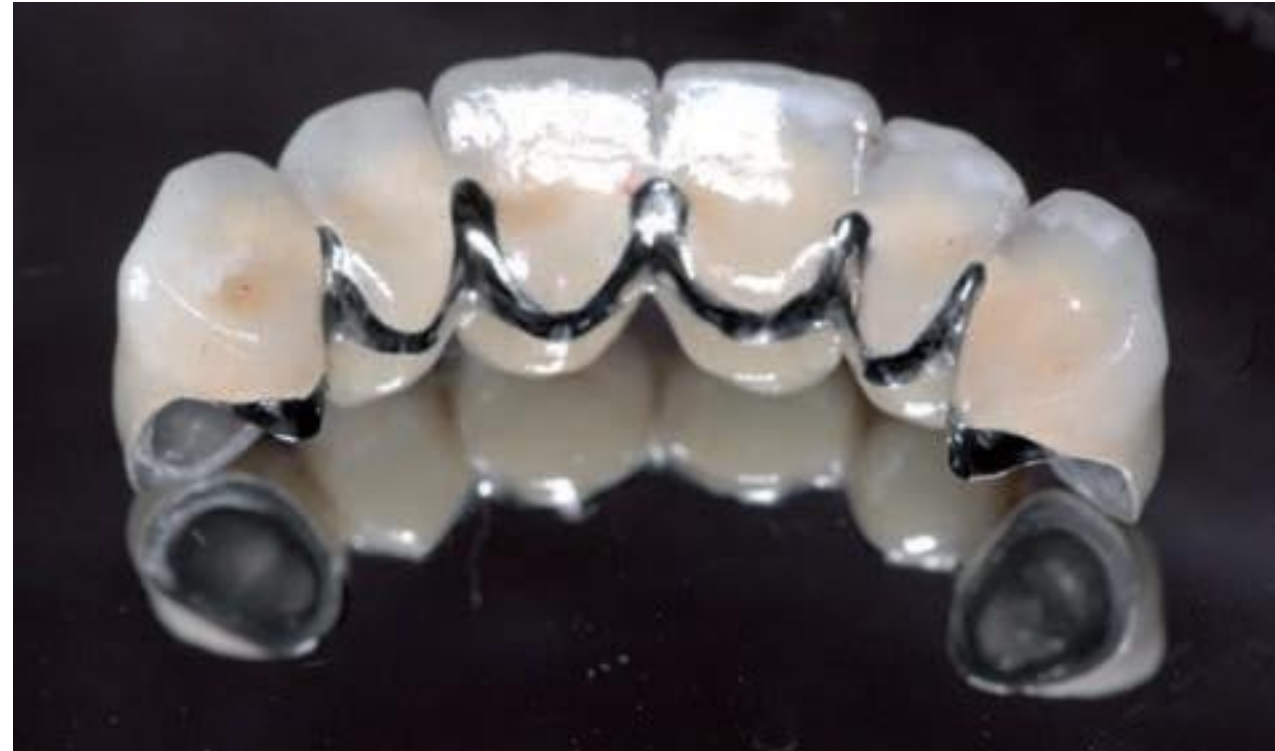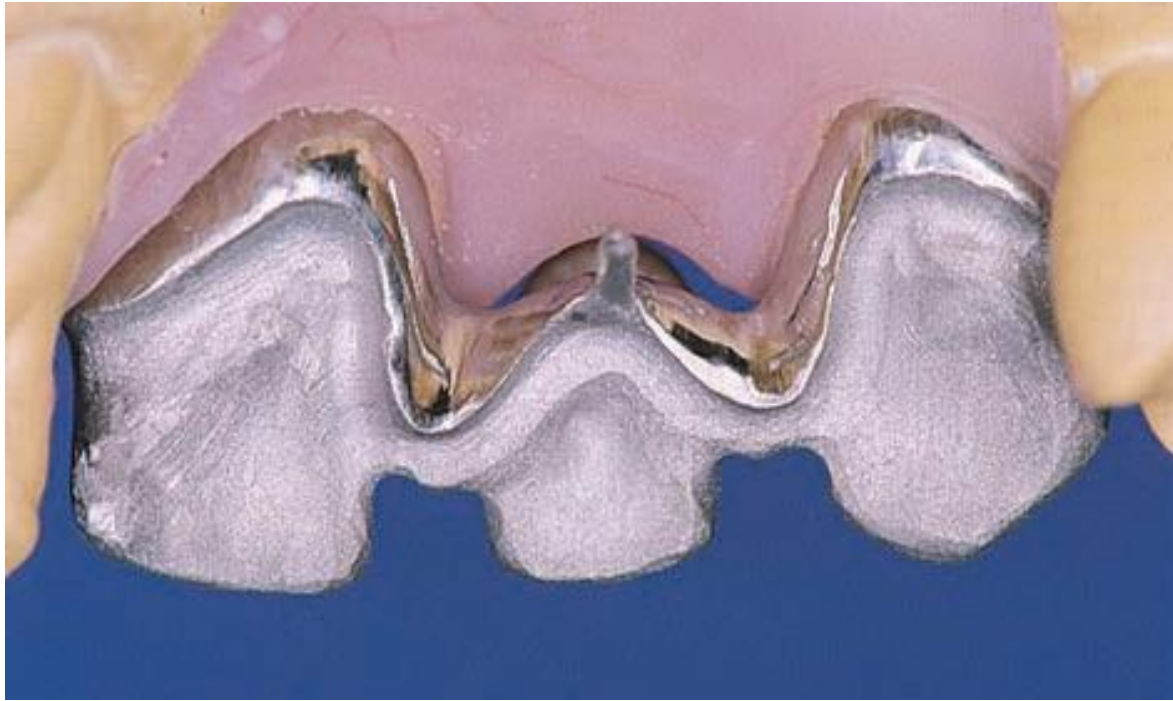Deflection of a fixed dental prosthesis (FDP) is directly proportional to the cube of the length of its span. An FDP with 2 pontics will deflect 2^3 ie 8 times as much as an FDP with 1 pontic.

Aslam A, Khan DA, Hassan SH, Ahmed B. Ceramic fracture in metal-ceramic restorations: the aetiology. Dental update. 2017 May 2;44(5):448-56.

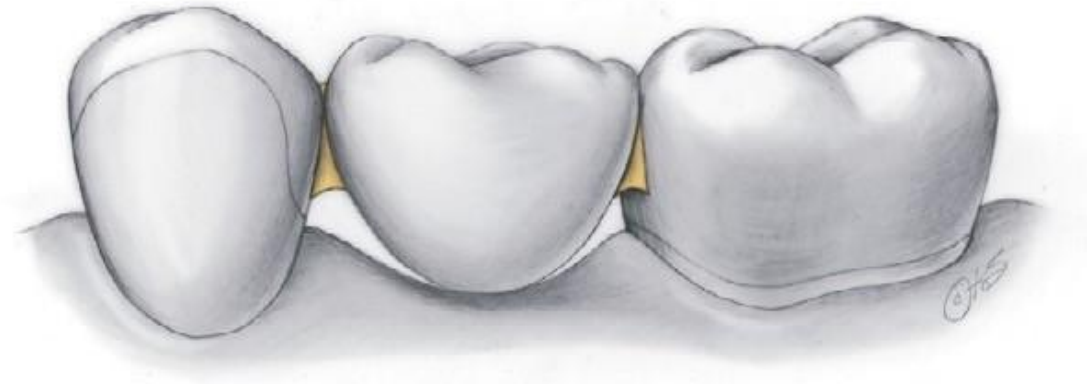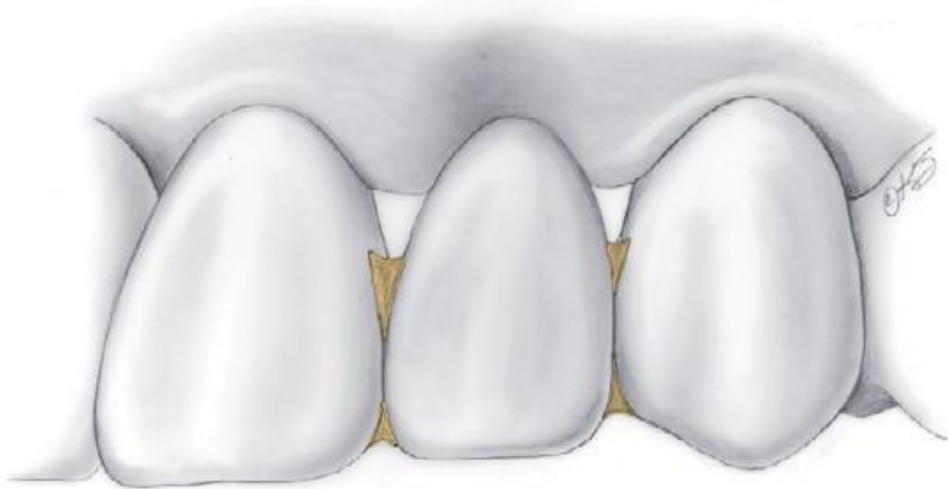CONNECTORS



CONNECTORS



CONNECTORS

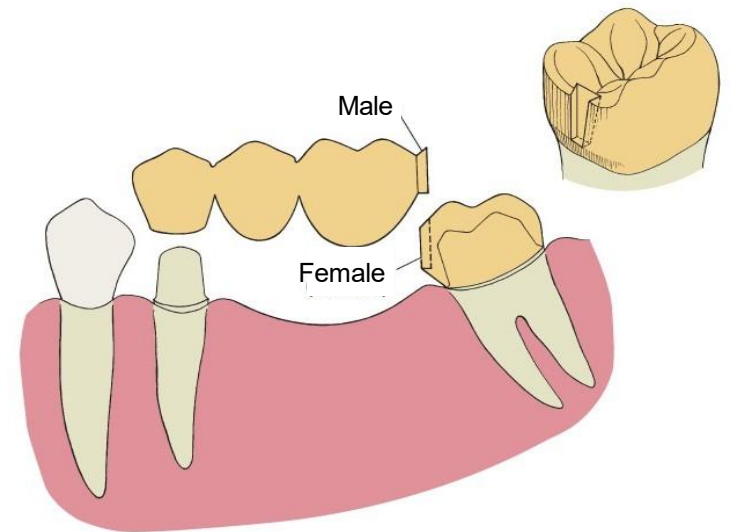
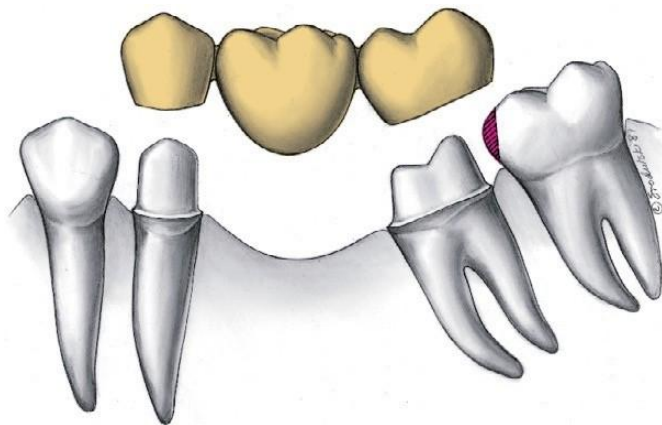


Areas of overcontouring

CONNECTORS

NON-RIGID CONNECTORS

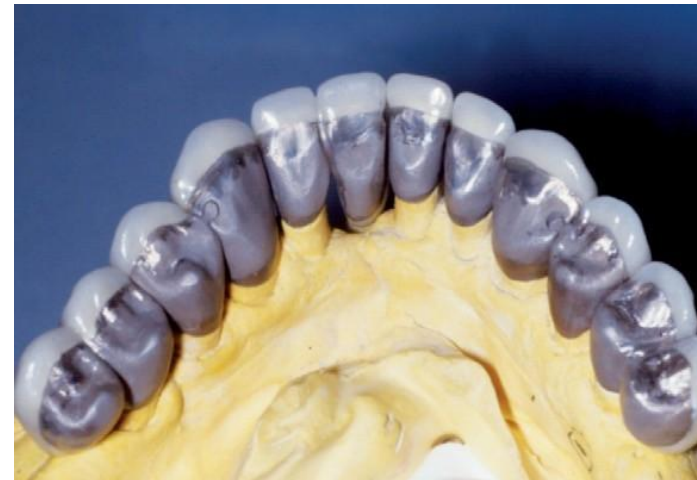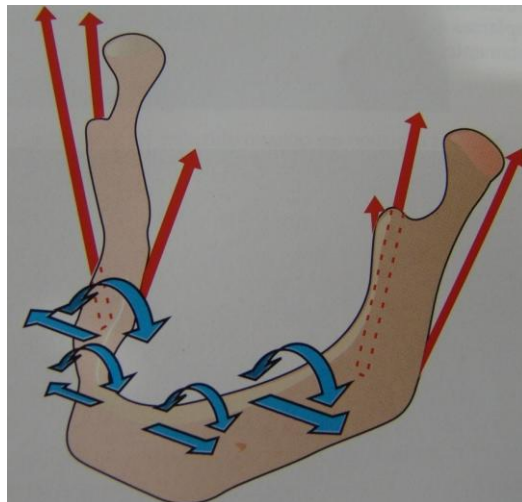
- Impossibility to prepare two abutments for a partial FDP with a common path of placement
- Segment a large FPD into shorter components that are easier to replace or repair individually



CONNECTORS

NON-RIGID CONNECTORS

- Impossibility to prepare two abutments for a partial FDP with a common path of placement
- Segment a large FPD into shorter components that are easier to replace or repair individually
- Prevent the stresses that potentially result from mandibular flexure



Functional Mandibular Deformation in Edentulous Subjects Treated with Dental Implants

Hind H. Abdel-Latif, BDS, MSc, PhD^a
John A. Hobkirk, Dr Med HC, PhD, BDS, FDS
RCS (Eng), FDS RCS (Edin)^b
John P. Kelleway, LIBST, RDT^c

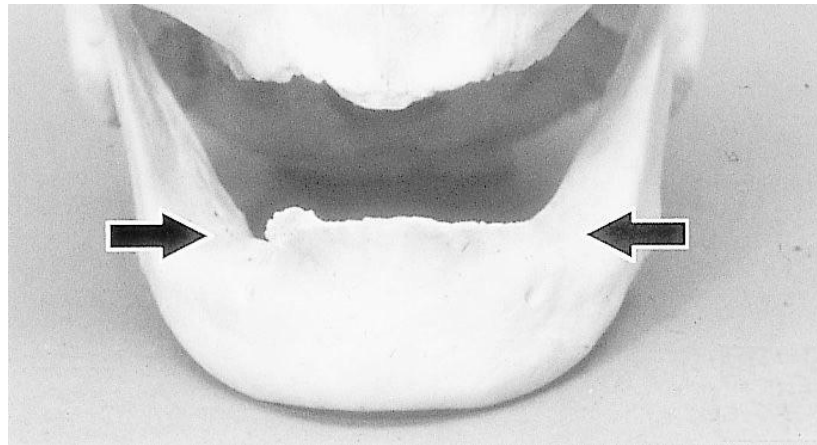
Int J Prosthodont. 2000

Torsion

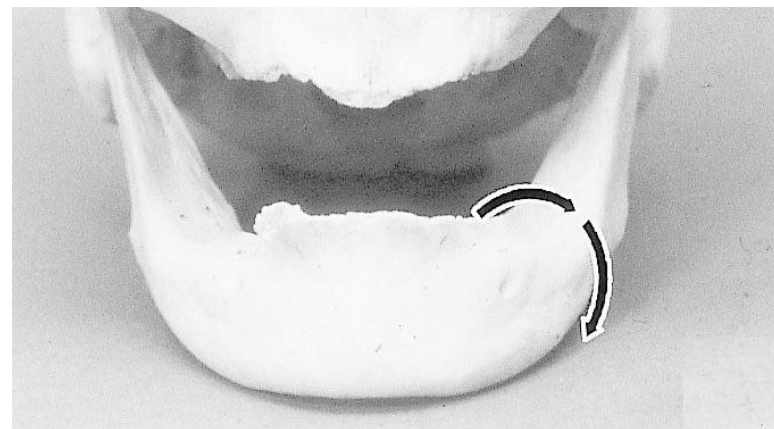Medial Convergence

Corporal Rotation

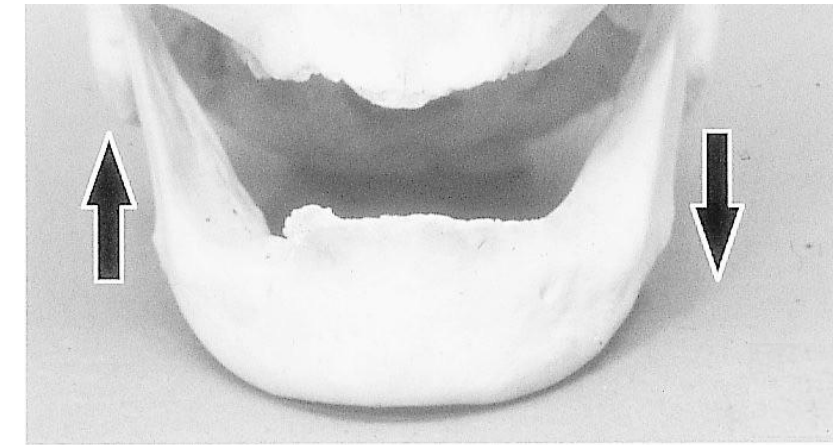
Dorsoventral Shear



- 70 to 780 μm
- Commencement of opening
- After 28% of maximum opening



- Power stroke of mastication
- Opening and closing of the jaw



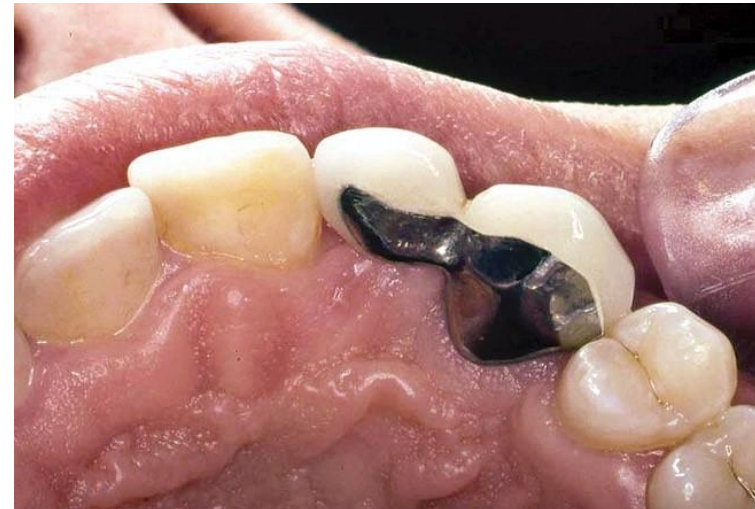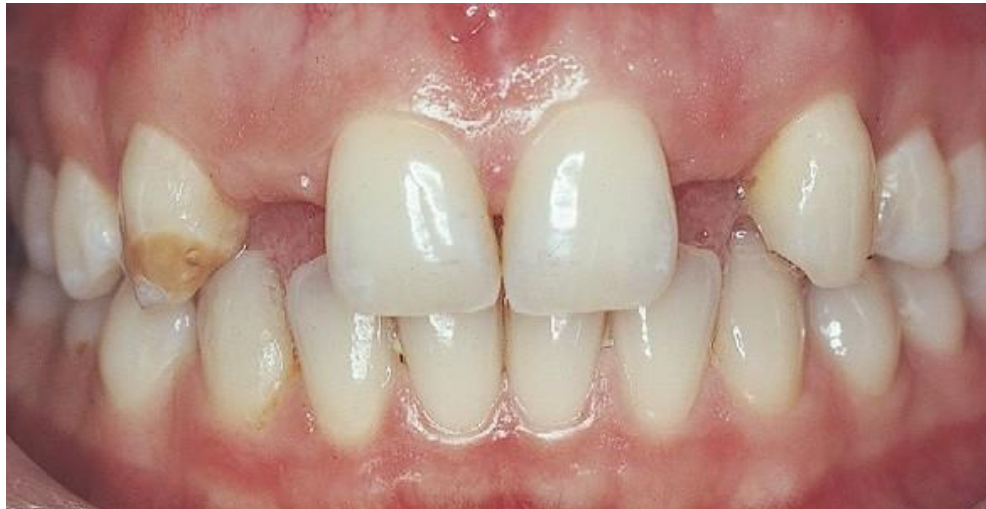- Unilateral mastication
- Opening and closing of the jaw

CANTILEVER

- Only one side of the pontic is attached to a retainer
- Replace one tooth

Assess

- Teeth
- Abutment vitality
- Opposing occlusion
- Edentulous ridge
- Esthetic



Ten-year survival of anterior all-ceramic resin-bonded fixed dental prostheses

Matthias Kern ¹, Martin Sasse

Affiliations + expand

PMID: 21935512 DOI: [10.3290/j.jad.a22096](https://doi.org/10.3290/j.jad.a22096)

Abstract

Purpose: To evaluate the long-term outcome of all-ceramic resin-bonded fixed dental prostheses (RBFDPs) made with a two-retainer design or a cantilever single-retainer design.

Materials and methods: Overall, 38 anterior RBFDPs were made from a glass-infiltrated alumina ceramic (In-Ceram). Sixteen RBFDPs had a two-retainer design, while 22 RBFDPs had a cantilever single-retainer design. Phosphate monomer containing luting agents were used either after silica coating and silanation or after air-abrasion only. The mean observation time in the two-retainer group was 120.2 months and in the single-retainer group 111.1 months.

Results: No restoration debonded. In the two-retainer group unilateral and bilateral fractures of the connectors occurred. In the case of unilateral fracture, the pontic remained in situ as a cantilever RBFDP for several years. In the single-retainer group, only one FDP fractured and was lost 48 months after insertion. The 10-year survival rate was 73.9% in the two-retainer group and 94.4% in the single-retainer group. When unilateral fracture of a FDP was taken as a criterion for failure, the 10-year survival rate decreased to 67.3% in the two-retainer group.

Conclusion: Cantilever all-ceramic RBFDPs are an adequate alternative to two-retainer RBFDPs.

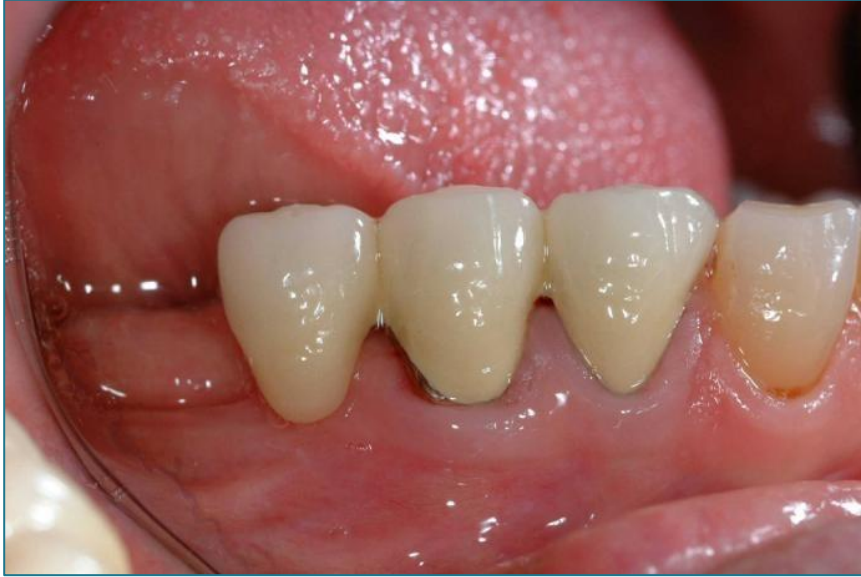Components



THE UNIVERSITY OF
**WESTERN
AUSTRALIA**



Oral Health Centre
of Western Australia



CANTILEVER

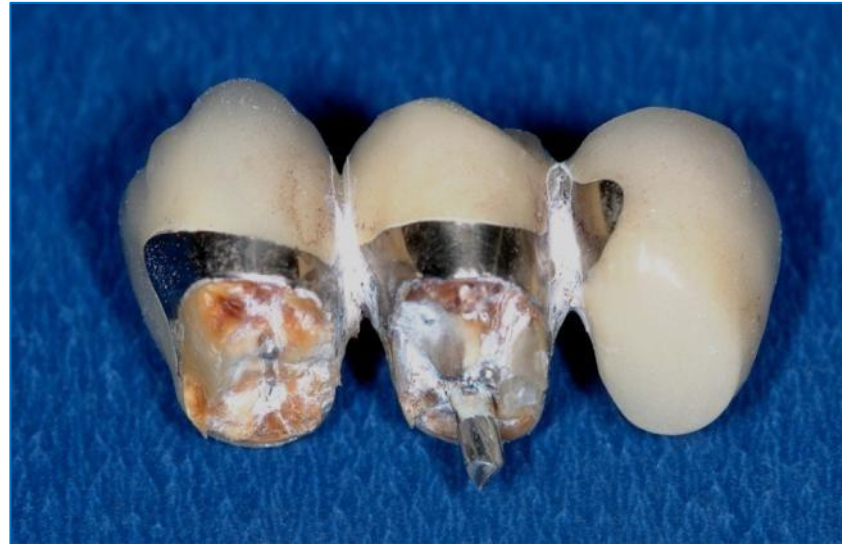
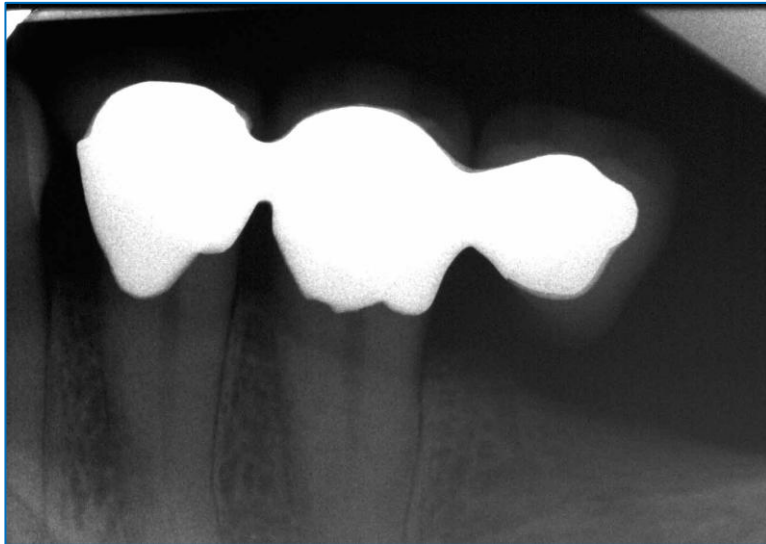
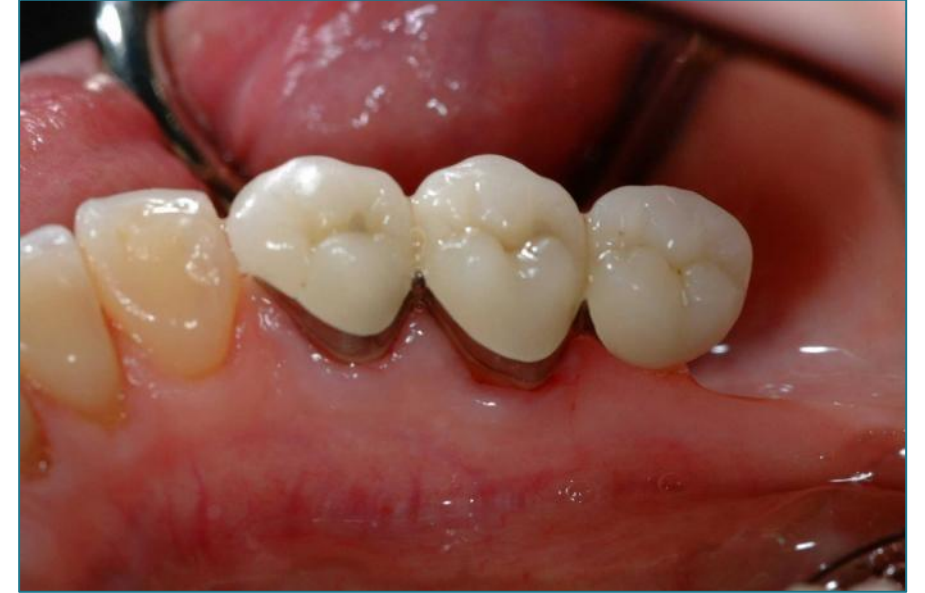

FIGURE 3: Failed posterior cantilever bridge due to fractured premolar abutment.

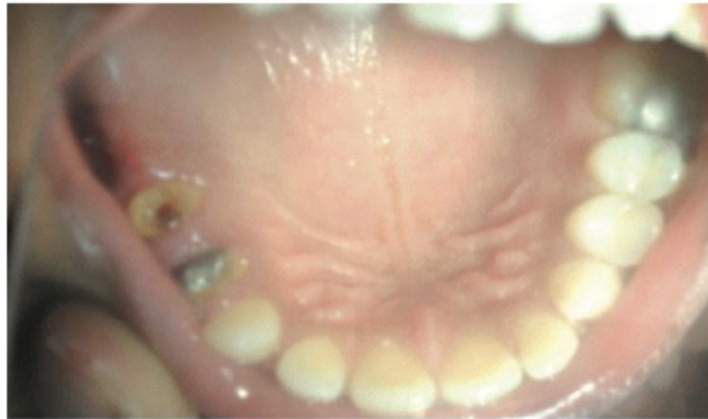

FIGURE 4: Fractured 2nd premolar (abutment next to pontic).

Careful selection of cases!!!

Review Article

Assessment of Various Factors for Feasibility of Fixed Cantilever Bridge: A Review Study

Potentially favorable situations:

- Anterior > Posterior (Anterior open bite ideal. Excessive overlap between maxillary and mandibular teeth is bad due to excursive movements. Replacement of lateral incisor with canine favourable)
- Vital > Non vital (Thought to be less susceptible to root fracture)

CANTILEVER

Adding a second abutment may lessen the forces experienced by the most distal abutment, and help in rotational forces. However greater challenge to the cement on the further abutment crown

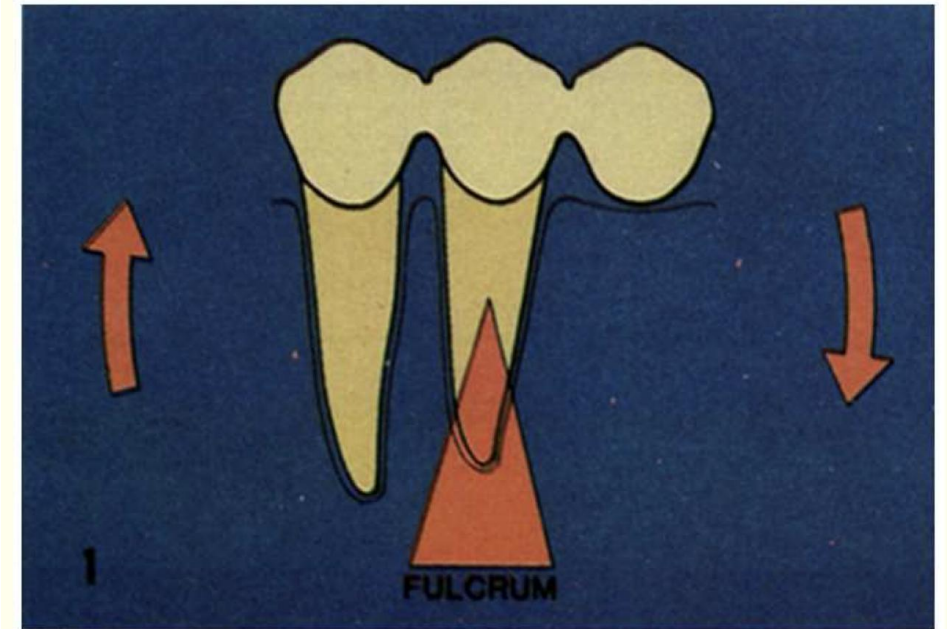
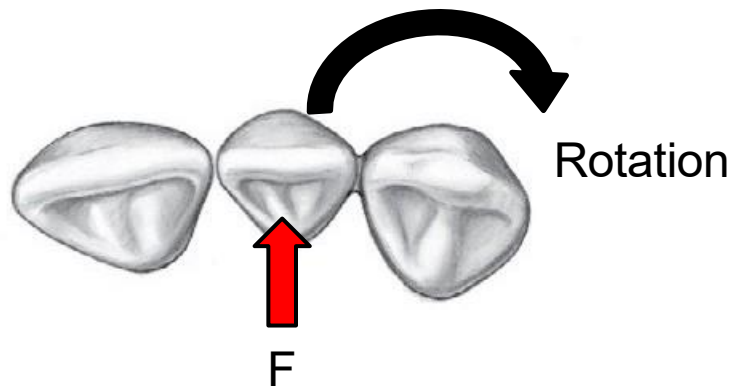
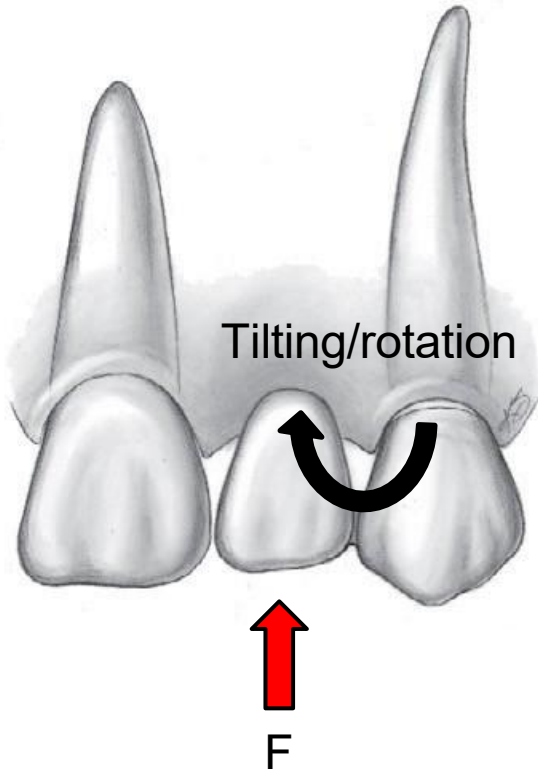
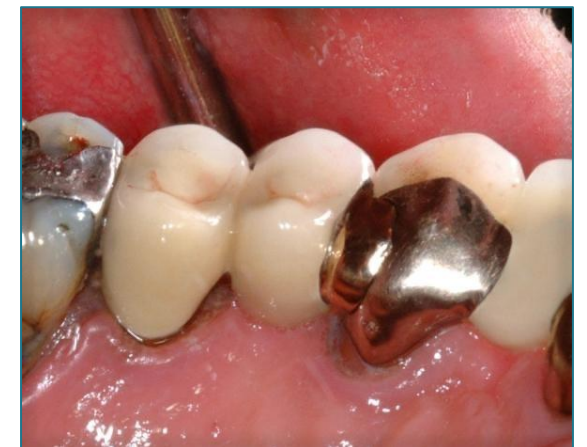
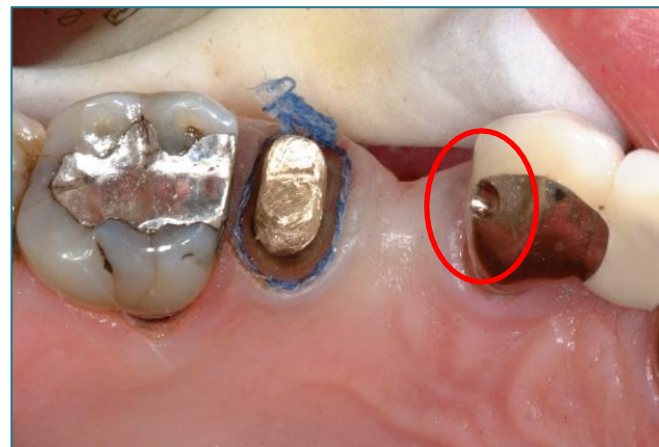
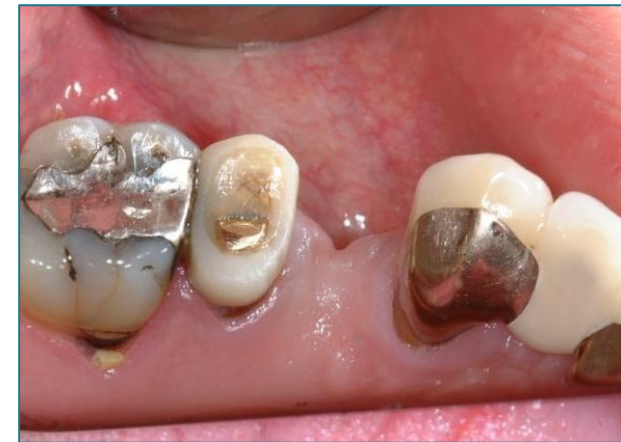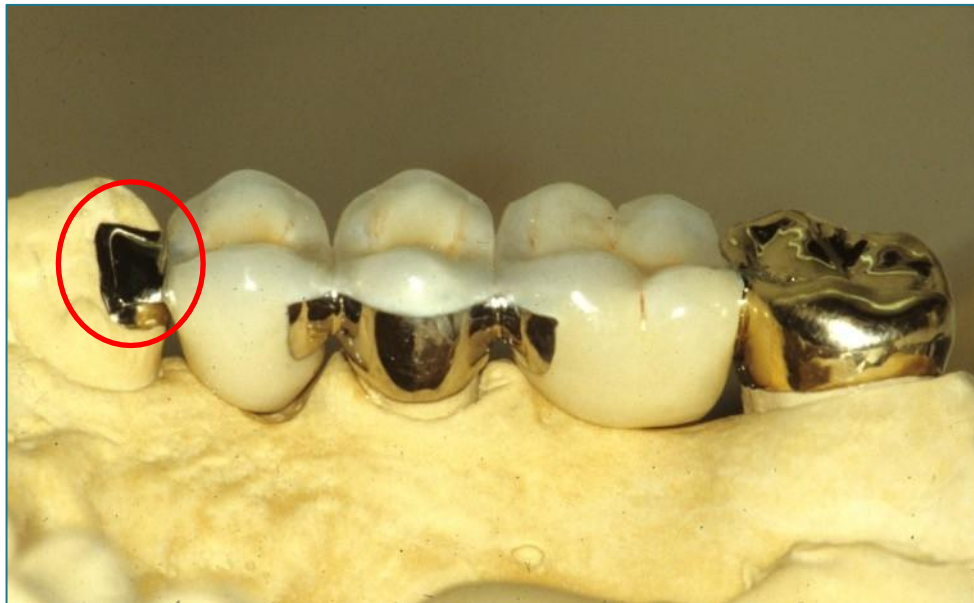Figure 1: Creation of a class 1 lever by a cantilevered FPD [3].

CANTILEVER



Thanks for listening!



Thank you!