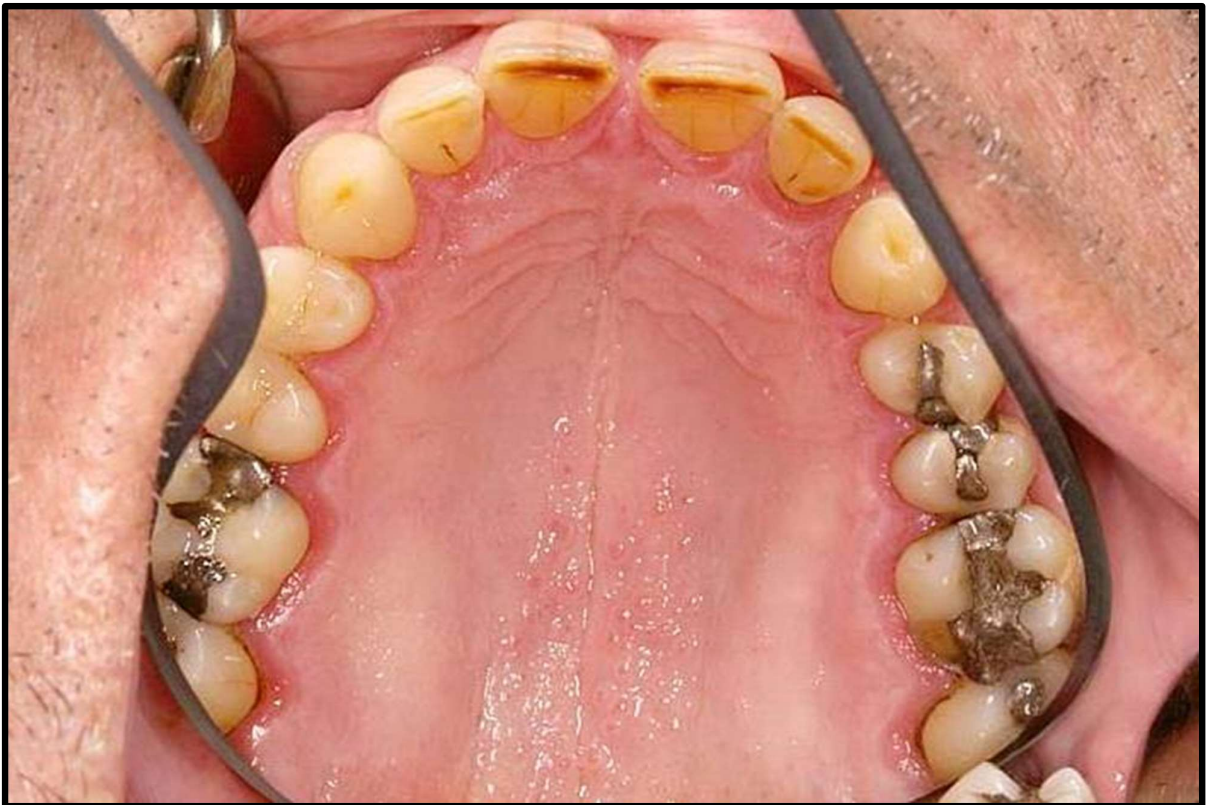
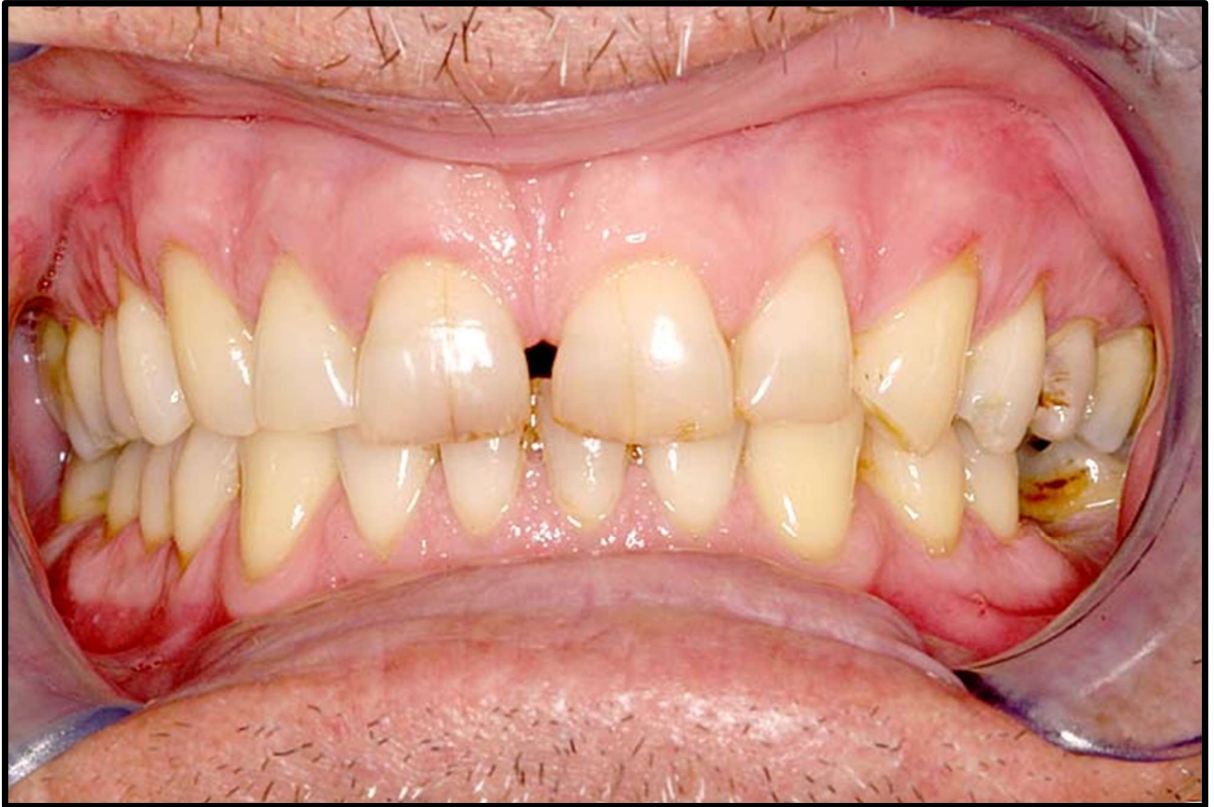
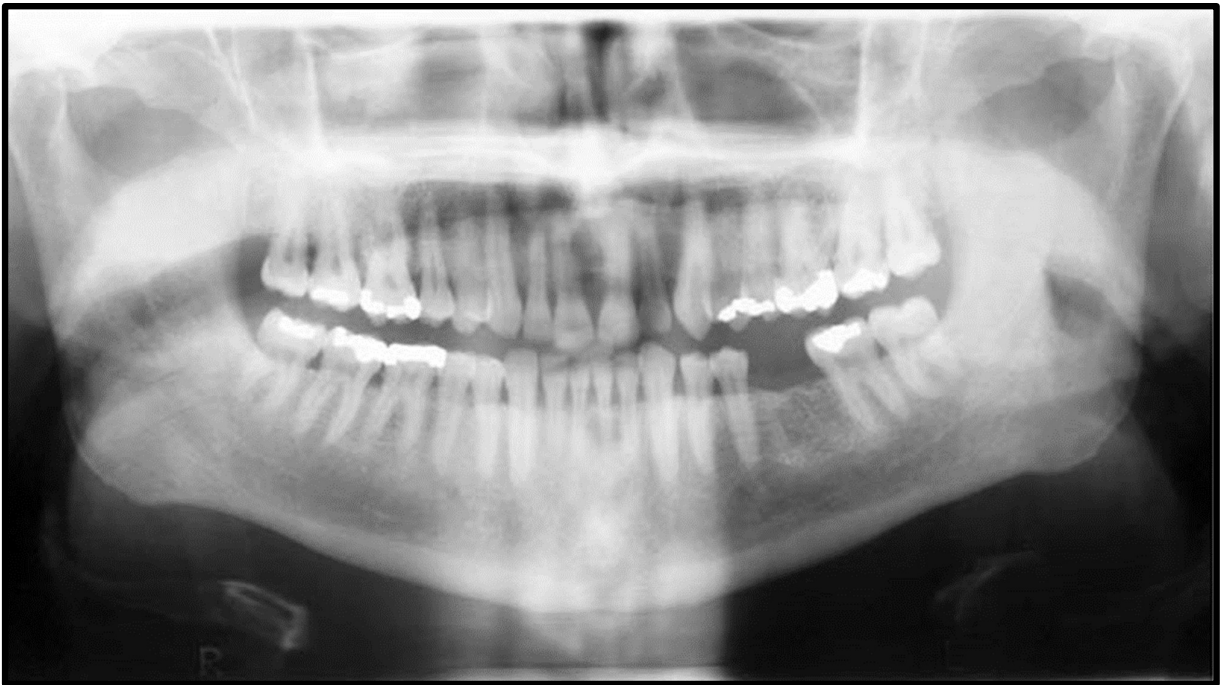
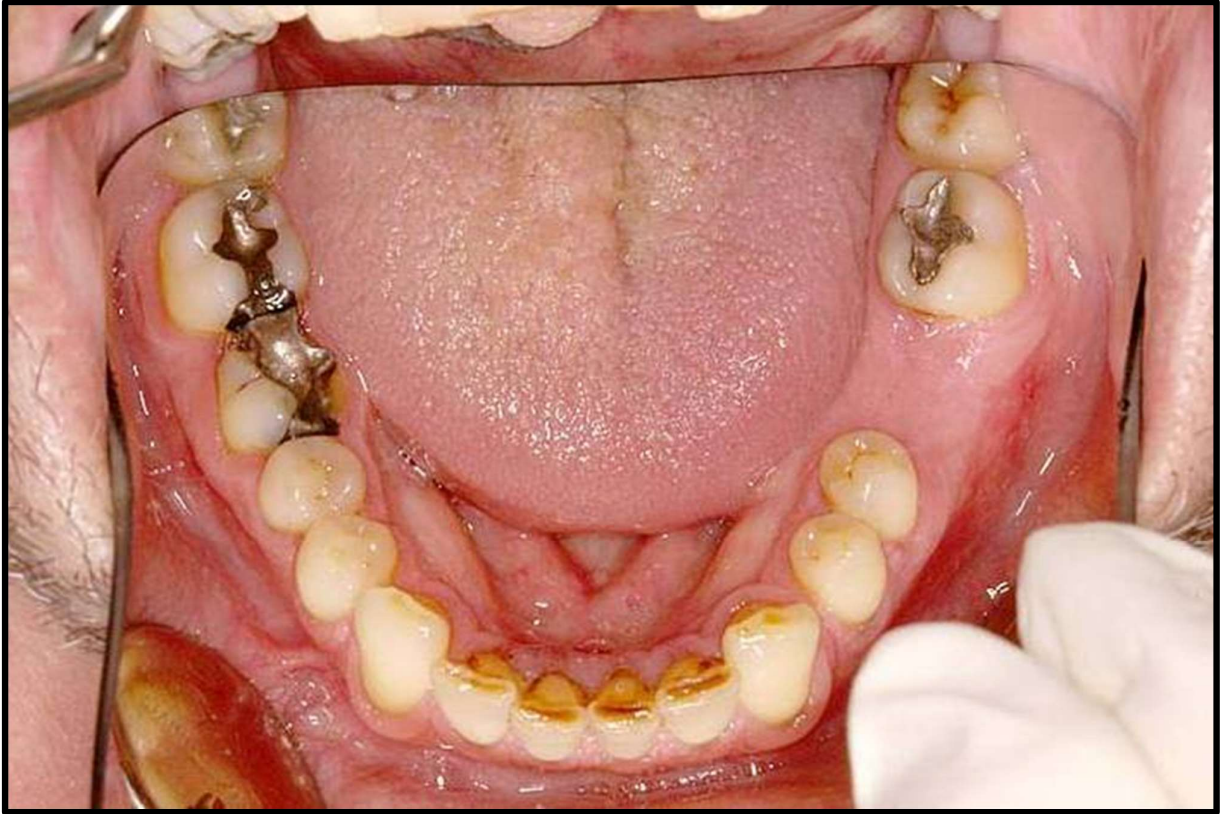# CASE DISCUSSION

---



## CASE DISCUSSION

---



# CASE DISCUSSION

---

## Case description:

A 52-year-old male diagnosed with metastatic SCC to the right neck of unknown primary origin to be treated with surgery & radiation therapy is referred to you for dental assessment. All malars are planned to be in the irradiated field and will receive 60Gy. His medical history is otherwise non-contributory. He is a smoker of 25 years (10 cigarettes per day) and reported consuming 4 alcoholic drinks per week on average. He sees his dentist regularly on a 12<sup>th</sup> monthly basis for dental examinations and prophylaxis.

## Activity:

1. How would you manage this patient?

- Timeline for exos
  - ↳ how long before exo?
- "Call radiologist" if issues

- ↳ what teeth would you extract?

- ↳ P/T compliance
  - ↳ remove all

- ↳ substance abuse?

- ↳ Arthritis?

- ↳ Perio?

- ↳ Prognosis?

- Smoking!

- Counselling

- ↳ Nf 5000  
2x daily

- ↳ Diet