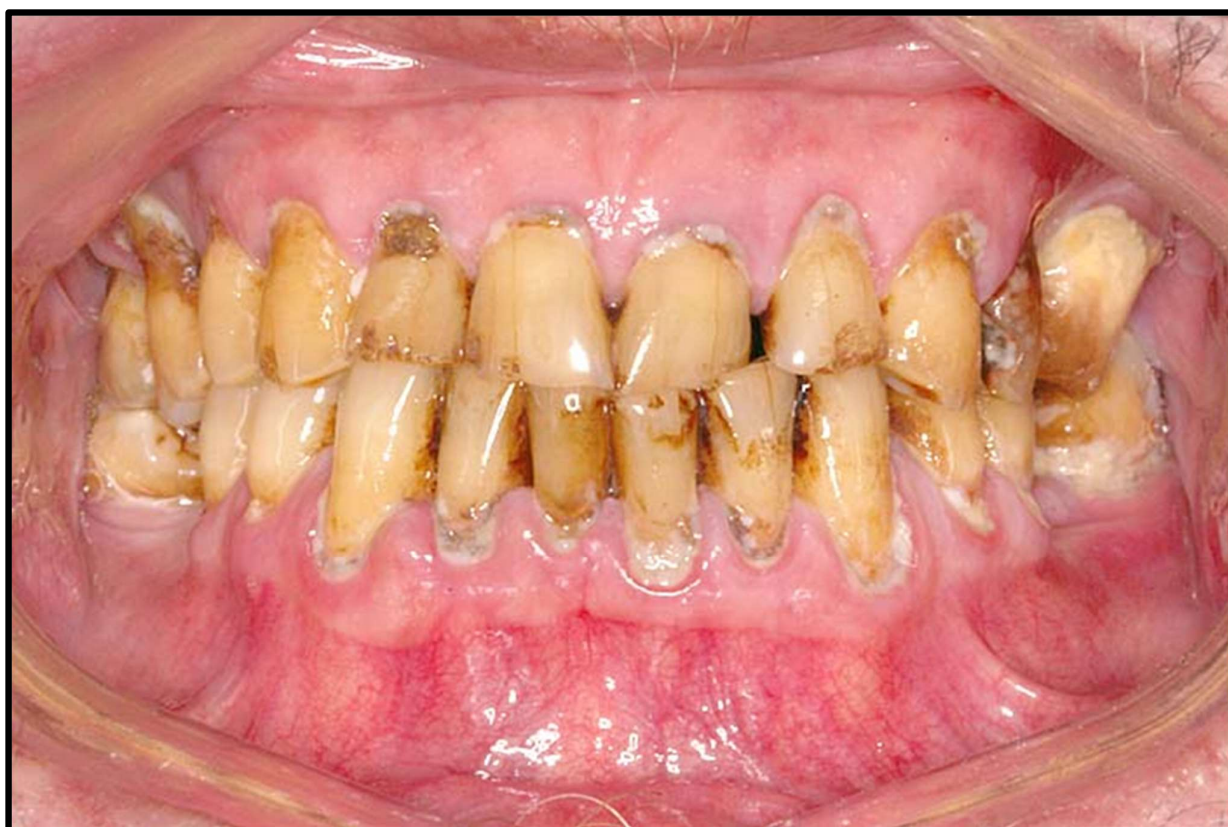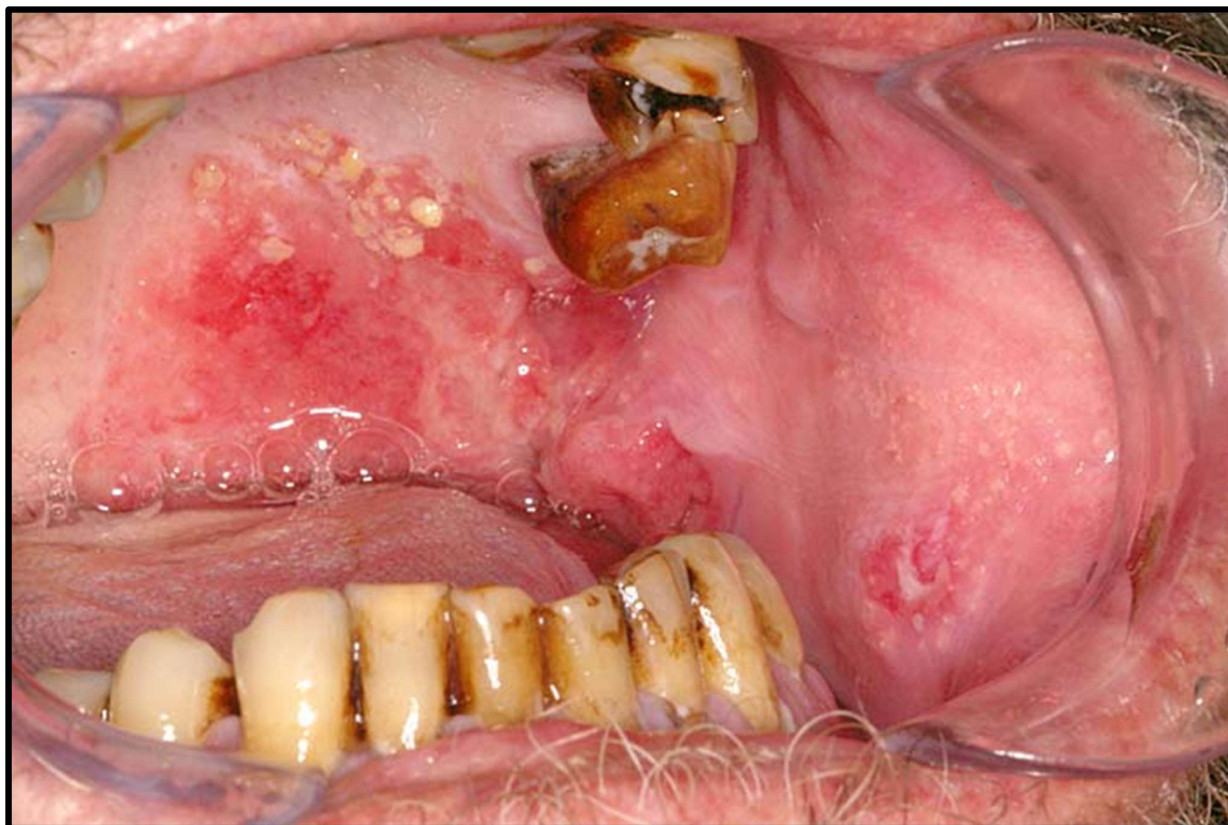


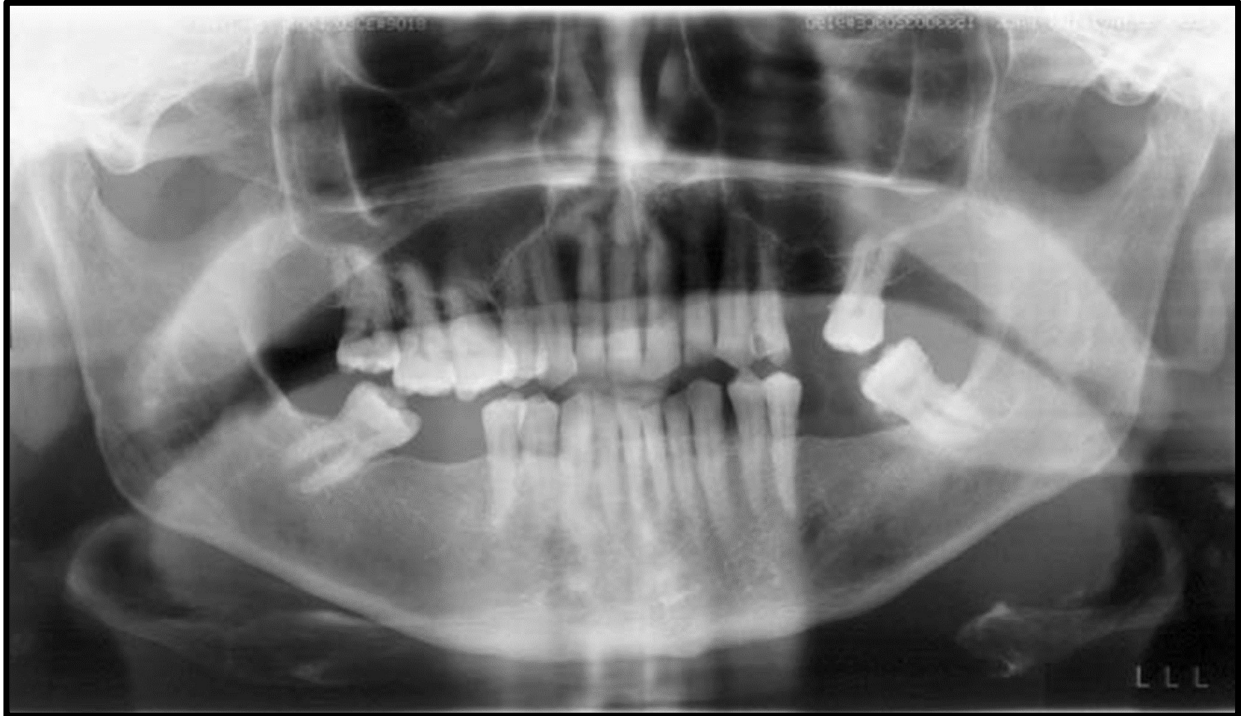
## CASE DISCUSSION

---



# CASE DISCUSSION

---



## Case description:

*A 60-year-old male diagnosed with oral SCC to be treated with surgery & radiation therapy is referred to you for dental assessment. His medical history is significant for depression. All molars and premolars are planned to be in the irradiated field and will receive 66Gy. He is unemployed and lives alone. He is a smoker of 30 years (25 cigarettes per day) and reported consuming at least 6 – 8 stubbies per day. He does not have a regular dentist and will only attend appointments if he needs to.*

## Activity:

1. How would you manage this patient?