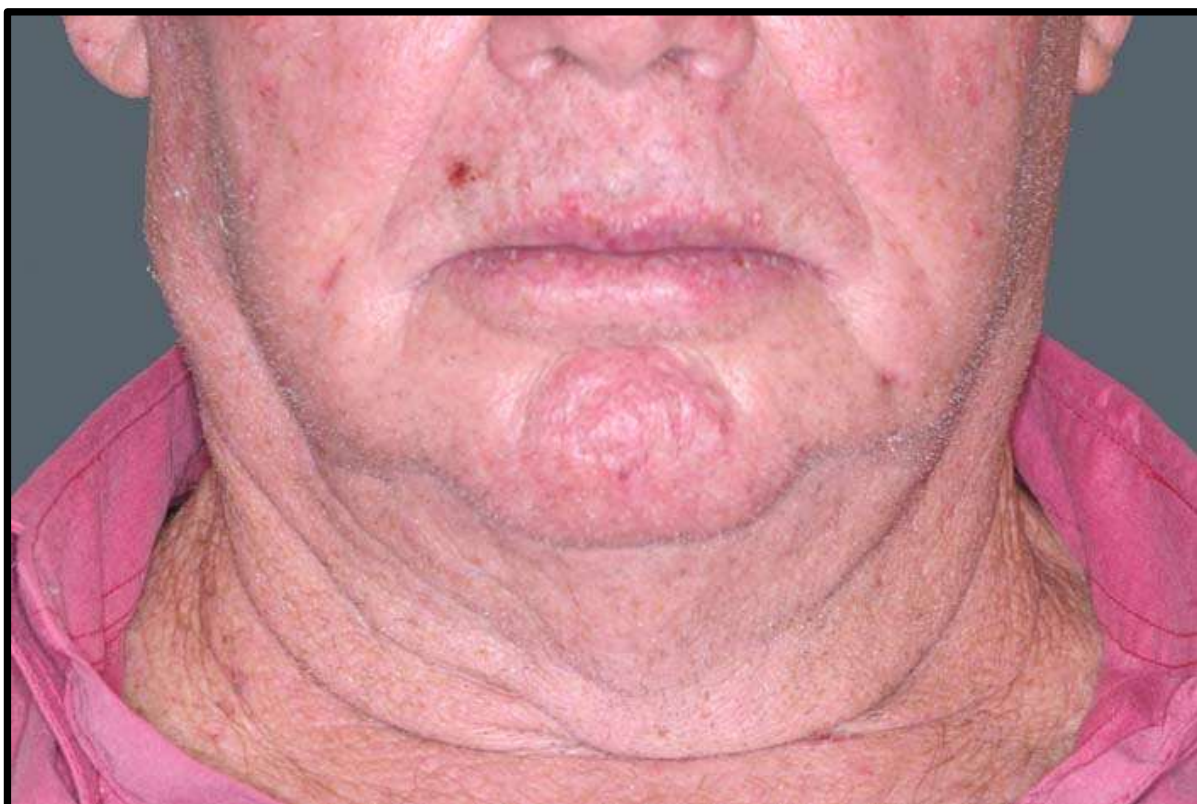
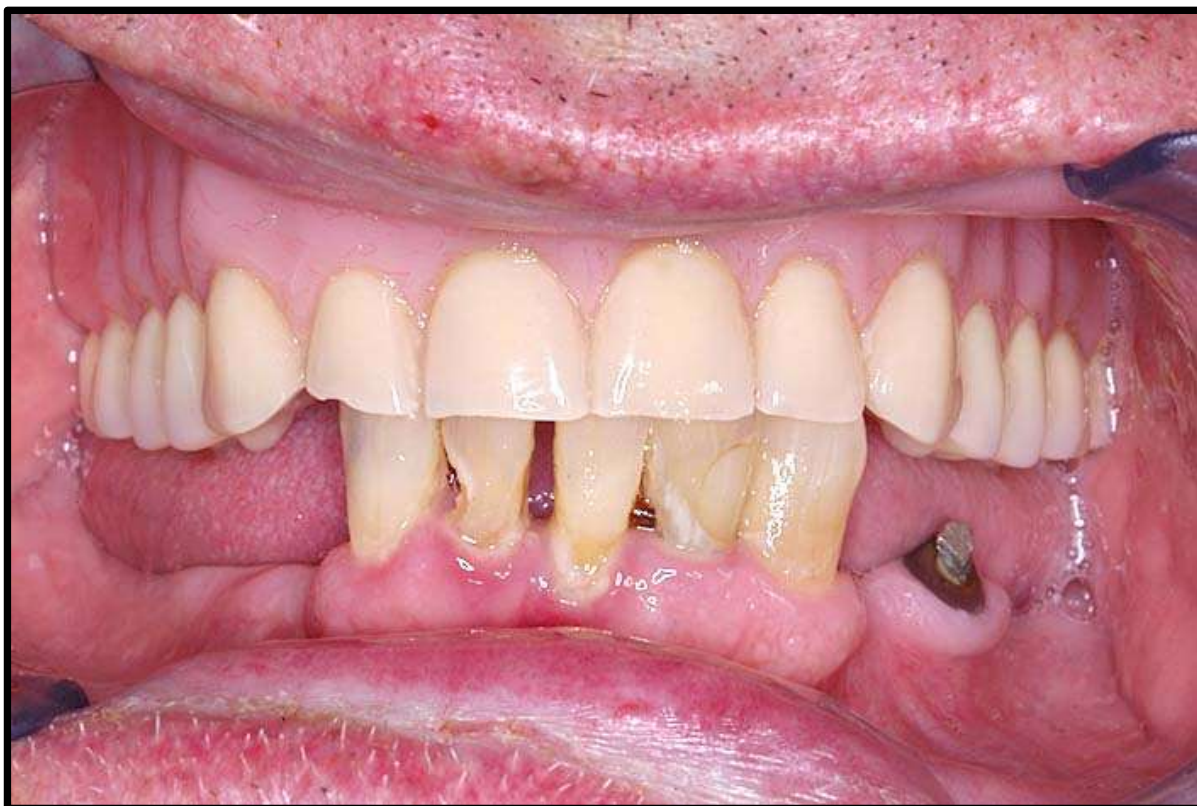

DISCUSSION CASE



DISCUSSION CASE

Case description:

A 68 year old male presented for a routine appointment with a complaint of being unable to chew well and wanted to know his restorative treatment options. He could not remember when he last saw a dentist but it was " a long time ago." His medical history is significant for hypertension, hypercholesterolaemia, ischaemic heart disease, osteoarthritis and skin cancers. He has not smoked in 30 years and reported consuming 1-2 alcoholic drinks per week, on average.

Activity:

1. Identify the pathosis and describe the clinical features
2. What is the differential diagnosis?
3. What are the relevant clinical investigations?
4. What is the diagnosis?
5. How would you manage this patient?