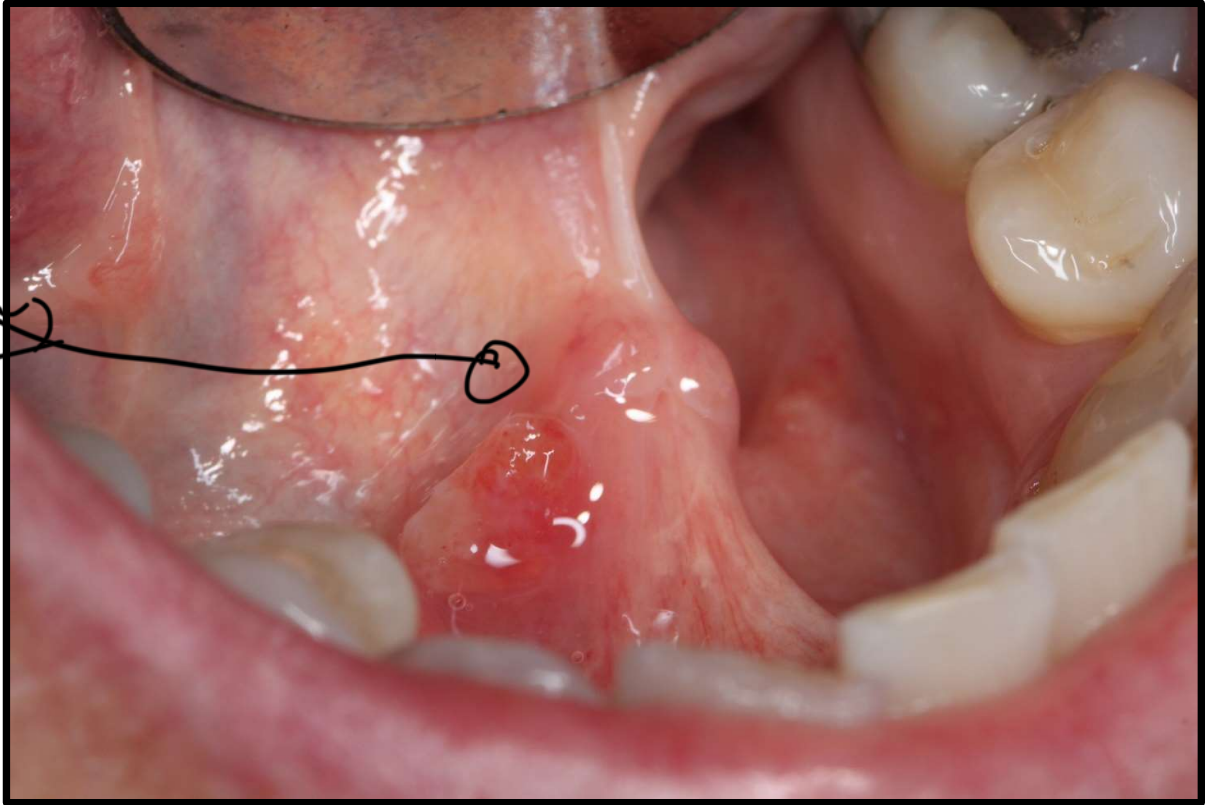


DISCUSSION CASE

most
common
is mucov
plugs
or sialadenoma



Case description:

48-year-old Female presented with asymptomatic lesion shown. She has been aware of the presence of the lesion over the last two months. Her medical history is non-contributory. She is a non-smoker and does not drink alcohol.

Activity:

1. Identify the pathosis and describe the clinical features
↳ mucocoele? what's the cause? ↳
2. What is the differential diagnosis?
3. What are the relevant clinical investigations?
↳
4. What is the diagnosis?
5. How would you manage this patient?