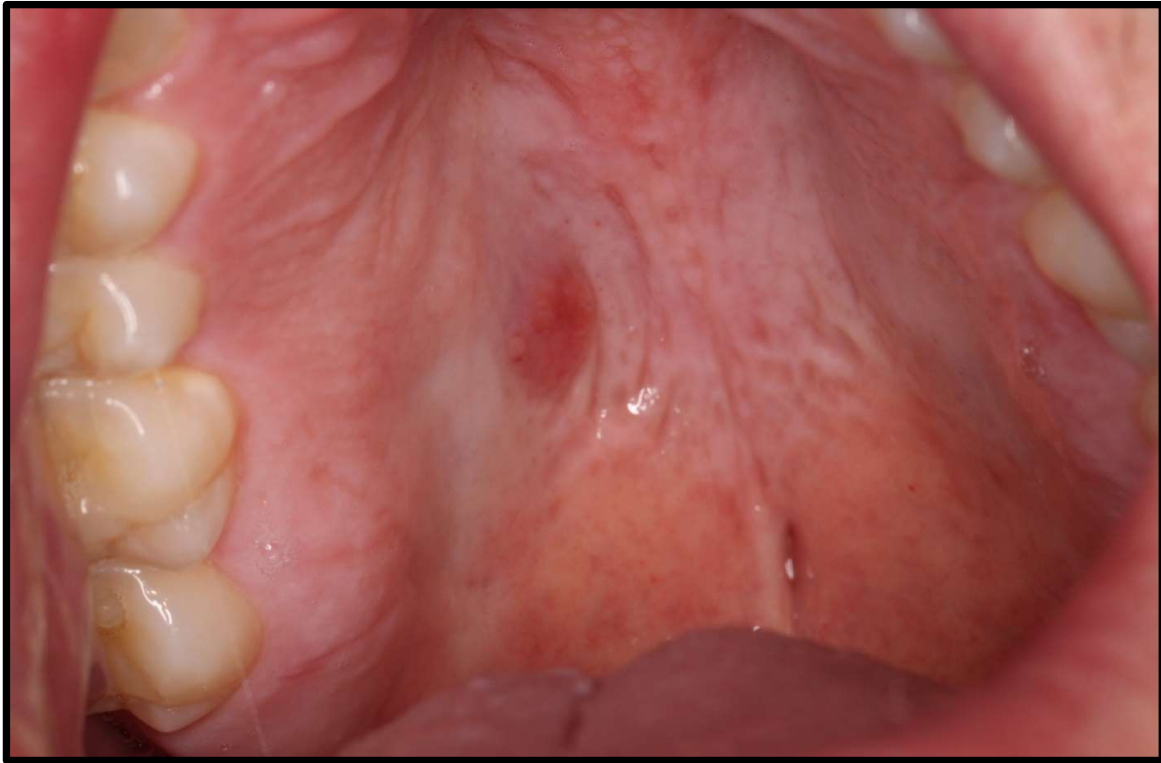


## DISCUSSION CASE



### Case description:

*A 40 year-old Male presented with the asymptomatic mucosal swelling shown. He has been unaware of the presence of the lesion, which was coincidentally noted during a routine dental examination. His medical history is non-contributory. He is a smoker of 10 years (15 cigarettes / day) and reported consuming 2 alcoholic drinks per day.*

### Activity:

1. Identify the pathosis and describe the clinical features
2. What is the differential diagnosis?
3. What are the relevant clinical investigations?
4. What is the diagnosis?
5. How would you manage this patient?