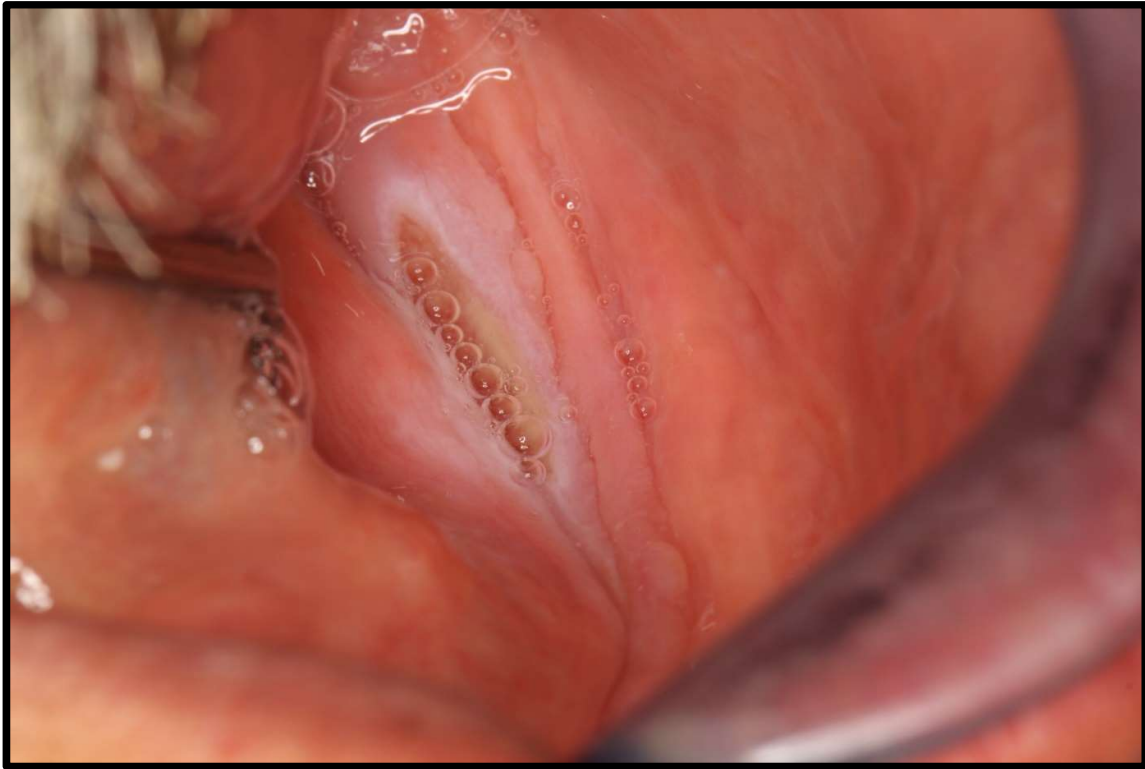


CASE DISCUSSION



Case description:

52-year-old male presented with a 6-week history of a painful lesion, which he has been treating with Kenalog with no response. His medical history is significant for diabetes, hypertension and hypercholesterolemia. He is a smoker of 30 years, smoking 15 cigarettes per day and reported consuming two alcoholic drinks per day, on average. He is edentulous and his current dentures are 5 years old.

Activity:

1. Identify the pathosis and describe the clinical features
2. What is the differential diagnosis?
3. What are the relevant clinical investigations?
4. What is the diagnosis?
5. How would you manage this patient?