

Periodontal wound healing and regeneration

Dr. Pradeep Koppolu & Dr Anna Hughes

Reading Resources



Chapter 21 and 45

Periodontal Wound Healing and Regeneration

Lindhe's Clinical Periodontology and Implant Dentistry Volume 7 2022

<https://youtu.be/ub2gGelwGCM>

https://youtu.be/_gn-OBzkoEU

<https://youtu.be/yb6TzZqmuTE>

CHAPTER 63

Periodontal Regeneration

Richard T. Kao | Daniel R. Clark | Henry H. Takei | Guo-Hao Lin

For online-only content on analysis of periodontal wound healing, non-graft-associated procedures, analysis of laser associated periodontal wound healing, autologous bone grafts, guided tissue regeneration membranes, miscellaneous biologics for periodontal regeneration, scaffold or supporting matrices, and therapeutic considerations, please visit the companion website at eBooks.Health.Elsevier.com.

CHAPTER OUTLINE

Assessment of Periodontal Wound Healing versus Regeneration Regenerative-Associated Procedures Regenerative Surgical Approaches Graft Materials and Procedures Non-Graft-Associated Reconstructive Procedures Periodontal Regeneration Utilizing Biologics	Enamel Matrix Derivative Recombinant Human Platelet-Derived Growth Factor-BB for Periodontal Regeneration Cell Therapy Use of Platelet-Rich Plasma/Platelet-Rich Fibrin for Periodontal Regeneration Combined Techniques	Regenerative Supportive Graft Materials Factors That Influence Therapeutic Success Clinical Guidelines to Guide Clinicians in Their Patient Management Future Directions for Periodontal Regeneration Conclusion
--	--	---

Aims of Periodontal Therapy

- 1- Restore and maintain structure and function of teeth throughout the individuals' life.
- 2 – Control dysbiosis, inducing favourable clinical alterations in the periodontium.
- 3 – Regeneration /repair
- 4 -Improve aesthetics

Periodontal Therapy procedures and Wound healing

Non-surgical therapy after risk factor management (steps 1 and 2)

Surgical

- **Surgical therapy (mucoperiosteal flap)**
 - **Regenerative procedures, guided tissue/ bone regeneration**
 - **Periodontal plastic /pre-prosthetic surgery**
 - **Implant surgery**

Growth factors

Cell therapy

Gene therapy

3D printed scaffolds

Host modulation therapy- NSAID, low dose tetracyclines- control enzymes

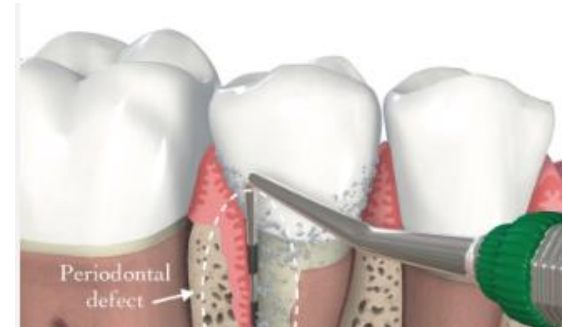Bone metabolism enzyme control

Antioxidants- eg resveratrol

Wound and Healing

Wound/injury

Disruption of the anatomic structure and function in a body part



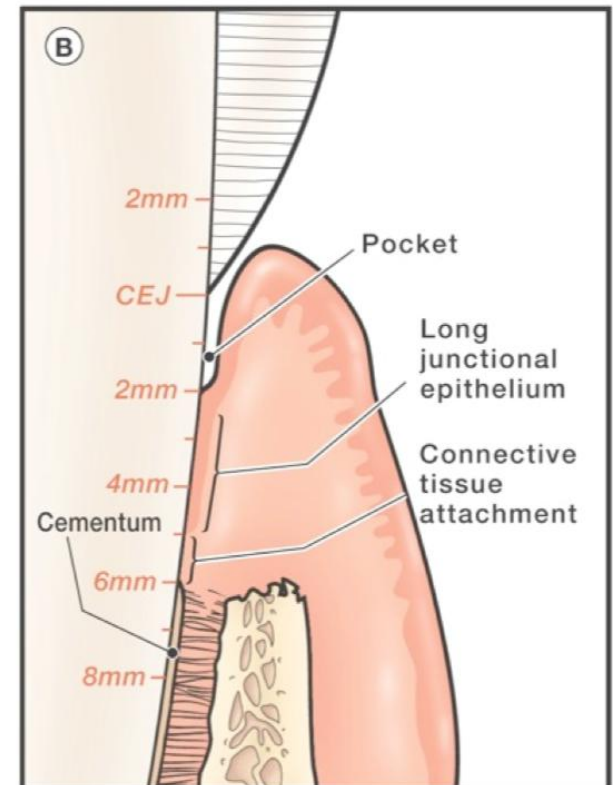
Healing

Cell/tissue response to injury in an attempt to restore the normal structure and function.

Peculiarities in the Periodontal area:

Wound margins are opposing a rigid non-vascularized surface

After non-surgical periodontal therapy, the pocket heals by forming long junctional epithelium



Phases of wound healing

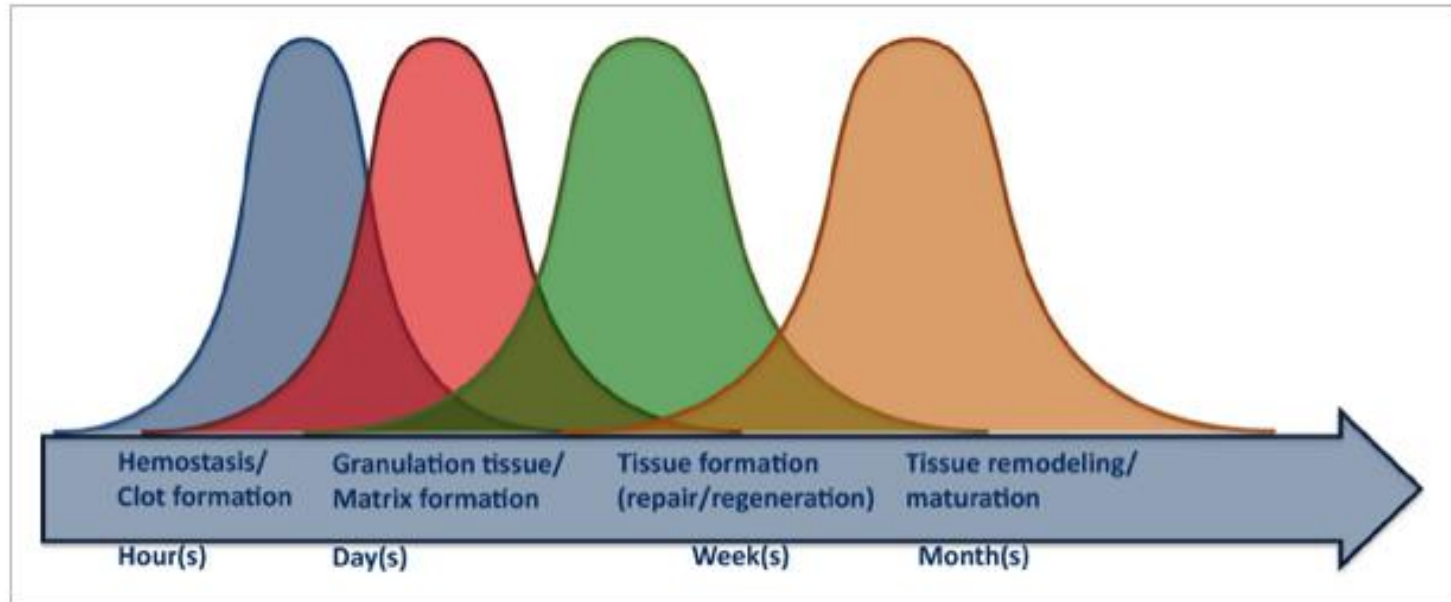


Figure 3

[Open in figure viewer](#) | [PowerPoint](#)

Timetable depicting early and late phases of wound healing/regeneration.

Sequence of well-orchestrated innate temporal and spatial events that dictate the outcomes of wound healing, either perio regeneration or perio repair.

These events follow a dynamic complex biomolecular path involving cell migration, proliferation, differentiation, angiogenesis, extracellular matrix formation and remodeling.

Phases of healing after injury

Immediate response-Initial clot- essential to protect wound and act as matrix for cell migration

Inflammation phase-Growth factors in initial blood clot attract inflammatory cells (mostly neutrophils and monocytes) which cleanse wound and initiate repair.

Granulation phase- @ day 4-Macrophages predominate to continue decontamination but also formation of granulation tissue with recruitment of fibroblast, endothelial cells, smooth muscle cells-highly regulated, growth factors and cytokines involved- collagen formation occurs , cell-matrix and cell to cell links

Maturation phase- @ day 7-Fibroblasts aid in tissue maturation, myofibroblasts help wound contraction, healing responds to functional demands – **regeneration or repair**

Periodontal wound healing more complex than epidermal wound healing

Factors that affect healing – local factors (infection, tissue trauma, poor vascular perfusion) Systemic factors –hormones, stress , nutritional deficiencies

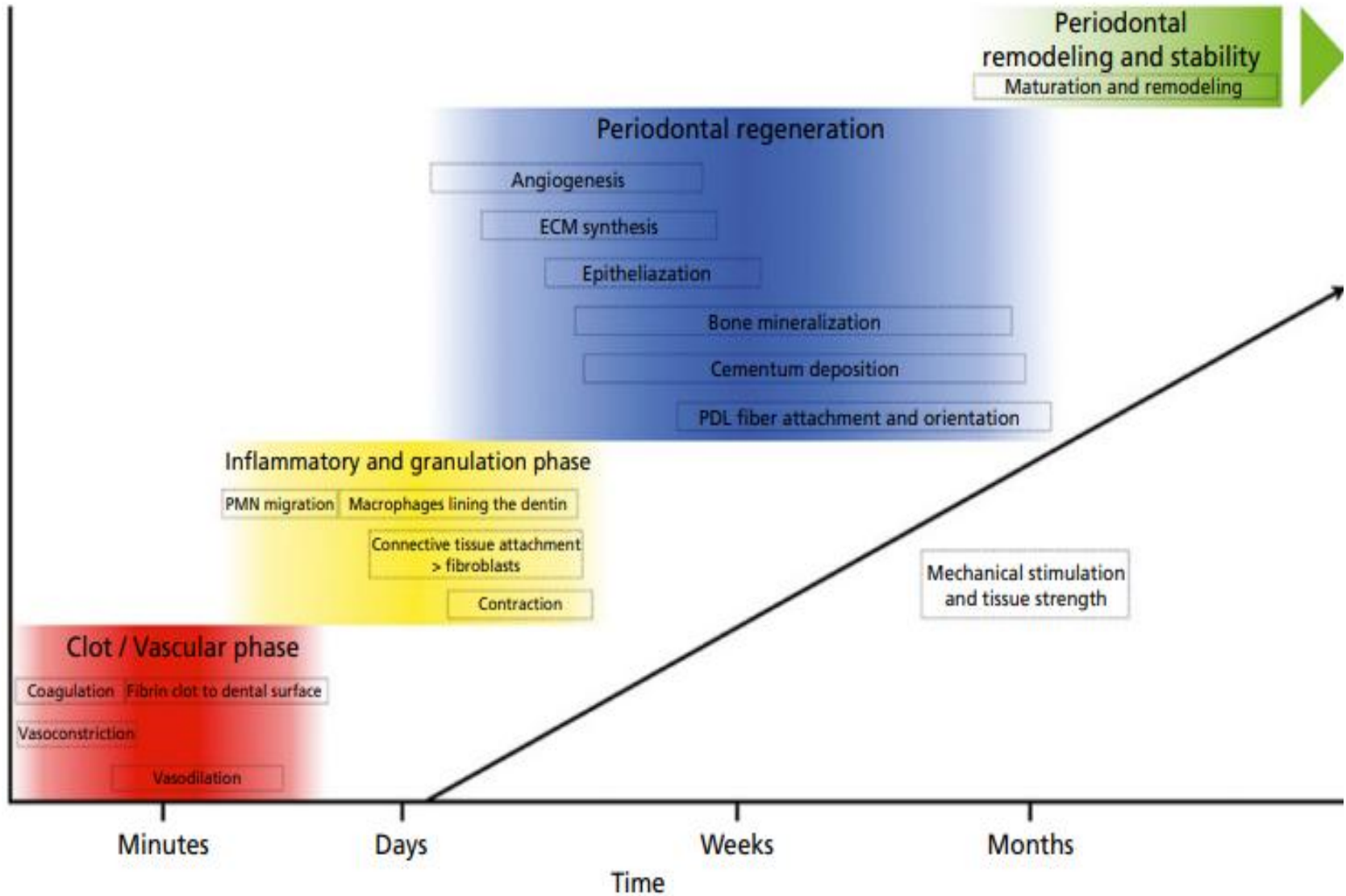


Table 21-1 Healing patterns in the **periodontal** tissues.

Healing by first intention

Healing through primary intention involves the wound edges being brought together using sutures. Primary intention wounds are associated with minimal tissue loss and **regeneration** predominates over fibrosis

Healing by second intention

Wound healing by secondary intention occurs in surgical wounds that are left to heal without approximating the edges. The wound then fills with granulation tissue from the bottom up. The epithelium then fills in over the top of the granulation tissue. Scarring is evident as there is significant fibrosis

Healing by third intention

Where there is great loss of tissue, the wound must heal by contraction of the wound edges and the formation of granulation tissue. In some cases, the presence of a foreign body or infection may be suspected, and these wounds are left open deliberately for several days until the potential complication has resolved. When resolution has occurred, the wound edges can be brought together (approximated) and the wound proceeds to heal

Partial-thickness healing

Occurs when a partial-thickness wound is closed primarily by epithelialization. This wound healing involves the superficial portion of the dermis (lamina propria). There is minimal collagen deposition and an absence of wound contraction

Table 21-2 Outcomes of periodontal wound healing.

Repair	Healing of a wound by tissue that does not fully restore the architecture or the function of the part. Within the periodontal wound, it refers to restoration of a normal gingival sulcus at the same level as the base of the previous pathologic periodontal pocket. Often repair is typified by the presence of a long junctional epithelium
Reattachment	Refers to the reattachment of the gingiva to areas from which it was mechanically removed
New attachment	Occurs when newly generated fibers are embedded in new cementum on a portion of the root that was uncovered by disease
Regeneration	Reproduction or reconstruction of a lost or injured part in such a way that the architecture and function of the lost or injured tissues are completely restored. This takes place by growing precursor cells replacing lost tissue
Resorption	Loss or blunting of some portion of a root, sometimes idiopathic, but also associated with orthodontic tooth movement, inflammation, trauma, endocrine disorders, and neoplasia
Ankylosis	Fusion of the tooth and the alveolar bone

Procedures specially designed to restore those parts of the tooth-supporting apparatus which have been lost due to periodontitis.

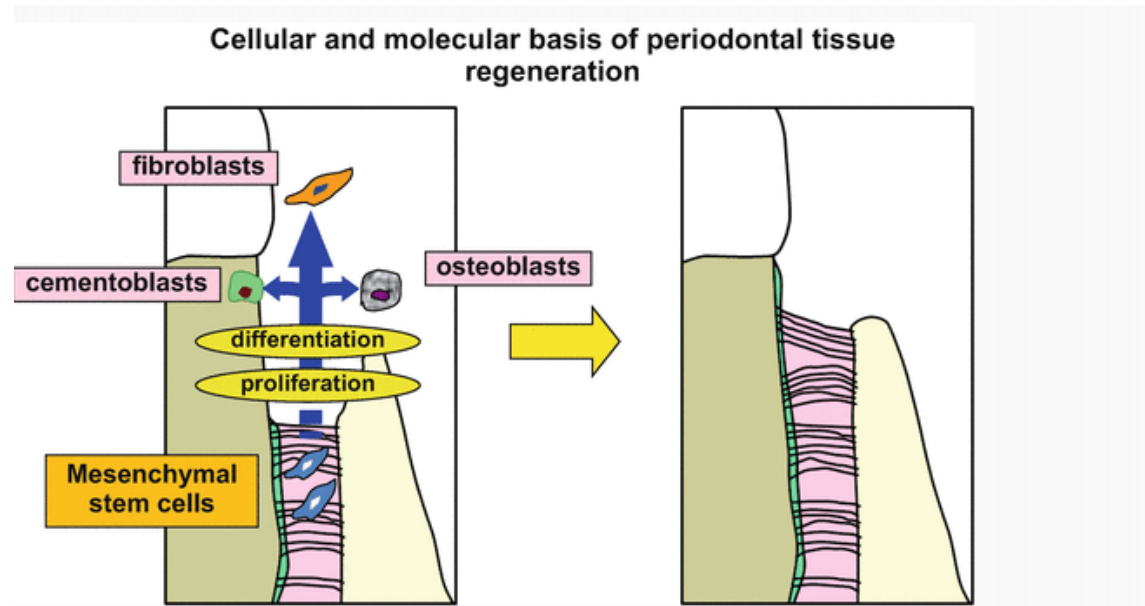


Fig. 12.1

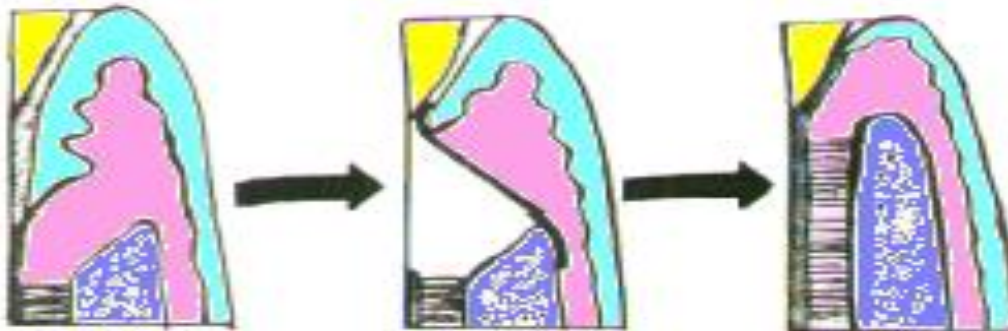
Cellular and molecular basis of periodontal tissue regeneration. Periodontal tissue stem cells, including undifferentiated mesenchymal stem cells, are present in the periodontal ligament, and regeneration of periodontal tissue can be achieved by activating these cells to proliferate, migrate, and site specifically differentiate at the site of periodontal tissue loss

Some definitions ..

REGENERATION

Reproduction or reconstruction of a lost or injured part in such a way that the architecture and function of the lost or injured tissues are completely restored.

- New cementum with inserting and functionally orientated ligament fibers
- Alveolar bone
- Gingiva



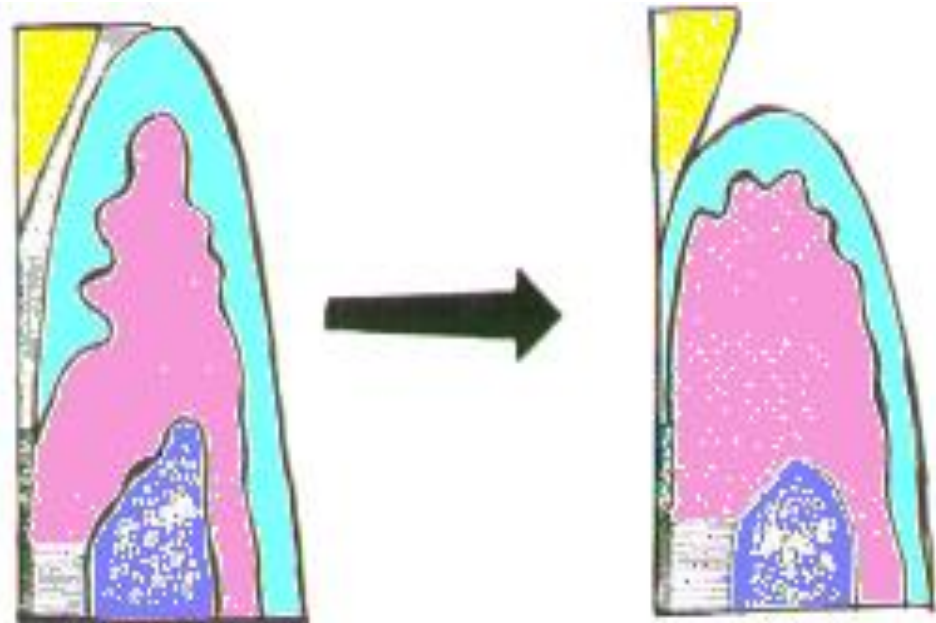
Repair

Healing of injuries without the complete restoration of structure or function of a part.

Long junctional epithelium
(satisfactory healing result)

Root resorption- unsatisfactory

Ankylosis- unsatisfactory




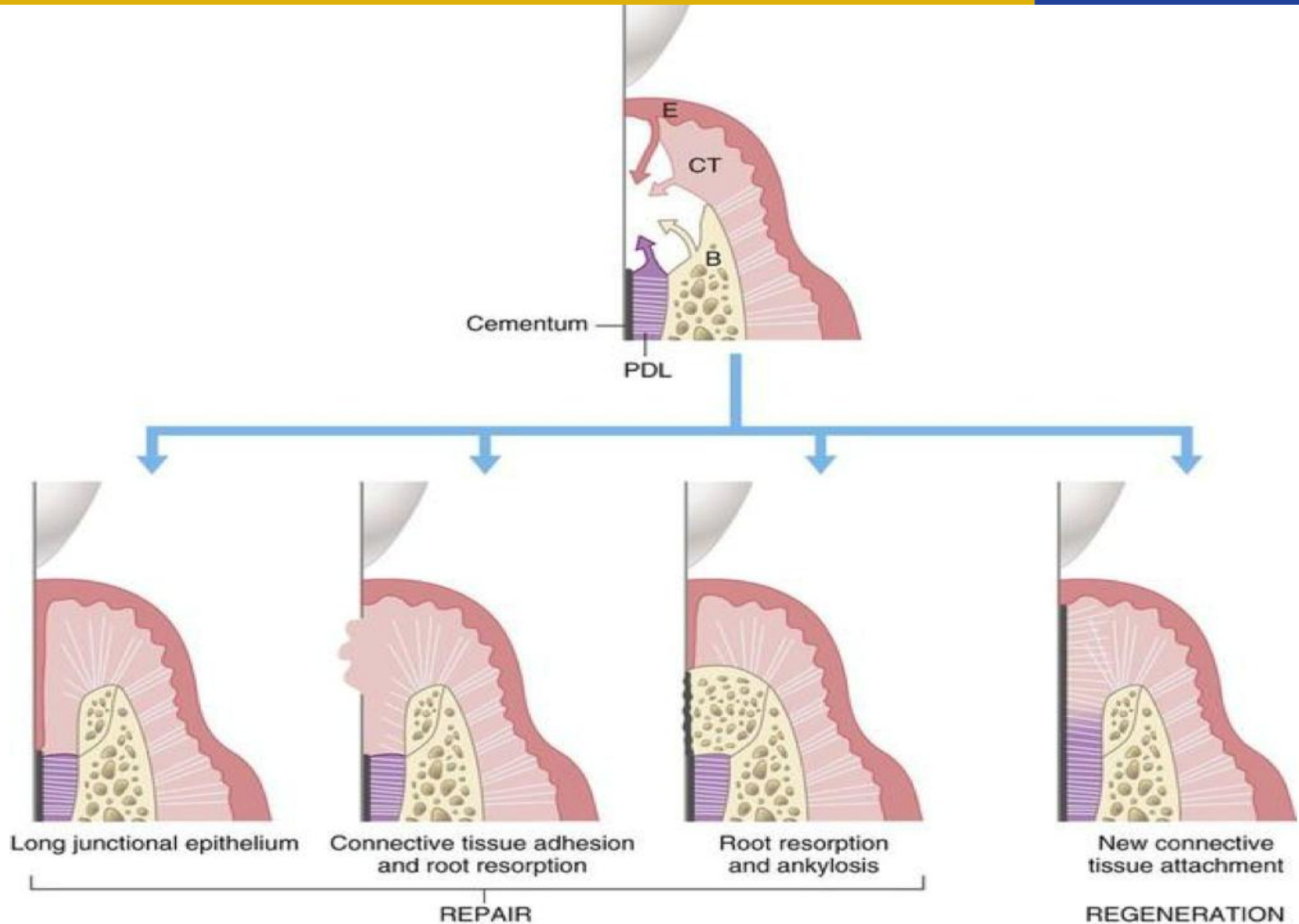
Healing dynamics of periodontal tissues

“**The type of cell** which repopulates the root surface after periodontal surgery **determines the nature of the healing** that will occur.”

- 1) Epithelium
 - 2) Cells derived from the gingival connective tissue
 - 3) Cells derived from the alveolar bone
 - 4) Cells derived from the periodontal ligament
- Different embryonic origin
 - Different rates of proliferation

Melcher, 1976





Healing outcomes after periodontal therapy and surgery



1) Epithelium usually wins the race-if epithelium repopulates the wound, a long junctional epithelium formed

Primary function is wound coverage and protection against microbes

Fastest tissue to proliferate , populates the root first, prevents other cell types from populating the root ,heals within weeks

To stop epithelium from proliferating, we place GTR (guided tissue membrane, which prevents epithelial proliferation)

Ectodermal origin

Healing outcomes

2) Cells derived from the gingival connective tissue

Mesodermal origin

Second fastest tissue



Connective tissue adhesions, reduction in tissue volume & recession
Root resorption

3) Cells derived from the alveolar bone

Mesodermal origin



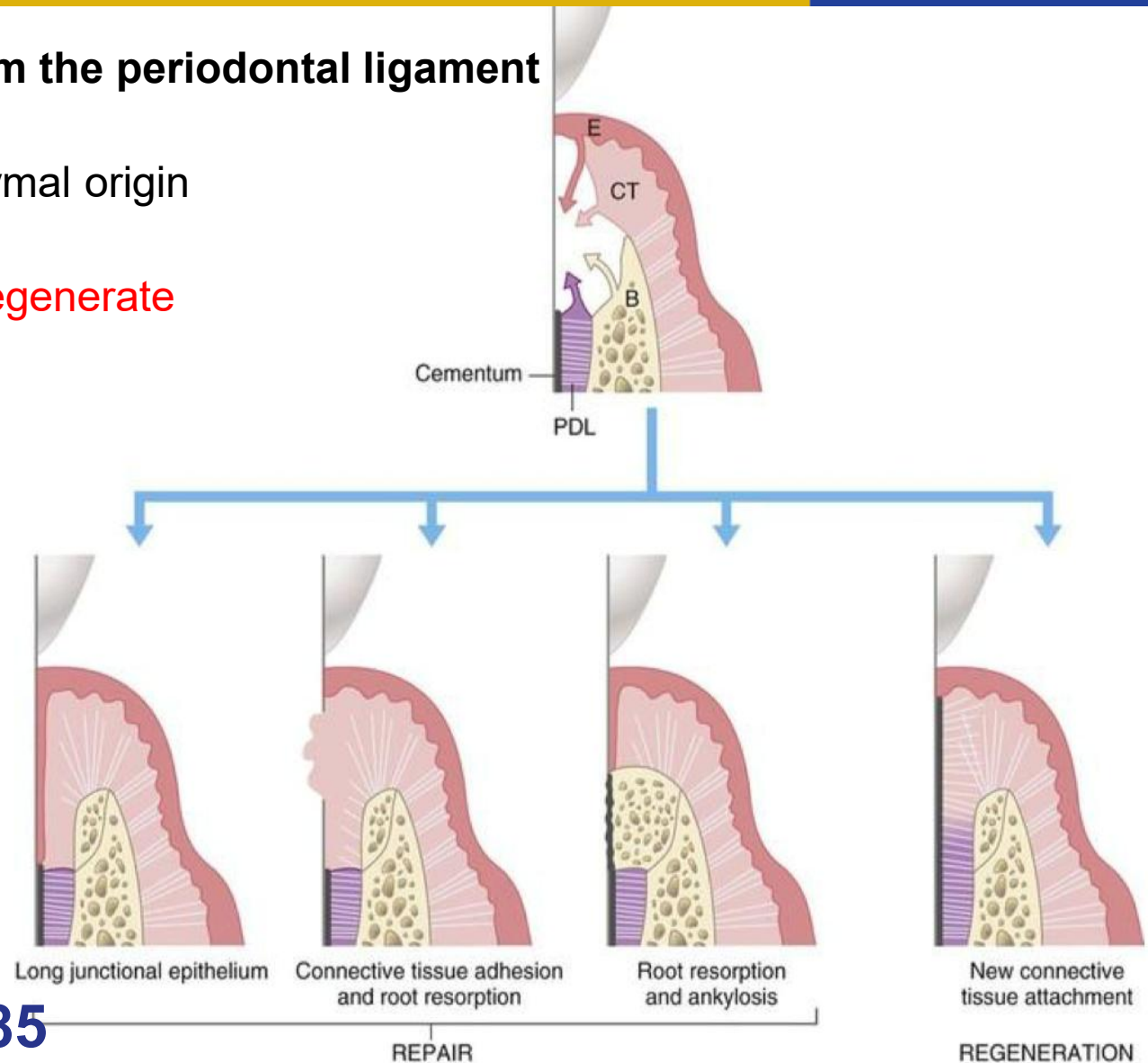
Ankylosis
Resorption

Healing outcomes

4) Cells derived from the periodontal ligament

Same ectomesenchymal origin

Only tissue able to regenerate



Karring et al 1985

Epithelium exclusion

Gingival CT exclusion

Wound stability

Space-provision

Primary intention healing

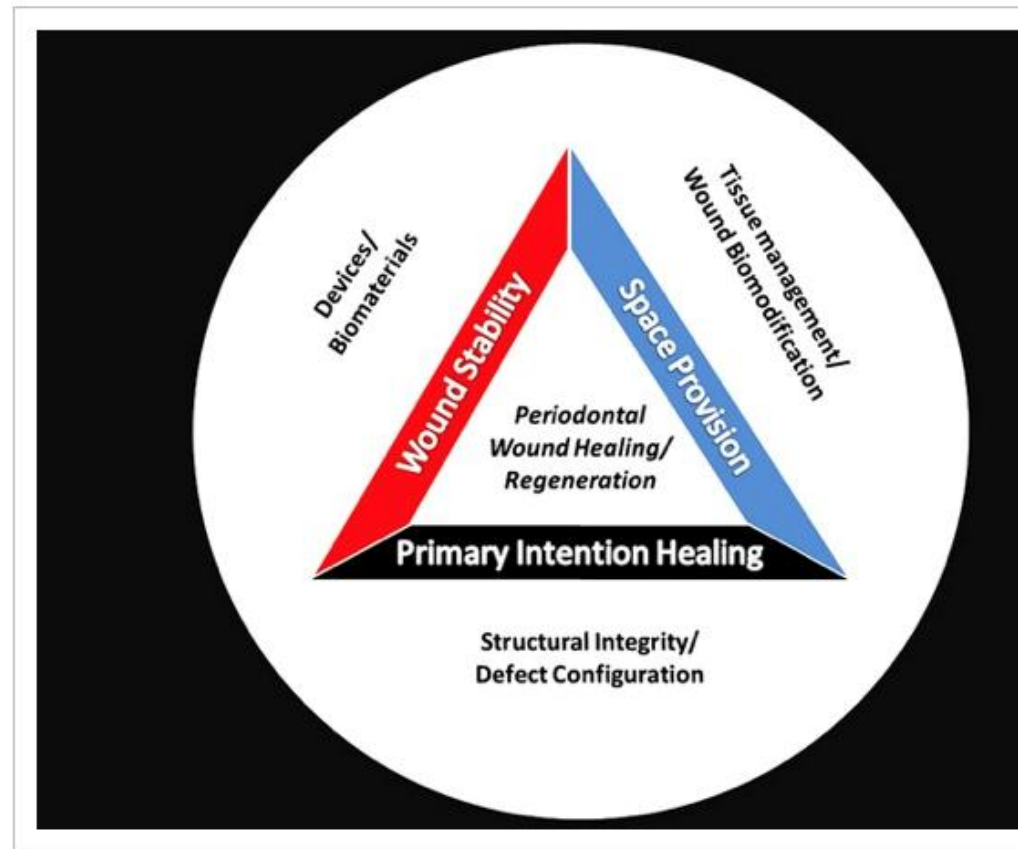


Figure 1

[Open in figure viewer](#) | [Pow](#)

Bioclinical principles for periodontal wound healing/regeneration.

Factors affecting regeneration potential

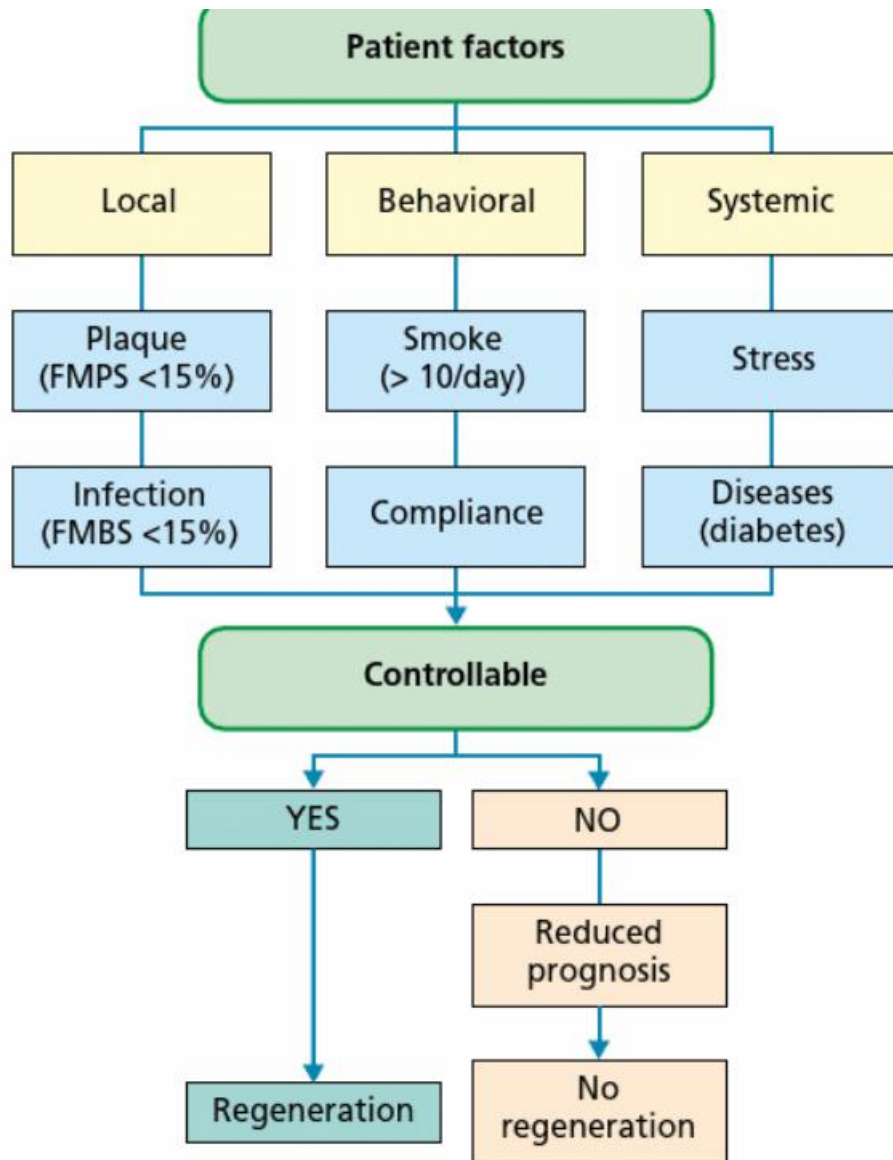


Patient factors

Defect factors

Tooth factors-restorability , mobility

Surgical factors

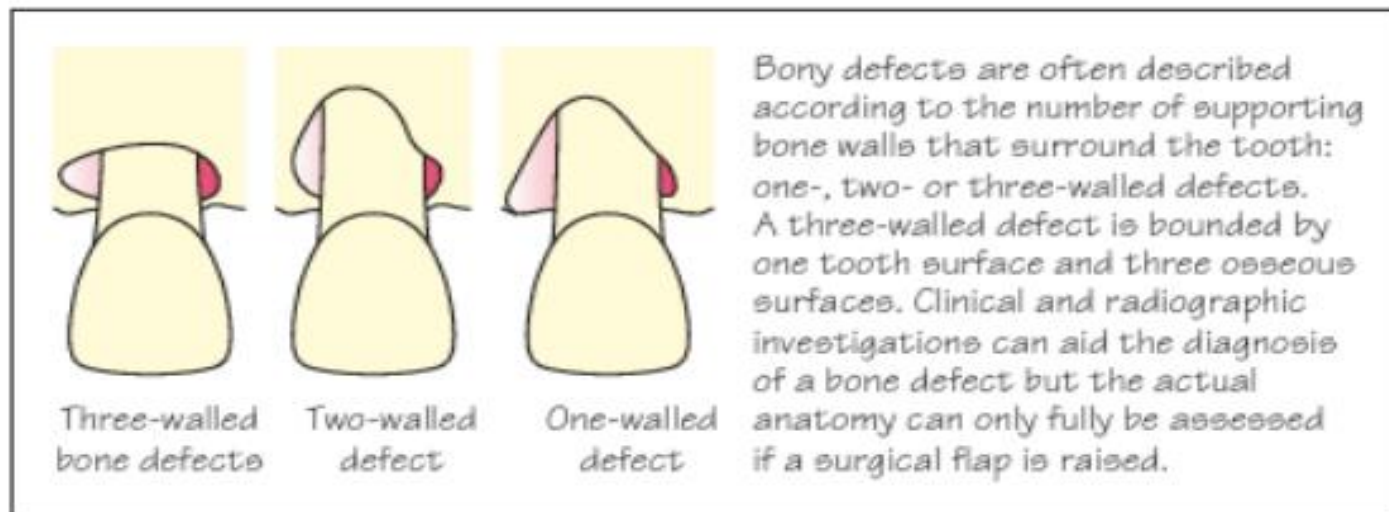


Defect factors

Bony defect size (**ideally 3/4 walls**) , depth (min 3mm),
width(narrow)

Surrounding soft tissue (sufficient, thick, keratinized)

- Accessibility



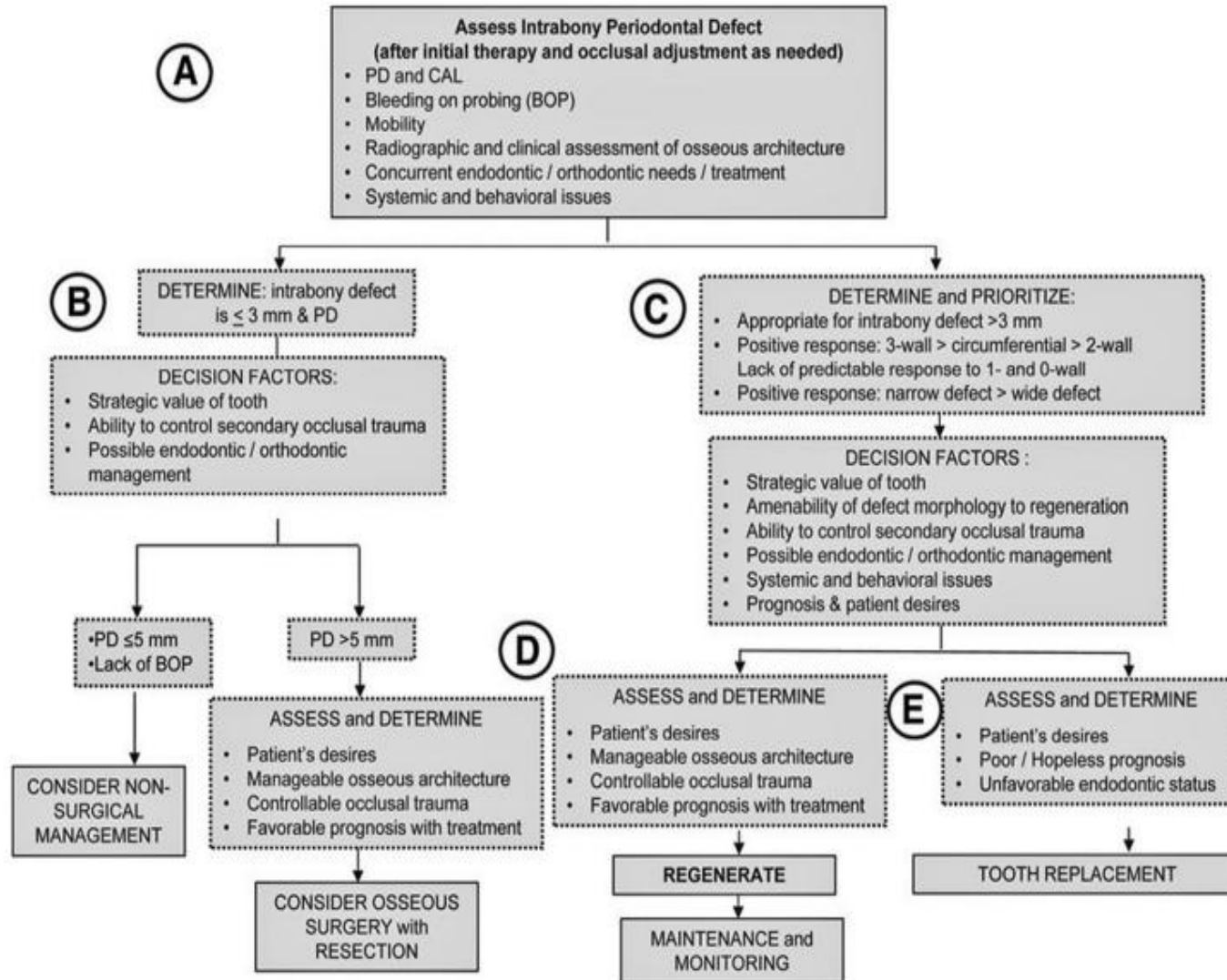


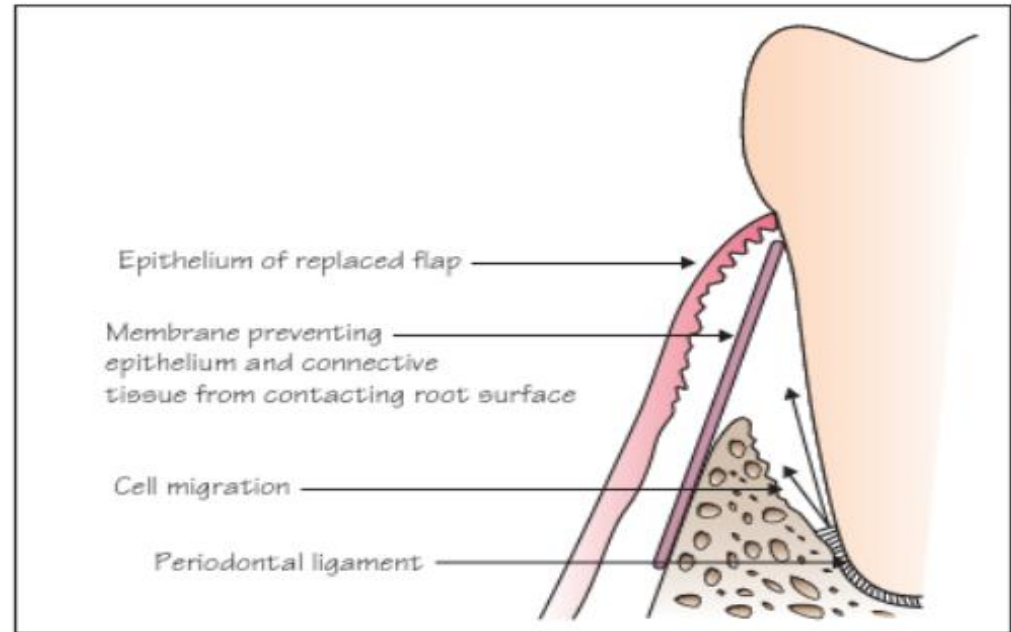
Fig. 63.4 Clinical decision tree for the management of advanced periodontal defects. A to E are explained in the text in the section titled "Clinical Guidelines to Guide Clinicians in Their Patient Management." CAL, Clinical attachment level; PD, periodontal defect. (From American Academy of Periodontology: J Periodontol 86[Suppl]:S77, 2015.)

Surgical factors

Wound coverage
Surgical technique
Space maintenance

Blood supply

Clot stabilization



How to promote regeneration clinically



Physical

1. Bone grafts
2. Barrier devices or membranes for guided tissue regeneration – GTR
- 3- 3D printed scaffolds

Biochemical

- . Extracellular matrix and growth factors-still experimental
- . Enamel matrix proteins (Emdogain)

Clinically some cases appear successful but histologically epithelial lining may be seen against bone instead of new cementum and bone

1. Bone grafts

Bone loss



Attempt to correct bony defects



Attempt to “regenerate”

Autogenous bone- same patient

Bone derivatives

Allogenic –same species(another human)

Xenogenic- different species(bovine, equine, porcine)

Bone substitutes

synthetic biomaterials

Limited if any evidence of histological regeneration if no membrane is used to exclude epithelium/CT

Act as a “biological obturation/filling” of the defect

eTABLE 63.1 Commercially Available Scaffold Materials Potentially Available for Oral Tissue Engineering Application

Biomaterials	Commercial Names
Allografts	
Demineralized freeze-dried bone allograft (DFDBA)	Distributed under various names by tissue banks
Freeze-dried bone allograft (FDBA)	Distributed under various names by tissue banks
Xenografts	
Anorganic bovine bone	Bio-Oss, OsteoGraf, Pep-Gen P-15
Hydroxyapatite (HA)	
Alloplasts	
Tricalcium phosphate	Synthograft
Hydroxyapatite	Periograf, Osteogen, ProOsteone
Bioactive glass polymers	PerioGlas, BioGran
Hard tissue replacement polymer	Bioplant
Coralline calcium carbonate	Biocoral
Polymers and Collagens	
Collagen	CollaPlug, CollaCote, Gelfoam, Helistat
Poly(lactide-co-polyglycolide)	
Methylcellulose	
Hyaluronic acid ester	HY
Chitosan	

2. Barrier devices or membranes

Placement of a physical barrier to exclude epithelium and connective tissue, allowing the repopulation of the wound by progenitor cells.

- **Non-resorbable**
- **Resorbable**

Limited clinical results due to:

Technique sensitivity (even microsurgical/modified approaches)

Instability

Infection

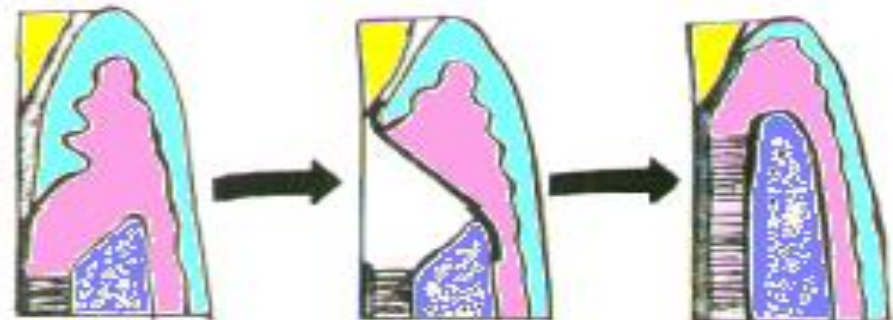
Recession

Membrane collapsing

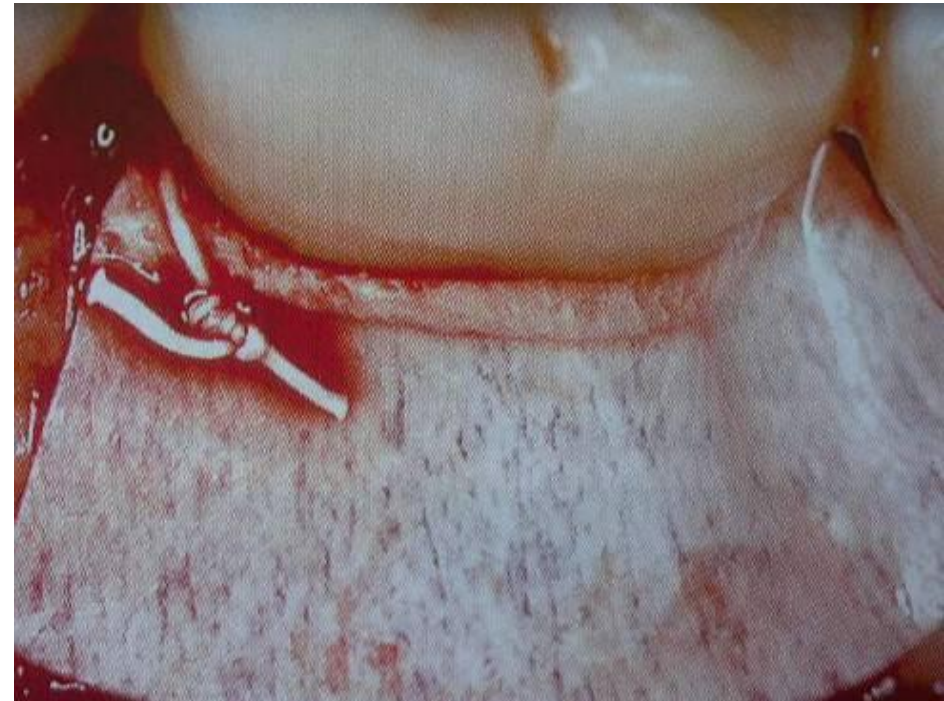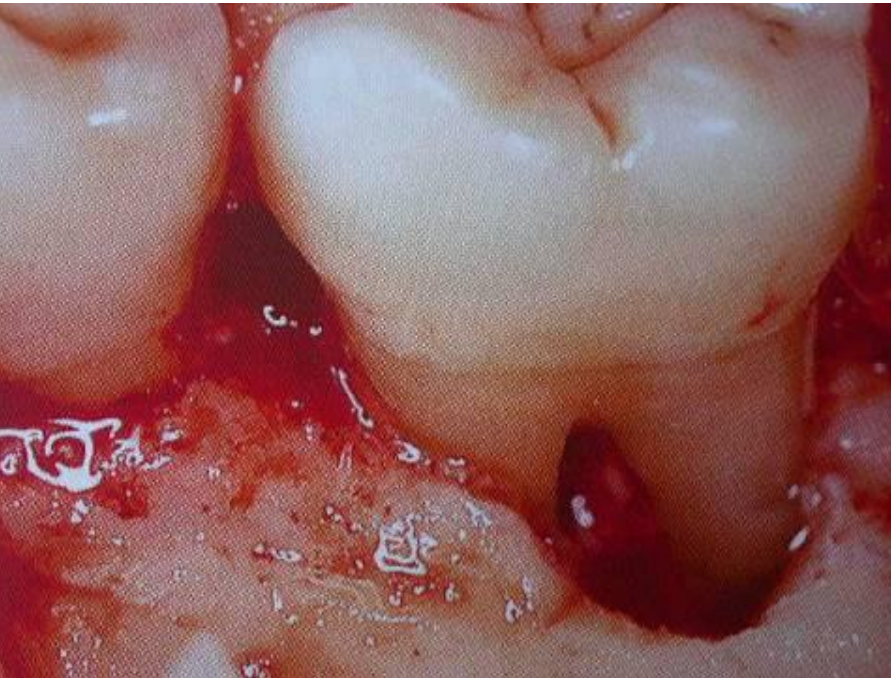
Patient factors-biofilm control, smoking

Nyman et al 1982 a, b

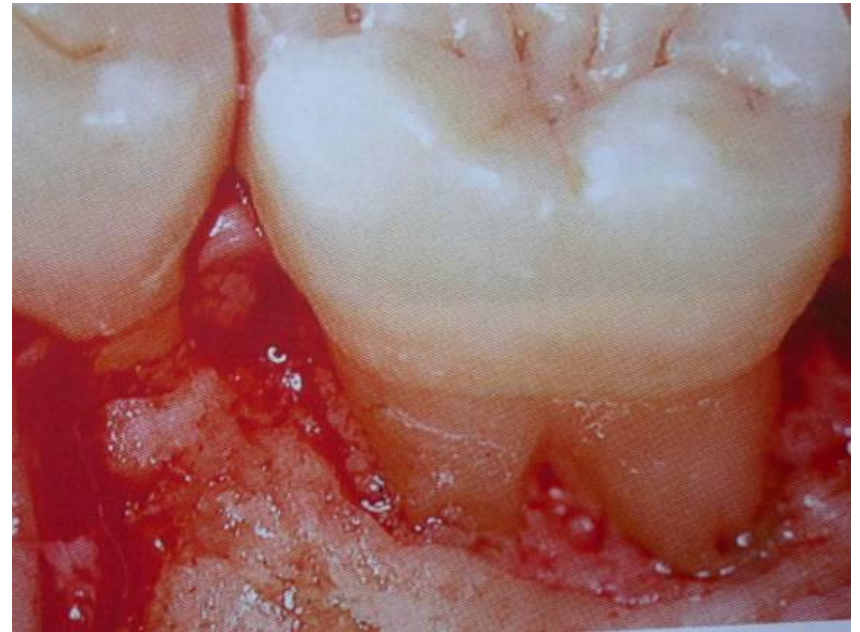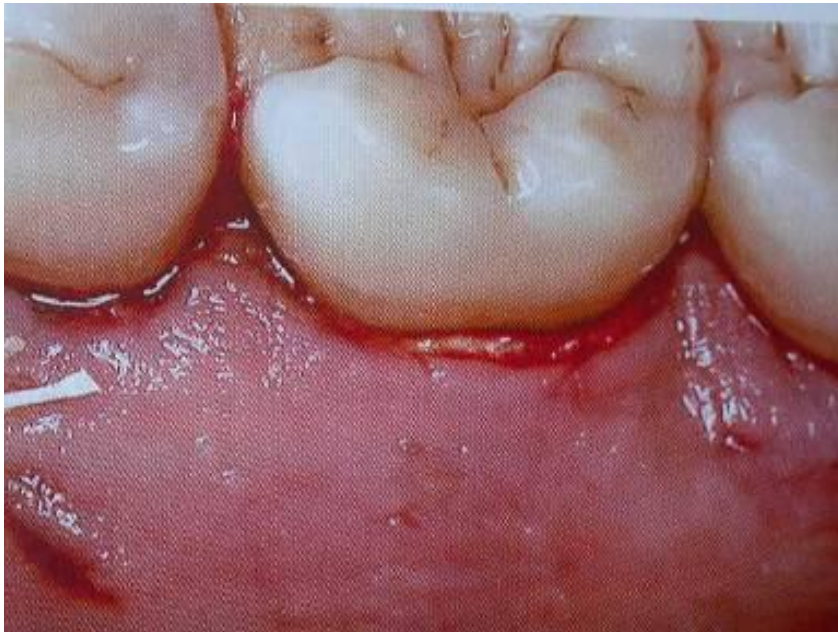Susin et al 2015

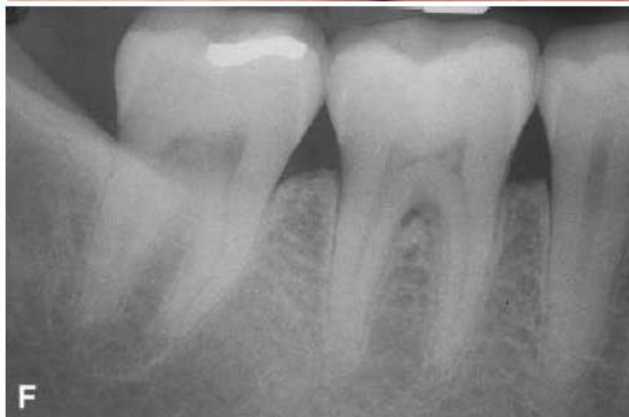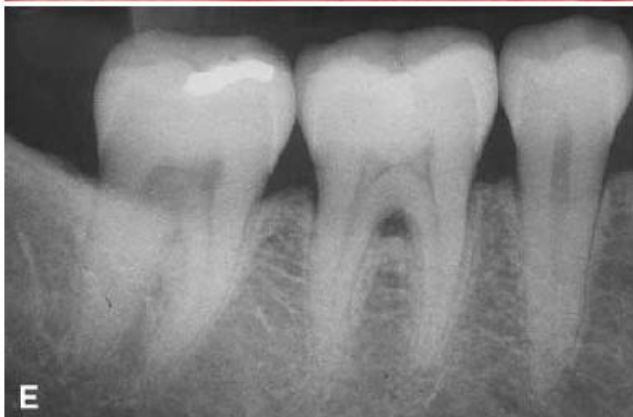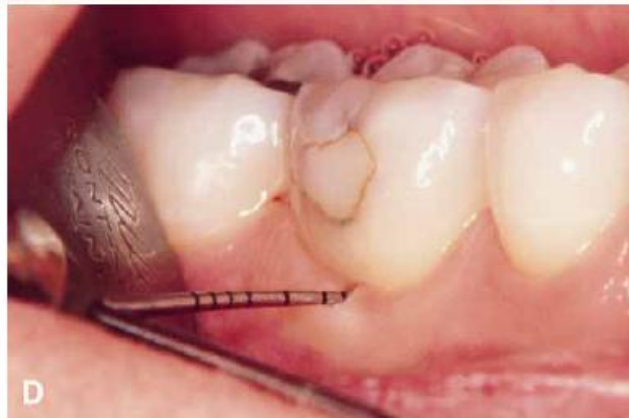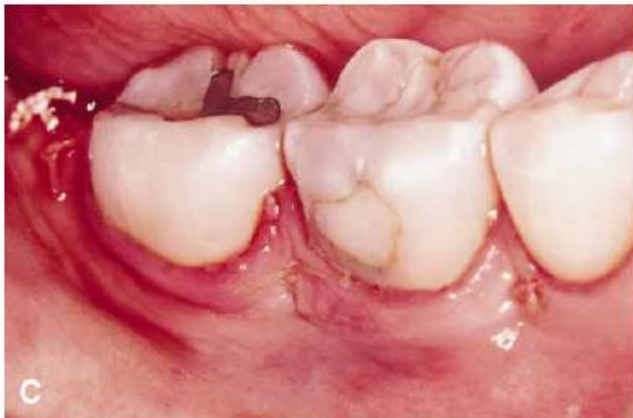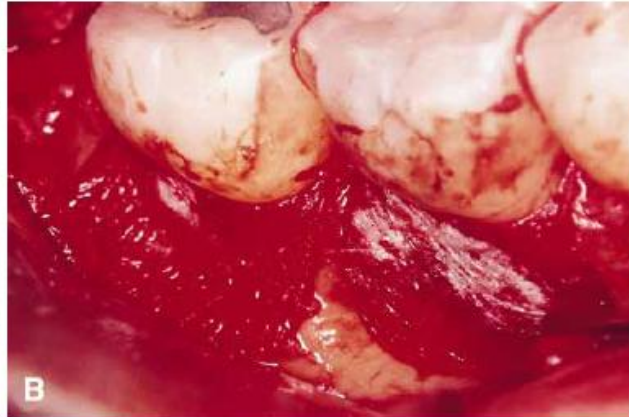


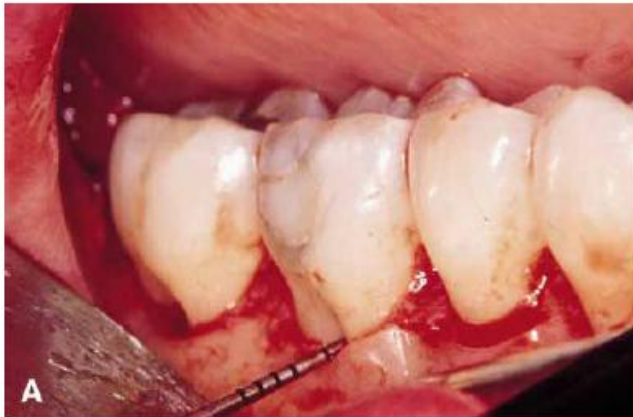Degree II furcation defect



1. repair defect
2. membrane
3. flap





Guided Tissue Regeneration Membranes

Nonresorbable Membranes


In classic animal and human studies demonstrating the efficacy of GTR, cellulose acetate filters were used. As this technique became more prevalent, the first commercial membrane was produced from expanded PTFE (ePTFE). This membrane has all the properties necessary for GTR barriers in that it (1) is a cellular barrier, (2) is biocompatible, (3) provides space for the healing tissue, (4) permits tissue integration, and (5) is clinically manageable (eFig. 63.10). Much of our current understanding of GTR is based on studies using ePTFE membranes. Although these membranes are used less frequently now, they are still popular for **guided bone regeneration** and ridge preservation, so it is important to understand the clinical procedures for managing these membranes.

Bioresorbable Membranes


Bioresorbable membranes have replaced the routine use of ePTFE membranes in GTR. There are three types of bioresorbable membranes: (1) polyglycoside synthetic polymers (i.e., polylactic acid, polylactate-polygalactate copolymers), (2) collagen, and (3) calcium sulfate. Polyglycoside membranes degrade as the result of random nonenzymatic cleavage of the polymer, to produce polylactide and polyglycolide, which are converted to lactic acid and pyruvate, respectively, and metabolized by the **enzymes** of the Krebs cycle. Porcine collagen membranes are degraded by **collagenases** and subsequently by gelatinases and peptidase. A resurgence has occurred in the use

Intrabony defects

Regeneration more reliable in 3 wall compared to 1 wall defects



1 Wall Defect

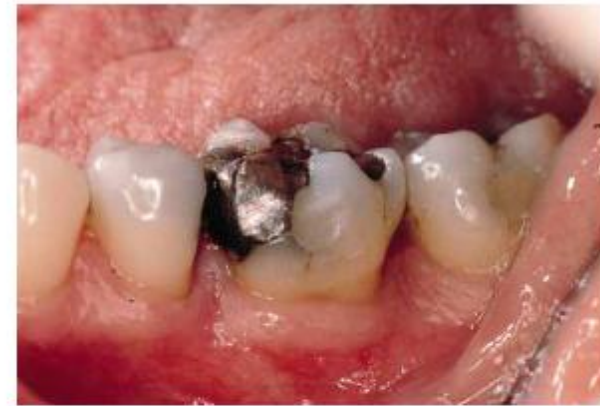
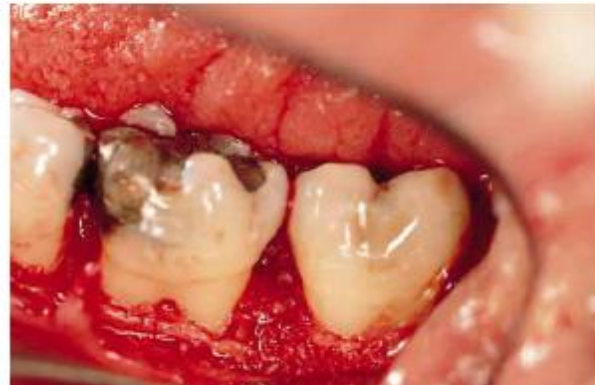
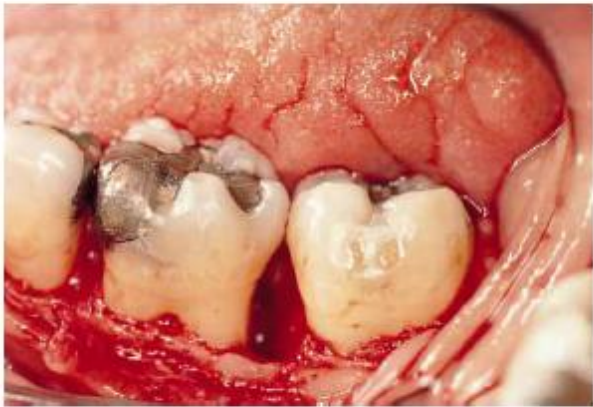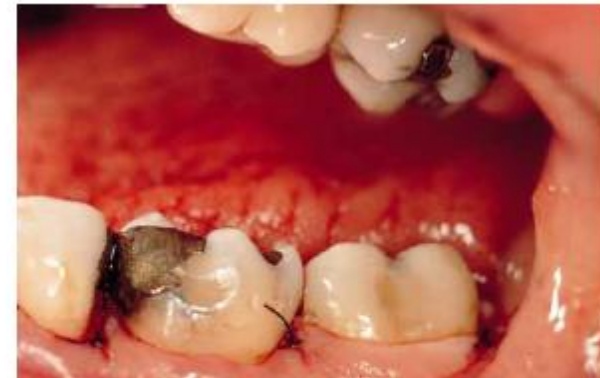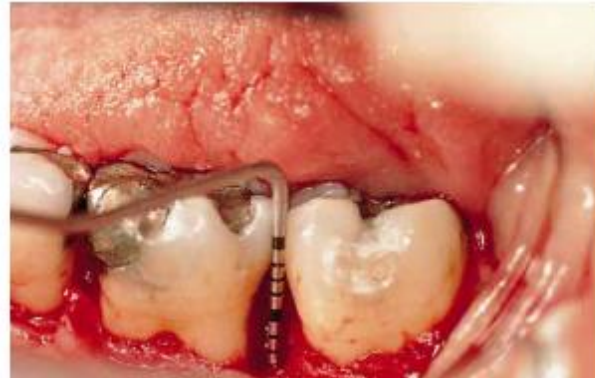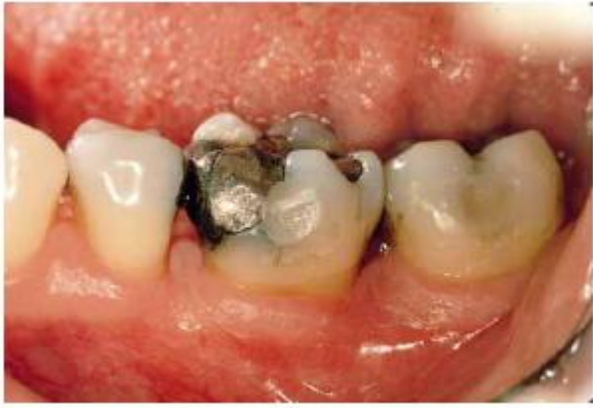2 Wall Defect



3 Wall Defect

Wound stability and space provision key to success



4. Enamel matrix derivatives

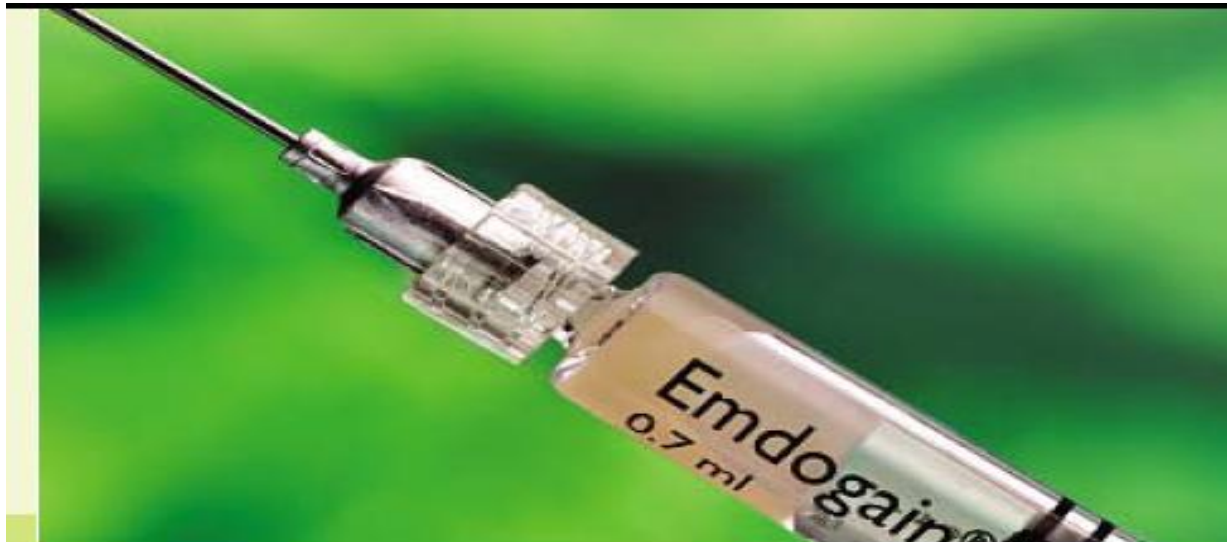Enamel matrix proteins active during periodontal embryonic formation

EMDOGAIN – porcine enamel matrix proteins, mostly amelogenin, commercially available- has been shown to affect wound closure, reduce inflammation and increase predictability of healing outcome.

Less technique sensitive than membranes plus less complications.

Increasingly used with minimal surgical procedures ideally.

Can be combined with bone grafts



Clinical indications for EMD in periodontal surgery

Intrabony defects

Class II furcation

Recession defects

Horizontal bone loss

Angular bony defects

Maxilla

Mandible

Thick biotype

Thin biotype

Conventional periodontal flap surgery
Conservative or resective approach

Self-contained defects
EMD or GTR either used alone or combined with a bone graft

Non-self-contained defects
EMD or GTR combined with a bone graft

Buccal
EMD or GTR

Mesial
EMD

Distal
Root resection or flap surgery with EMD

EMD or GTR either alone or in combination with a bone graft (in buccal defects) or respective approach

Coronally advanced flap + EMD

Coronally advanced flap + EMD + connective tissue graft

or

Tunnel technique + EMD + connective tissue graft



Figure 8. An example range of microsurgical instruments.

Straumann® Emdogain® FL
Cultivating flapless
periodontal regeneration



Figure 9. Emdogain FL delivery system. Courtesy of Straumann.

- **Non-surgical use?**

Indications	Contraindications
Adjunct to non-surgical periodontal therapy (initial phase of therapy)	Uncontrolled diabetes or other systemic diseases that impact healing potential
Pockets $\leq 5\text{mm}$	Chronic high-dose steroid therapy
Implants	Metabolic bone disease
Support wound healing	Radiation or other immunosuppressive therapies
Good oral hygiene	Infection or vascular impairment at the site
Minimally Invasive	Porcine origin
Avoid surgical procedures	Allergies to constituents
	Smoker

Table 1. Indications and contraindications for the use of Emdogain Flapless. The list is not exhaustive and manufacturer's guidance should be followed accurately. Adapted from the product instruction manual (available at: <https://tinyurl.com/ye8y28ua>).

		Before Emdogain	
1.	Root debride and scale	Removal of biofilm and plaque	
2.	Root conditioning	Application of PreGel. Pressure and gel dislodges blood from pocket. Leave 2 mins.	
3.	Rinse	Saline/ultrasonic waterjet	
4.	Haemostasis	Can be facilitated by floss packing into the pocket	
5.	Emdogain FL application	Pocket base upwards until excess seen	
6.	Post-operative instructions	Oral health instructions to include interdental brushing. Recall at 2-3-monthly intervals	

Table 2. Step-by-step guide for Emdogain Flapless.¹³ Adapted from the product instruction manual

Cell and Gene therapy, 3D scaffolds

- In soft tissue grafts- **cell therapy** (autogenous fibroblast , autogenous keratinocytes placed in alloderm) currently used to replace tissue lost through trauma or craniofacial malignancies- these cells do not self-renew.
- Recently new commercial ways of producing /expanding autologous bone marrow derived stem cells shows promise in alveolar bone defects
- **Gene therapy**- potential for producing proteins/ growth factors that are more bioavailable but still very experimental
Gen21s is a growth factor which induces bone formation
- **3D printed scaffolds**- provides space and wound stability. , has the potential to guide the complex spatial and temporal interactions during periodontal wound healing- customized scaffold made of biodegradable polymer designed from a CT image of a bone defect used very successfully in a patient recently

Where we should consider regenerative therapies.



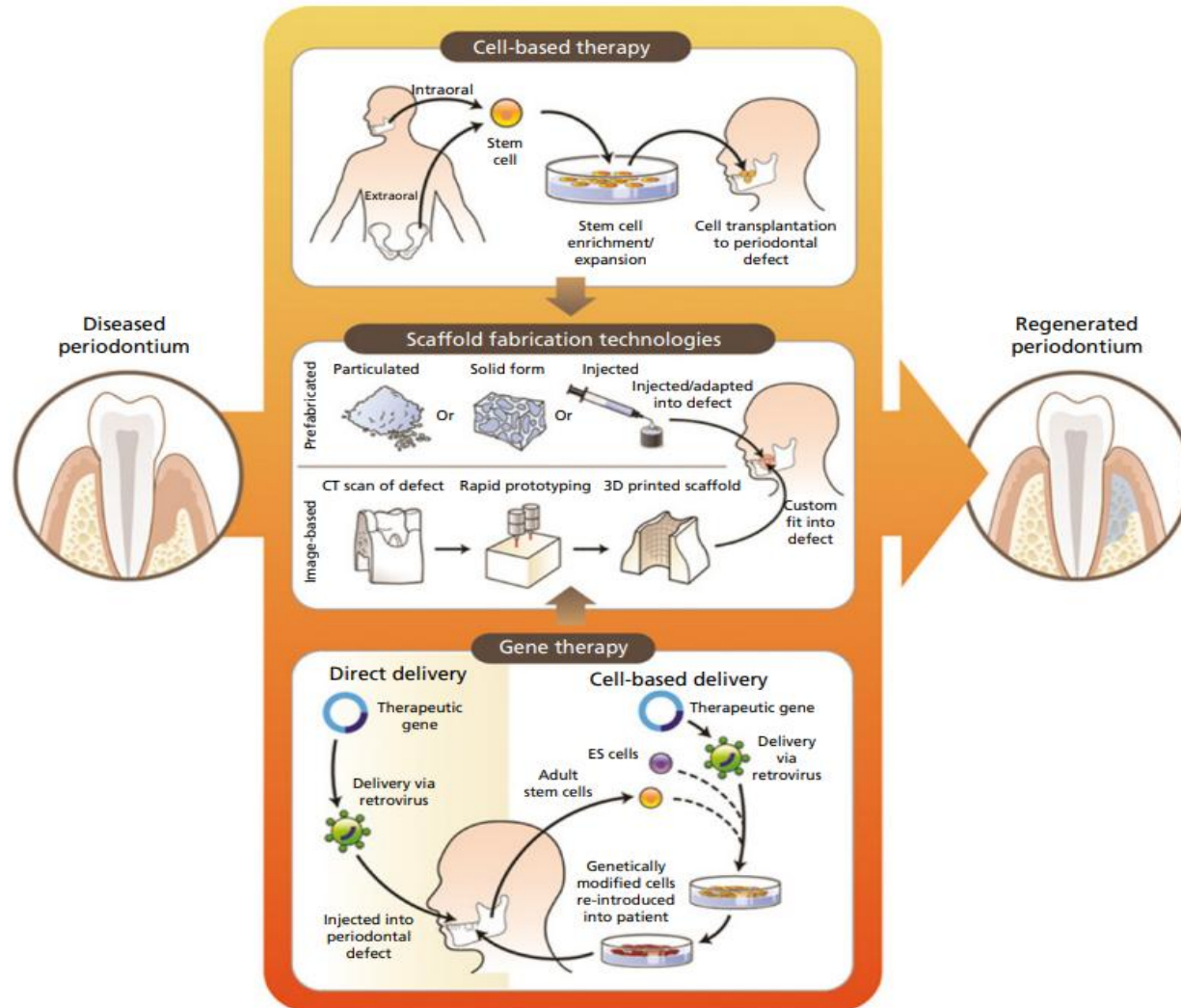
Furcation defects (mandibular molar, grade 2, buccal)

Intrabony defects(ideally 3 walled, greater than 3mm depth)

Recession defects

Bone regeneration in Implantology

New technologies in Tissue Regeneration



3. Extra Cellular Matrix and growth factors

Fibronectin, PDGF, IGF, TGFs, BMP-3

Significant results in animal models

Clinical efficacy thus far appears insufficient to warrant wider clinical use
Expensive

Other techniques;

Systemic PTH, sclerostin monoclonal antibody

Soft tissue grafts- cell therapy (autogenous fibroblast , autogenous keratinocytes placed in alloderm) currently used to replace tissue lost through trauma or craniofacial malignancies- these cells do not self-renew.

Recently new commercial ways of producing /expanding autologous bone marrow derived stem cells shows promise in alveolar bone defects

Healing assessment

Clinical parameters

Gain in attachment levels

Radiological examination

Gain in bone levels

Re-entry surgeries

Gain in bone levels



Histology

Only way to really detect regeneration!!

Ethical considerations, animal models, indirect evidence from case reports

Our lecture today...

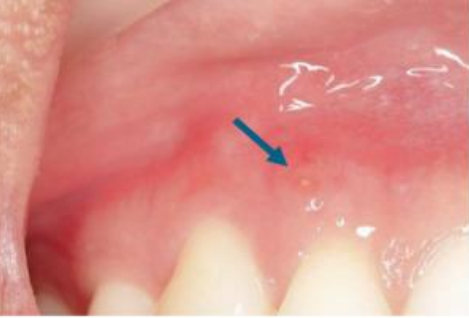Progenitor cells for reformation of lost periodontal attachment are only present in the periodontal ligament.

Periodontal regenerative procedures need to encourage repopulation of the wound with periodontal ligament cells.

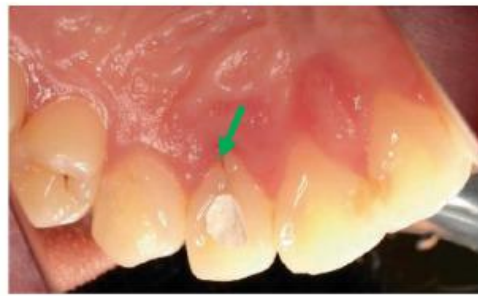Regenerative procedures include **GTR and Emdogain**.
Regeneration not guaranteed!

Bone grafts lack the ability to regenerate, they rather repair.

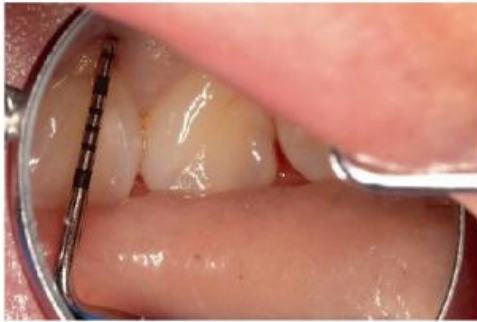Histology is the only way to detect true regeneration.



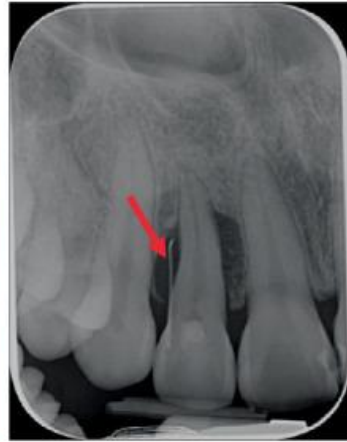(a)



(b)

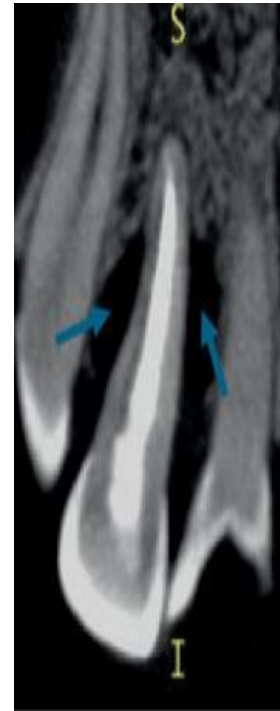

(c)

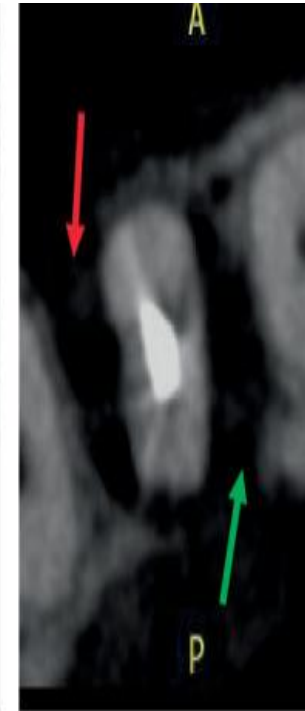


(d)

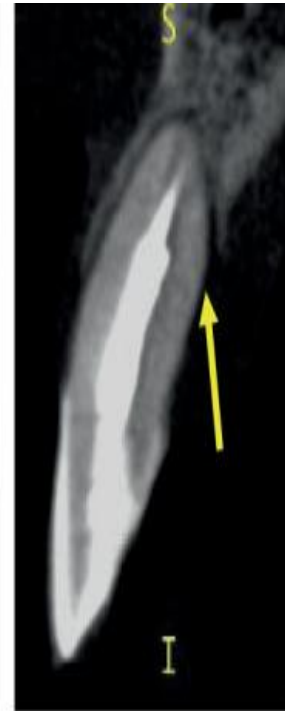Palatal root groove case:
- bone defect caused by a palatal root groove



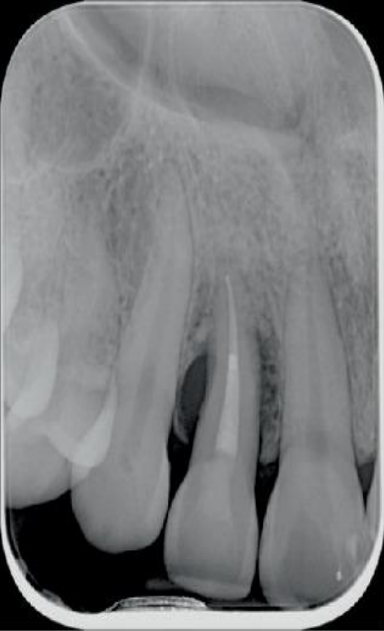(a)



(b)



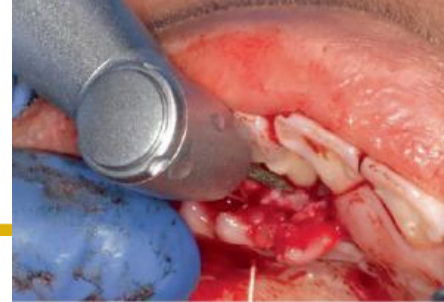(c)



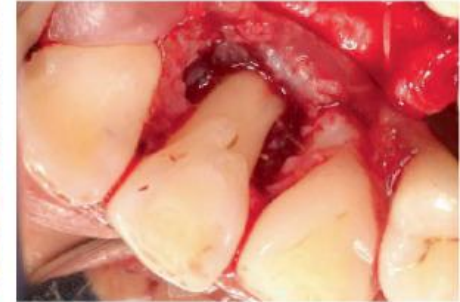(a)



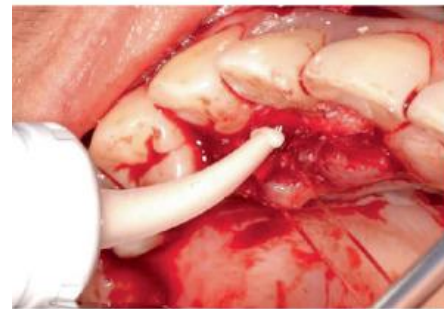
(b)



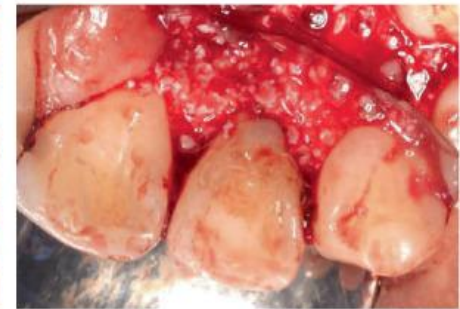(a)



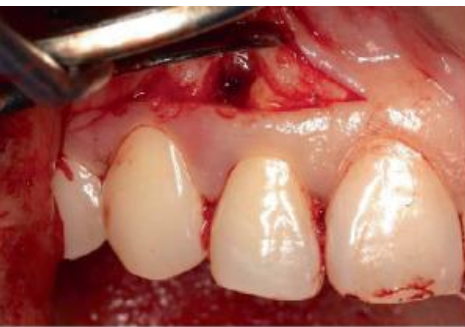(b)



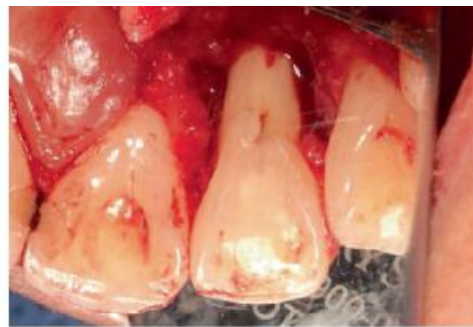(c)



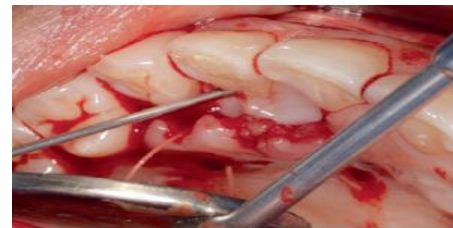
(d)



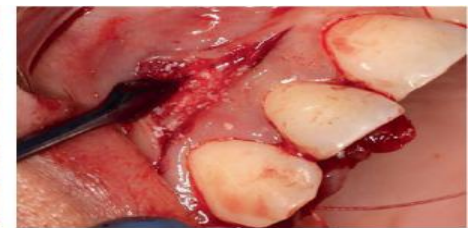(a)



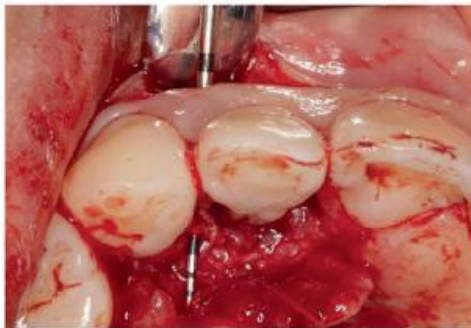(b)



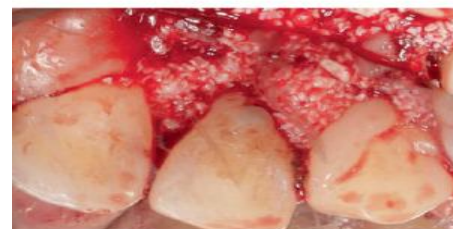
(a)



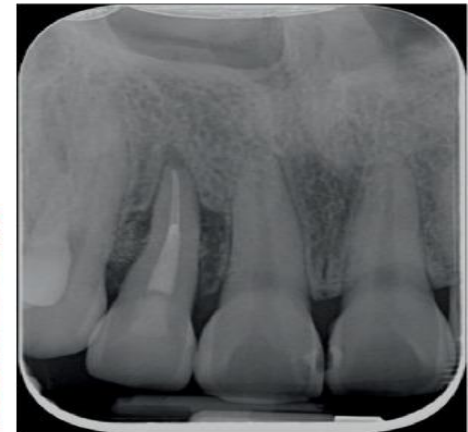(b)



(c)



(c)



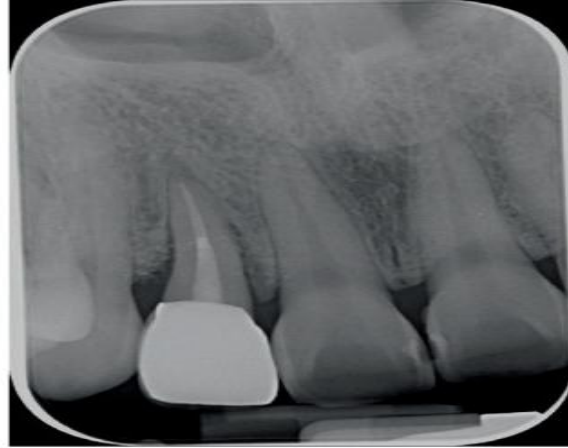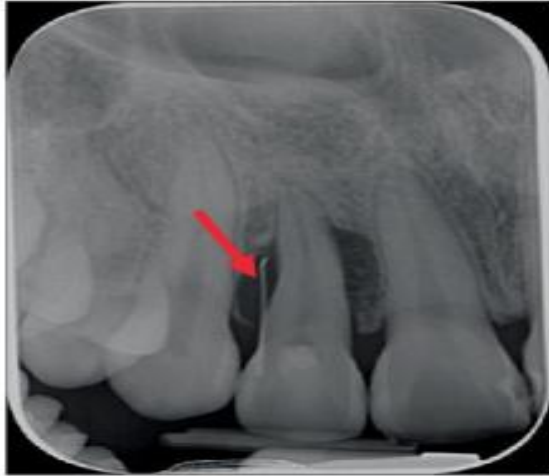(d)

Palatoradicular Groove–Associated Periodontic–Endodontic Lesion: A Multidisciplinary Case Report Utilising Minimal Access Papilla-Sparing Regenerative Technique (MAPSRT) and Dual-Flap Approach

Amelia Hemmati , Stephanie Chan, Mehdi Valizadeh, Robert Childs, Leticia Algarves Miranda , Paul Abbott , and Pradeep Koppolu 

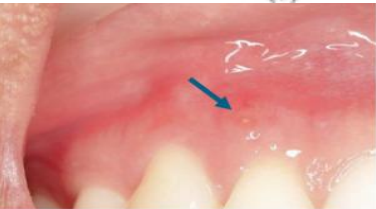UWA Dental School, The University of Western Australia, Perth, Australia

(b)

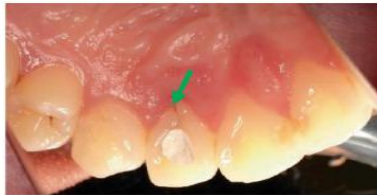

(b)

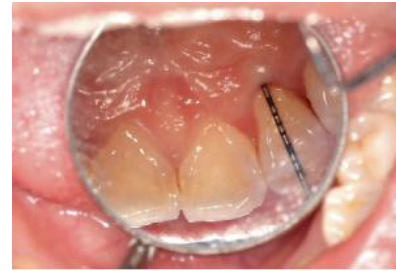(d)



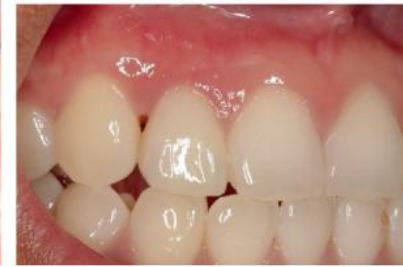(a)



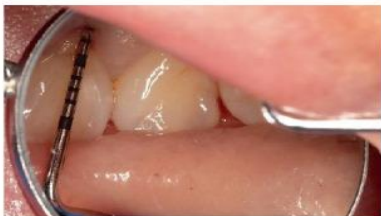(b)



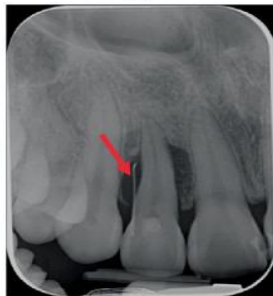(a)



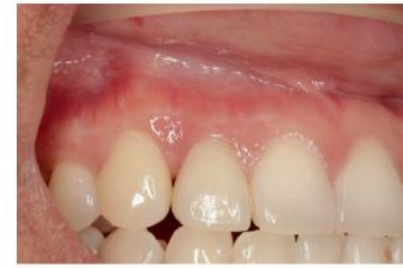(b)



(c)



(d)



(c)

Thank you!!!



THE UNIVERSITY OF
WESTERN
AUSTRALIA