



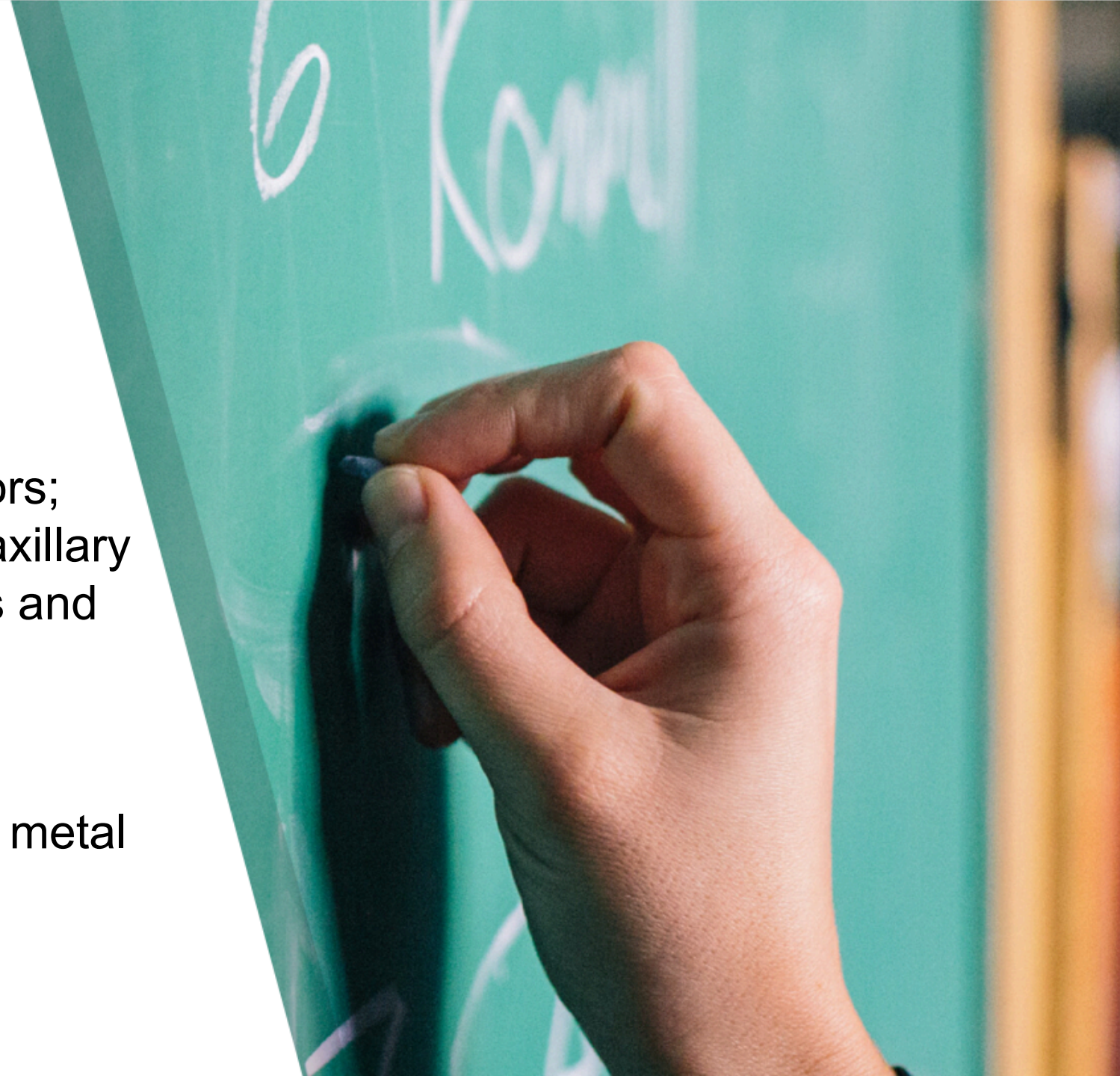Connectors

Major and Minor Connectors



LEARNING OUTCOMES

- Discuss the function and design considerations of Major Connectors;
- Describe the different types of Maxillary and Mandibular major connectors and their indications;
- Discuss the function of Minor connectors;
- Identify a minor connection in the metal framework.



Major Connectors



THE UNIVERSITY OF
**WESTERN
AUSTRALIA**

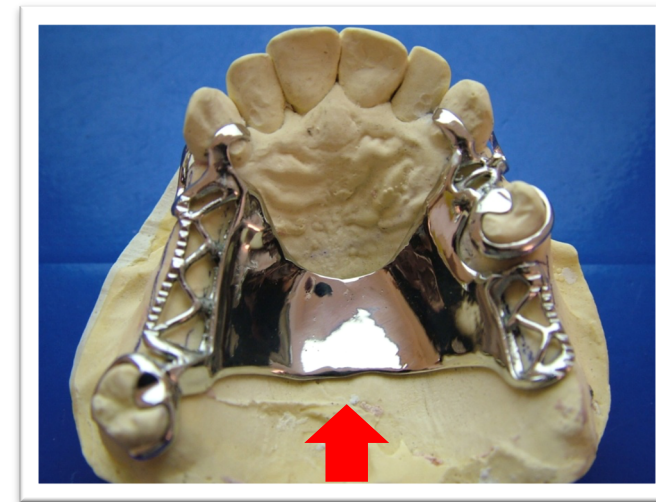
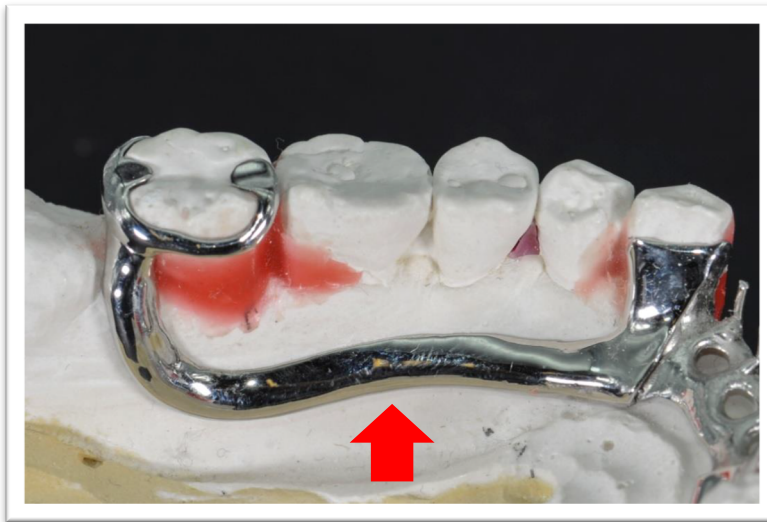

Oral Health Centre
of Western Australia

CONCEPT

Rigid structure that joins the components on one side of the arch with those on the opposite side

GPT-9, 2017

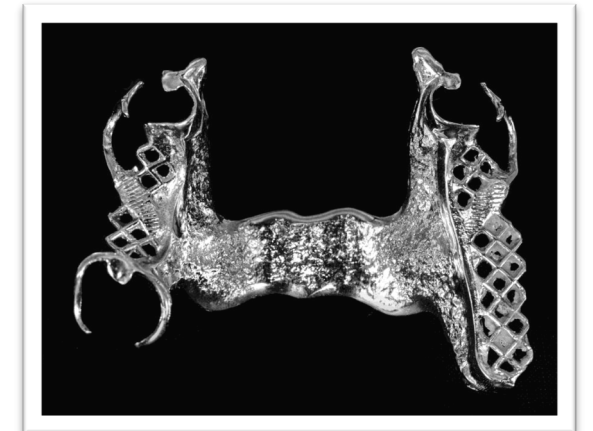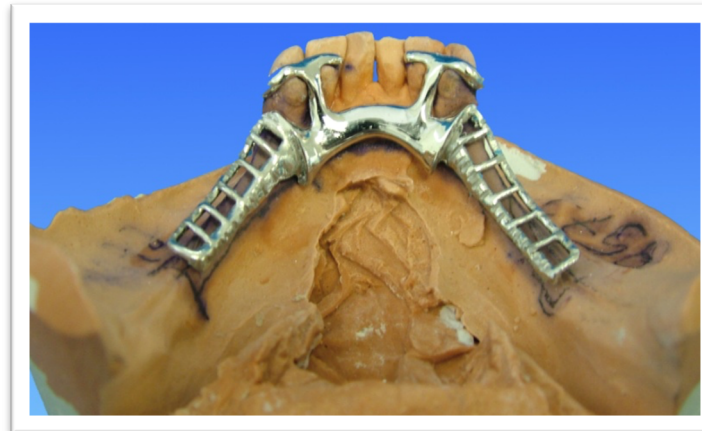


All other RPD components are directly or indirectly attached to it

Major Connectors

Function

- Union of RPD components (direct or indirect)
- Distribution of applied force throughout the arch to selected teeth and tissues
- Minimization of torque to individual teeth
- Control prosthesis movement (Cross-arch stability)
- Assist indirect retention



Major Connectors



THE UNIVERSITY OF
**WESTERN
AUSTRALIA**



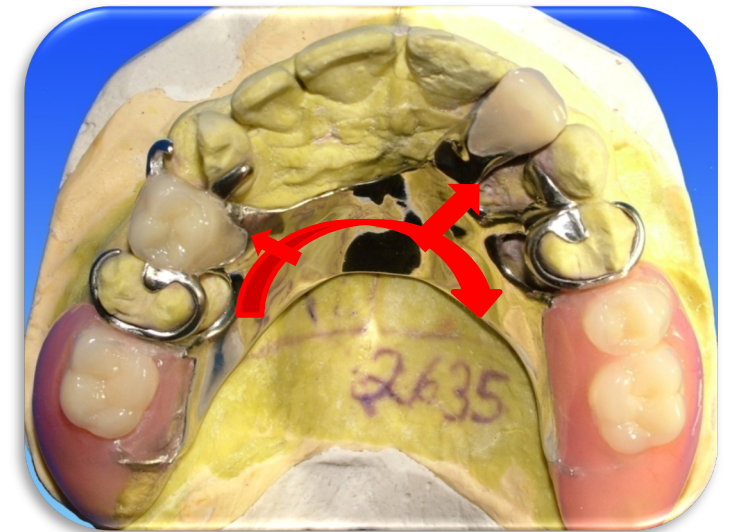
Oral Health Centre
of Western Australia

Attributes and Design Considerations

- **Rigidity:** distribute forces, ensure all other components of the RPD are effective

Flexible major connector:

- damage to hard and soft tissues
- allows forces to be concentrated on individual teeth and segments of residual ridges resulting in tooth mobility and loss, bone resorption leading to decreased support for associated denture bases



Major Connectors



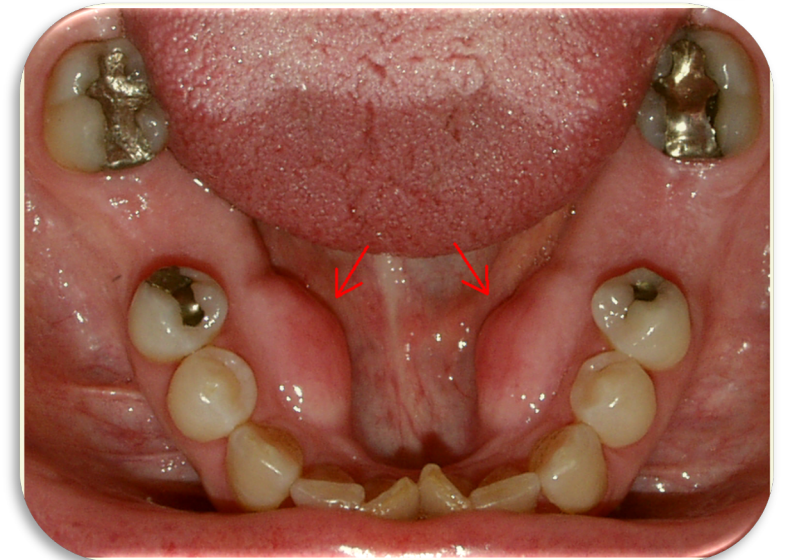
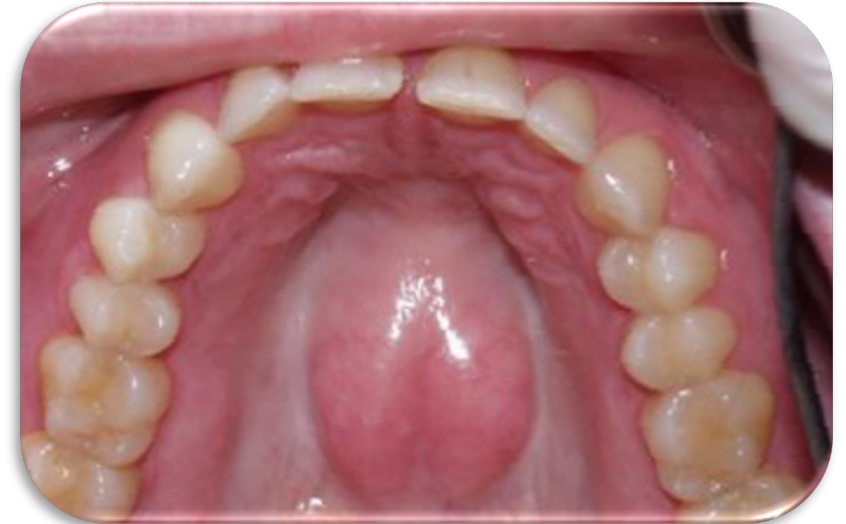THE UNIVERSITY OF
**WESTERN
AUSTRALIA**



Oral Health Centre
of Western Australia

Attributes and Design Considerations

- **Favorable location:**
 - Free of movable tissue
 - Avoid impingement of gingival tissues (gingival margin)
 - Avoid tori and soft tissues prominences
 - Relief beneath MC in areas of possible interferences (e.g. median palatal suture)



Major Connectors



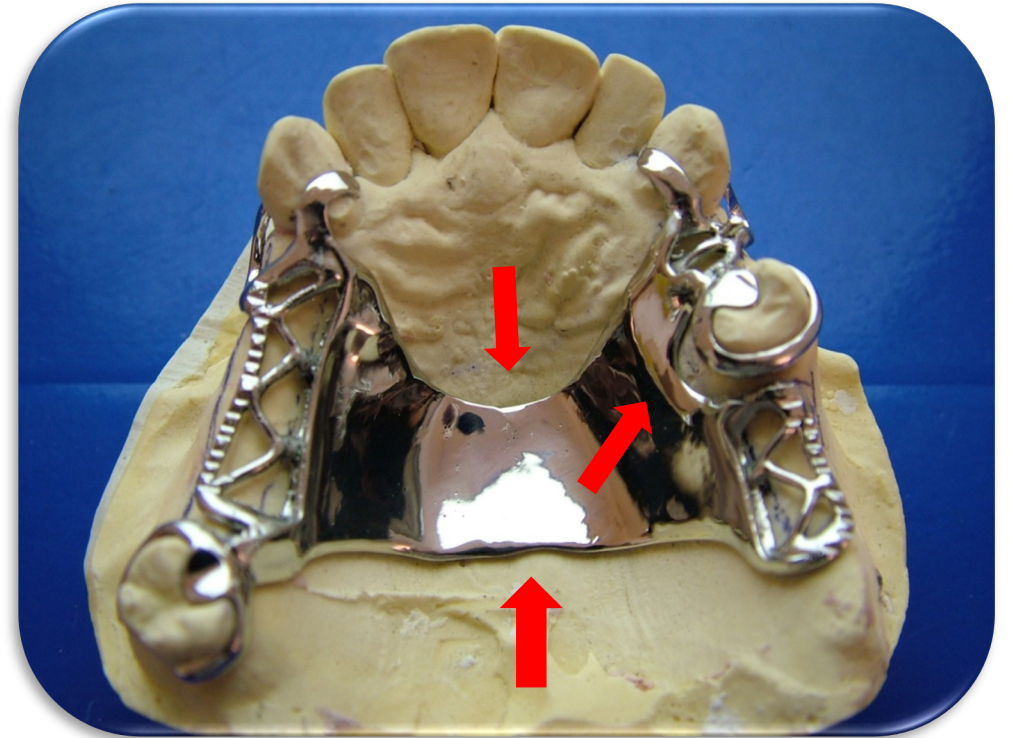
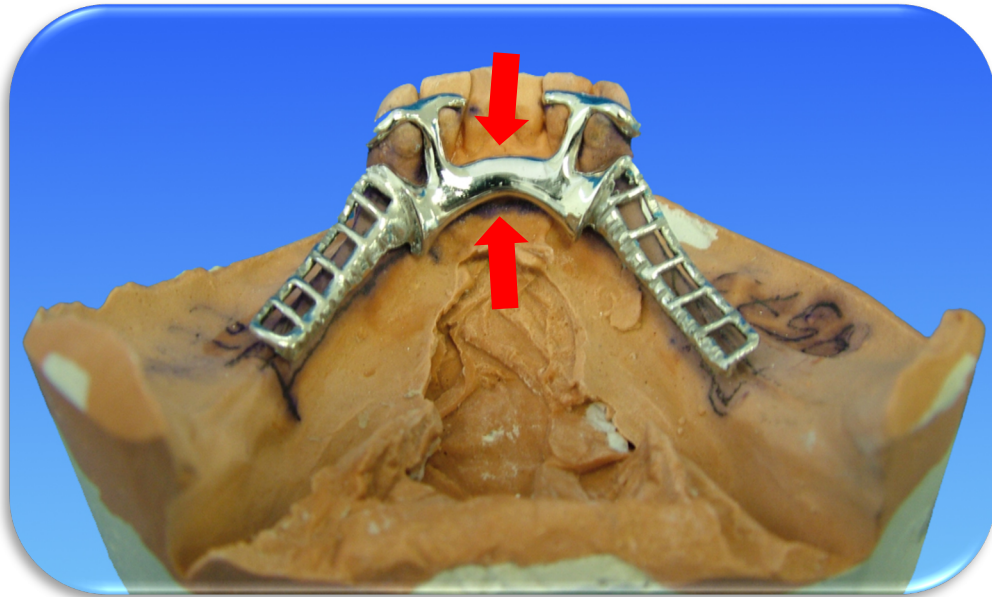
THE UNIVERSITY OF
**WESTERN
AUSTRALIA**



Oral Health Centre
of Western Australia

Attributes and Design Considerations

- **Rounded angles**



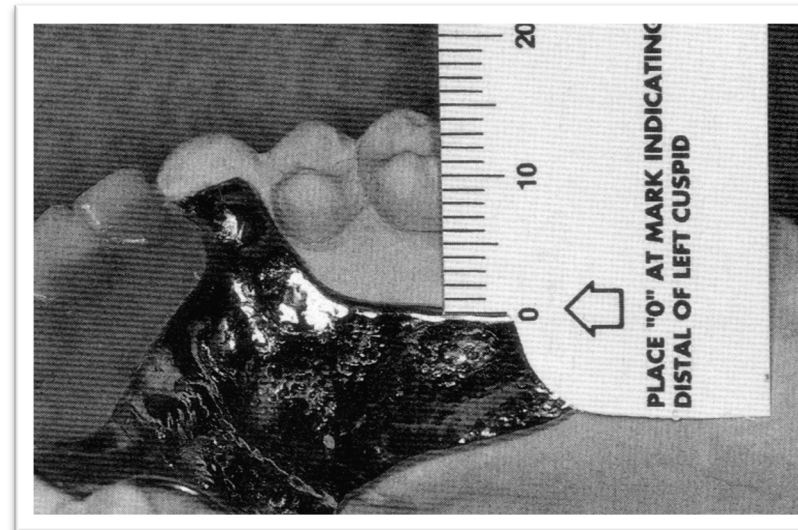
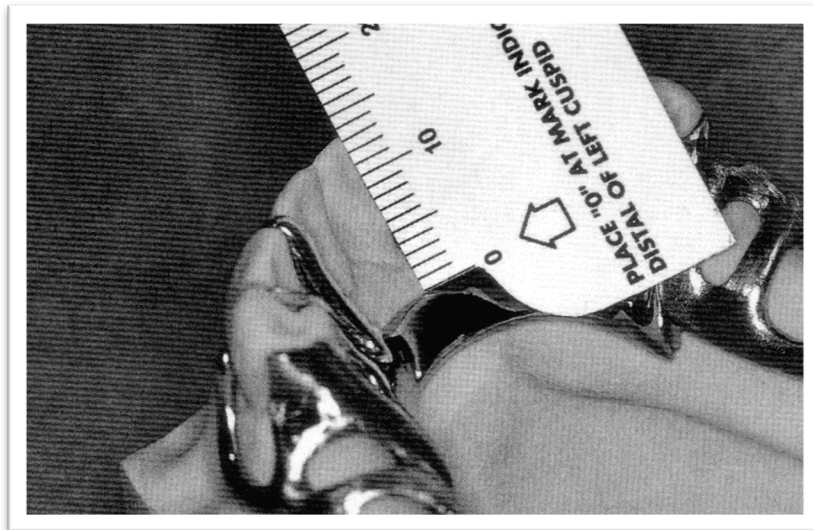Major Connectors

Attributes and Design Considerations

- **Borders of major connectors far from gingival margin:**

Mandible: at least 3 – 4 mm from gingival margin and floor of the mouth

Maxilla: at least 5 – 6 mm from gingival margin and avoid torus and soft palate



Major Connectors



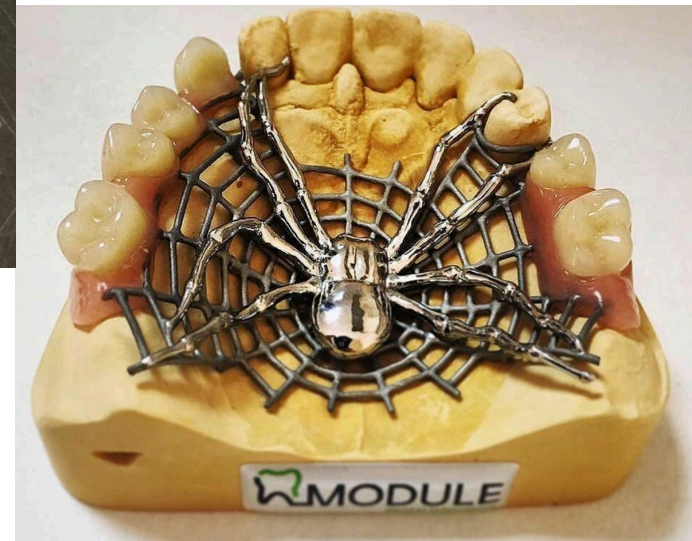
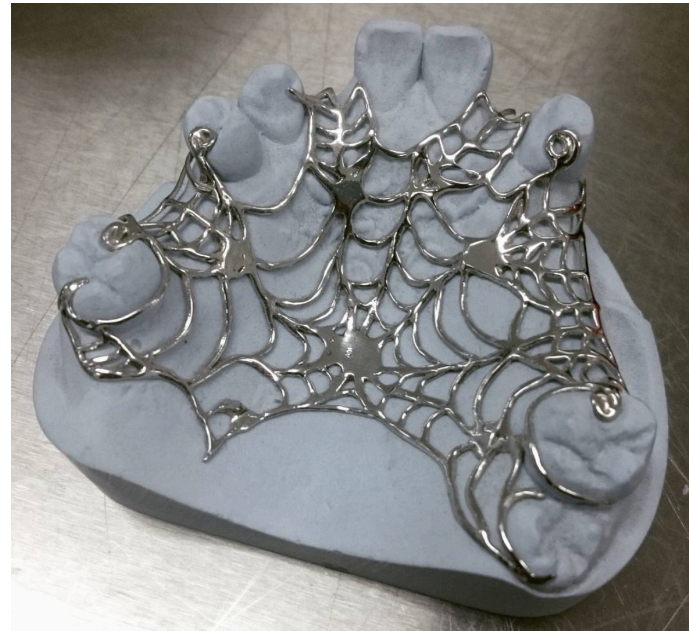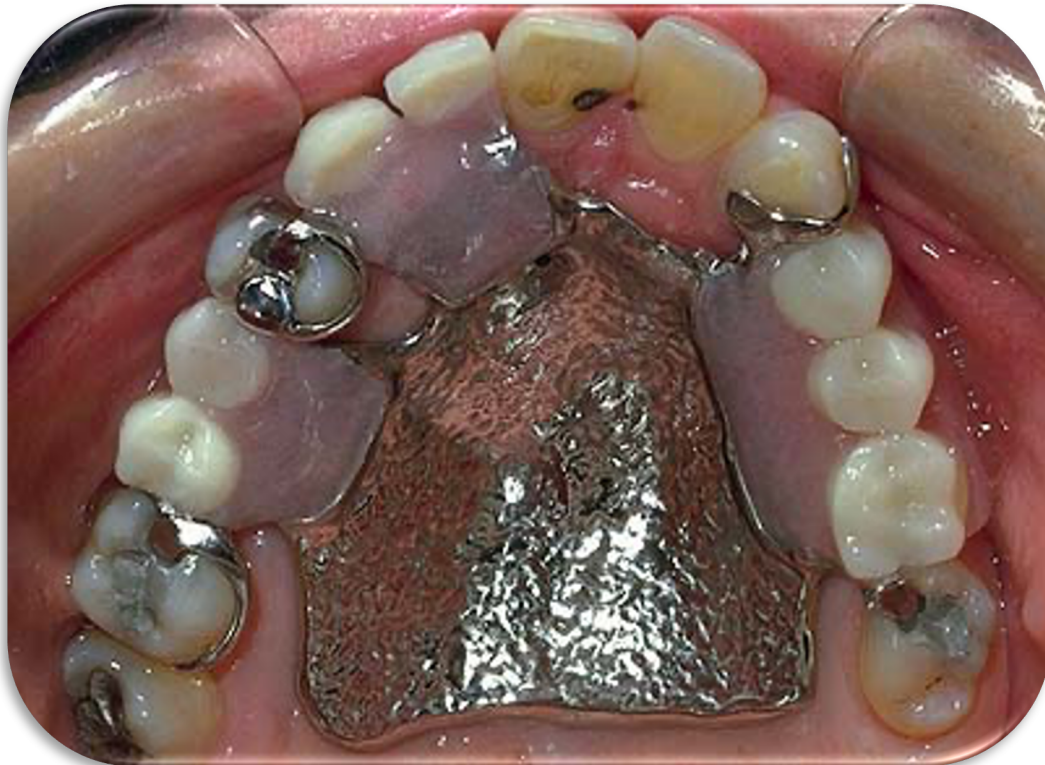THE UNIVERSITY OF
**WESTERN
AUSTRALIA**



Oral Health Centre
of Western Australia

Attributes and Design Considerations

- Maintain the natural contour of subjacent structures



Major Connectors



THE UNIVERSITY OF
**WESTERN
AUSTRALIA**



Oral Health Centre
of Western Australia

Types

- Maxillary
- Mandibular

Maxillary Major Connectors

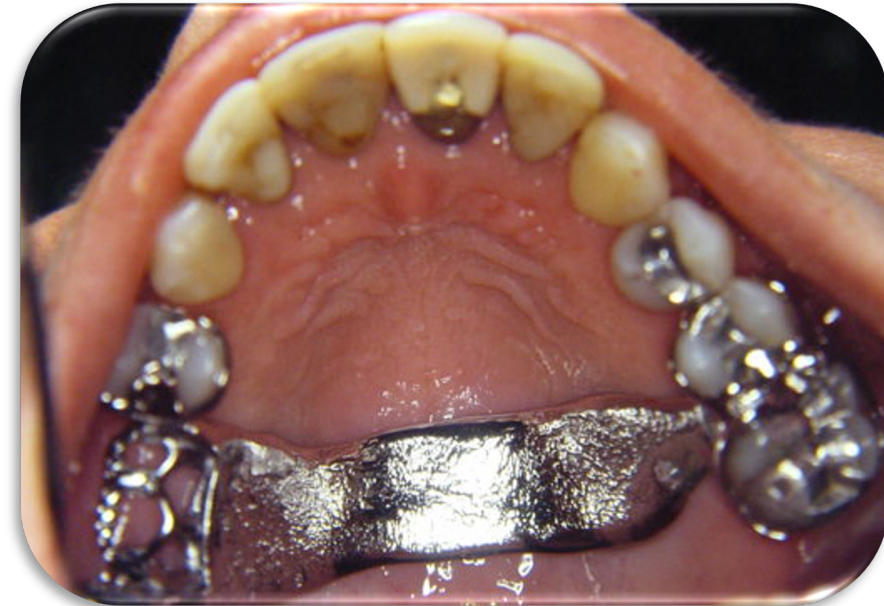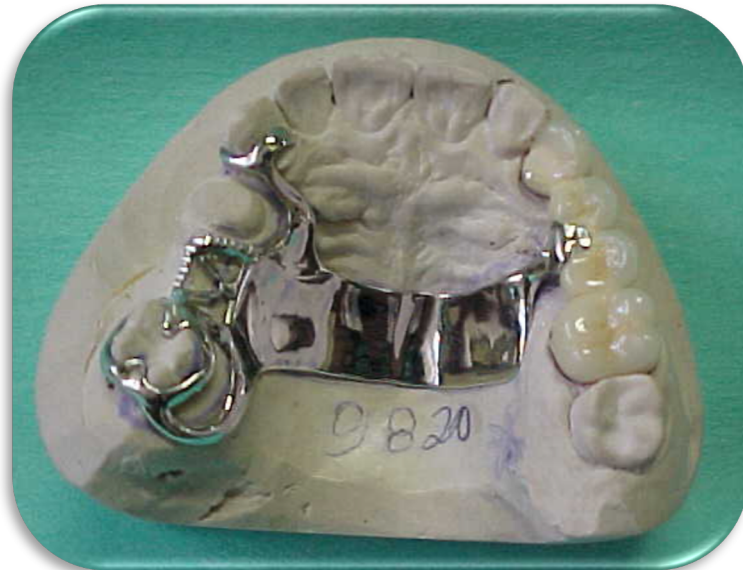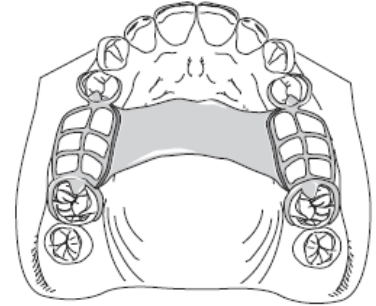
- Intimate contact of MC and palatal mucosa improve retention and stability
- The lower the periodontal support of remaining teeth, the greater the palatal coverage.
- The wider the MC, the thinner it can be. The narrower the MC, the thicker it should be.

Types

- Single palatal strap
- Anterior-posterior palatal strap
- U-shaped palatal connector
- Broad palatal strap or Palatal plate
- Single palatal bar
- Anterior-posterior palatal bar

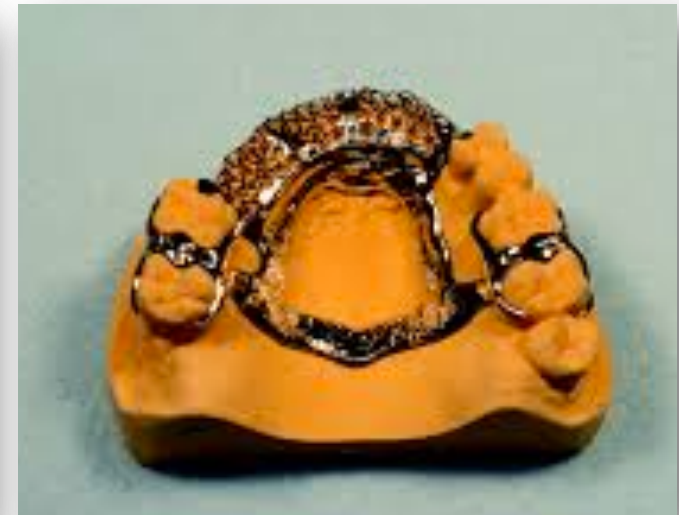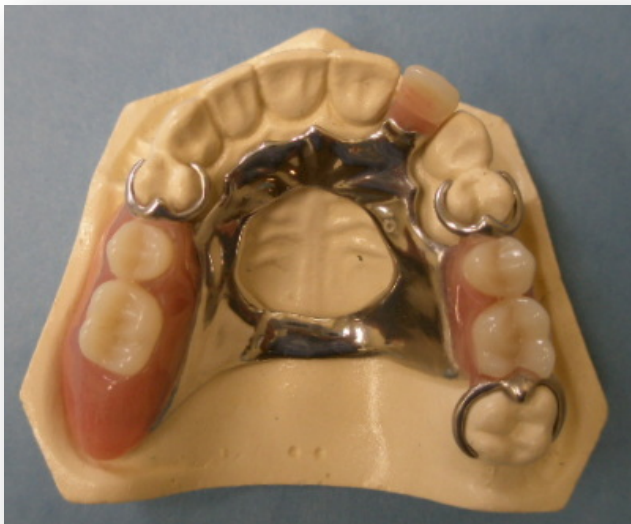Single Palatal Strap

- Generally used for Class III with or without mod (no anterior mod)
- Thin for tongue comfort but wide (≥ 8 mm) enough for rigidity
- Anterior border should follow the valleys but avoid going across the rugae
- The anterior and posterior border cross the suture line at right angles



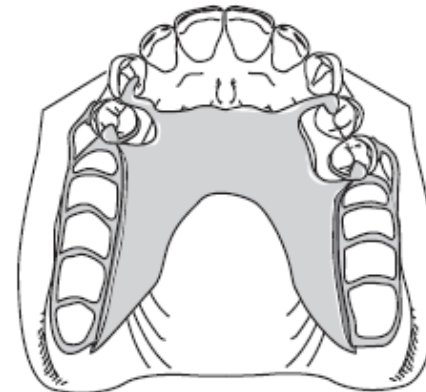
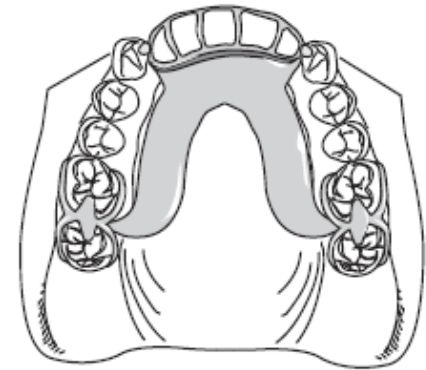
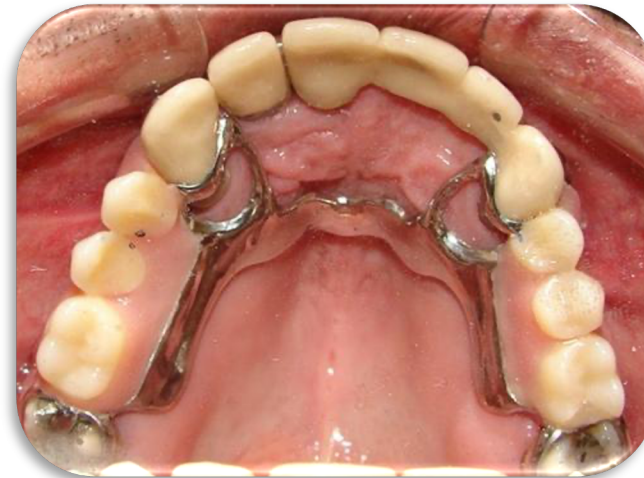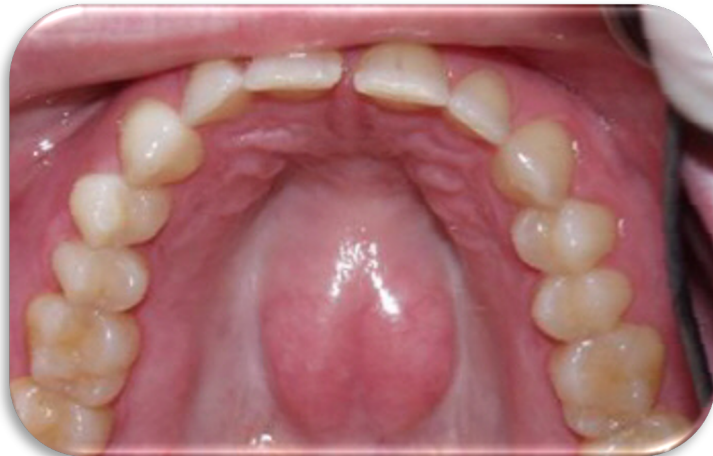Anterior-posterior Palatal Strap

- Combination of anterior and posterior straps
- Class II, III with anterior MOD, IV
- Flat and at least 8 mm wide
- Posterior strap should be anterior to hard/soft palate limit
- Contraindicated: inoperable torus extending to soft palate



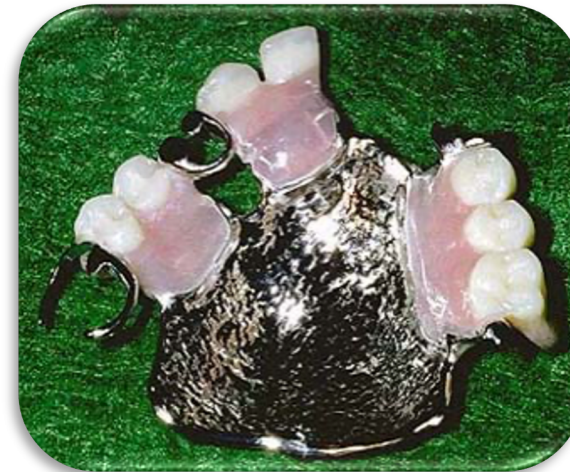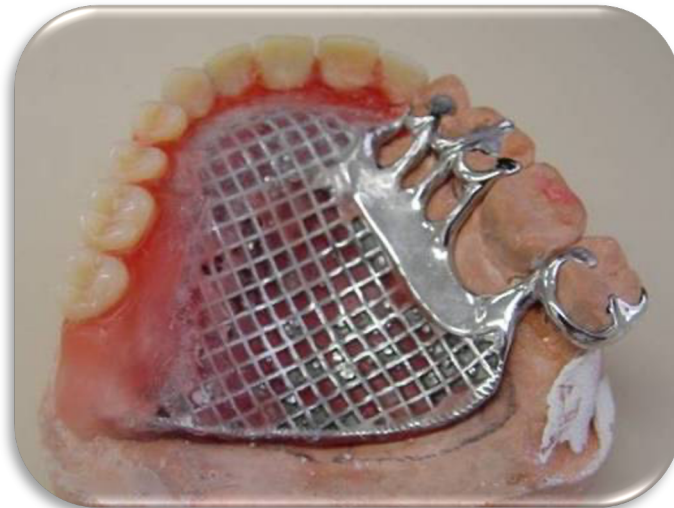
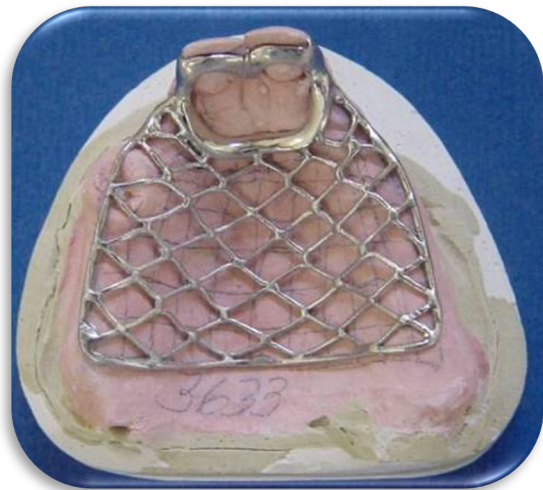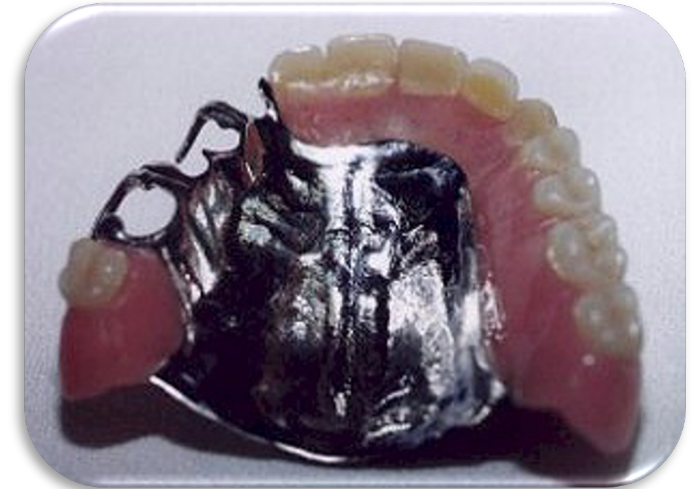U-Shaped Palatal Connector (Horseshoe)

- Inoperable large palatal torus
- Common with Class IV (Missing anterior teeth but posteriors still present)
- Significant gag reflex
- Poorest design for rigidity.
- Bulk is required where tongue space is needed (the most freedom is required in the rugae zone).



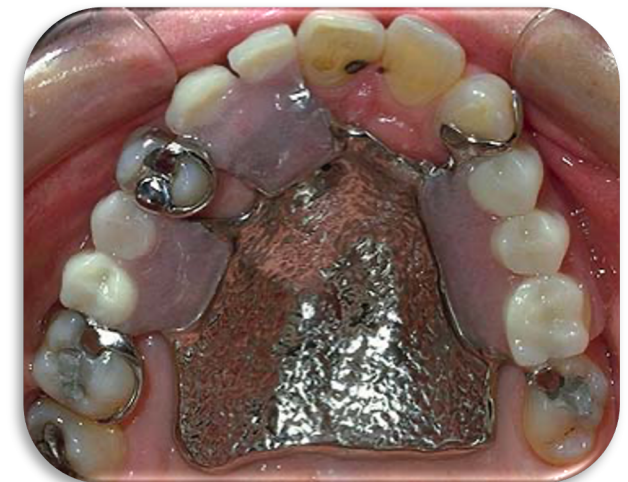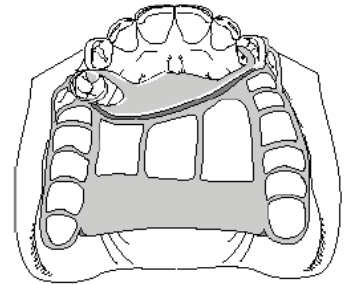
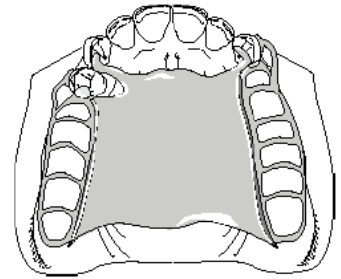
Palatal plate or Full Palatal Coverage

- Cover most of the palatal surface
- Aid retention and stability
- They may be all metal or metal and acrylic



Palatal plate or Full Palatal Coverage

- Cover most of the palatal surface
- Aid retention and stability
- They may be all metal or metal and acrylic
- Indication:
 - Few remaining teeth such as only the anterior arrangement
 - Teeth have a guarded prognosis
 - Long, flat residual ridges

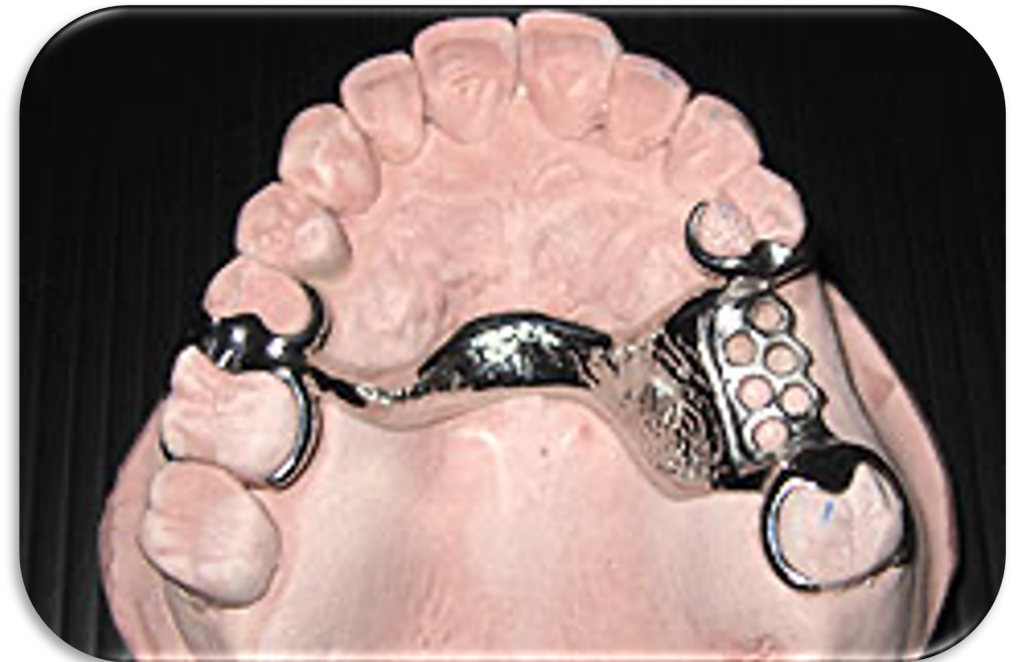

Single Palatal Bar

- Narrow
- Cross-section: half-oval shape
- Less than 8 mm in width
- Class III with small edentulous area

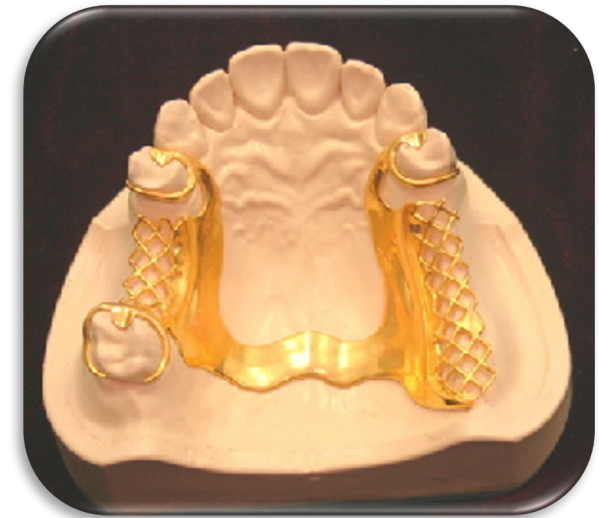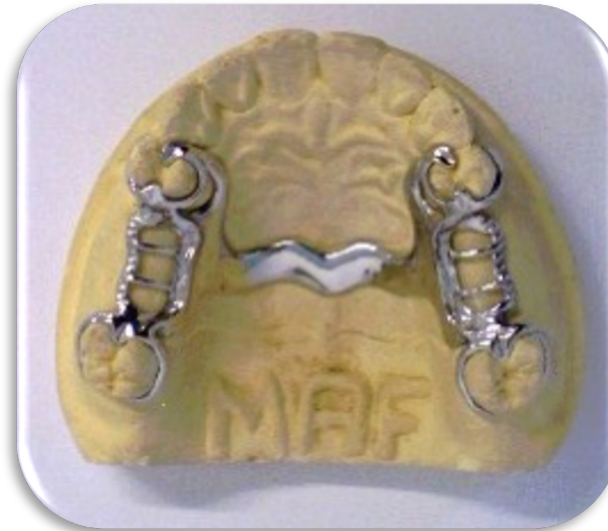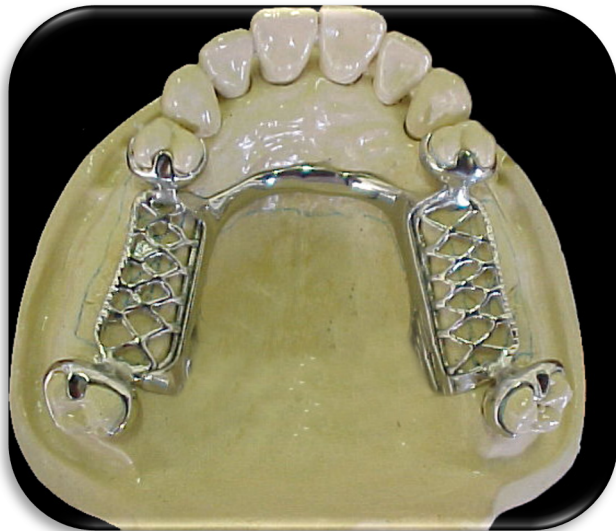Disadvantages

- Bulky – Discomfort. Not to be placed anterior to the 2nd PM
- Low vertical support



Single Palatal Bar

- Anterior: located in the area of palatal rugae
- Median: behind palatal rugae (Ideal)
- Posterior: placed in the limit hard-soft palate

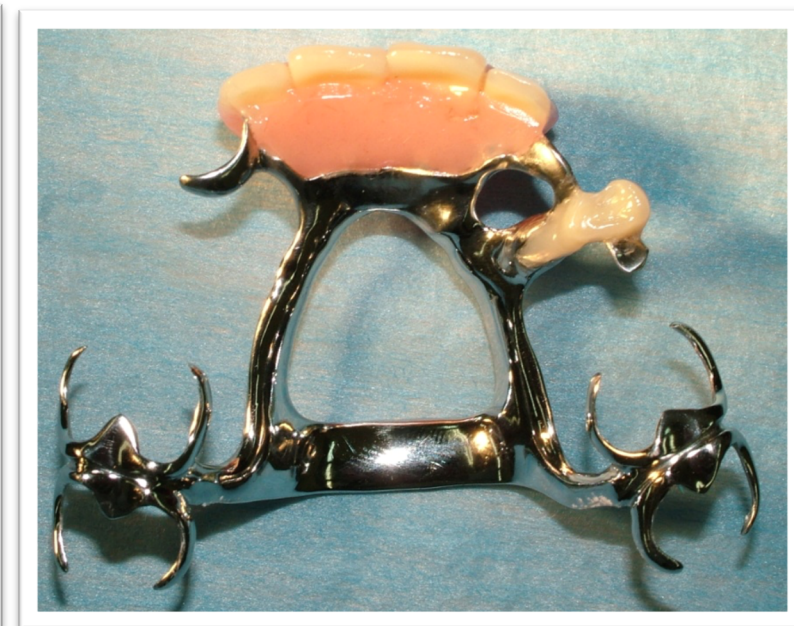

Anterior-Posterior Palatal Bar

- Combination of anterior and posterior bars. Anterior less bulky.
- Two flat longitudinal elements on each side
- Absence of many teeth (anterior and posterior)
- Presence of torus
- Uncomfortable

Advantage:

- Minimize soft tissue coverage
- Rigidity

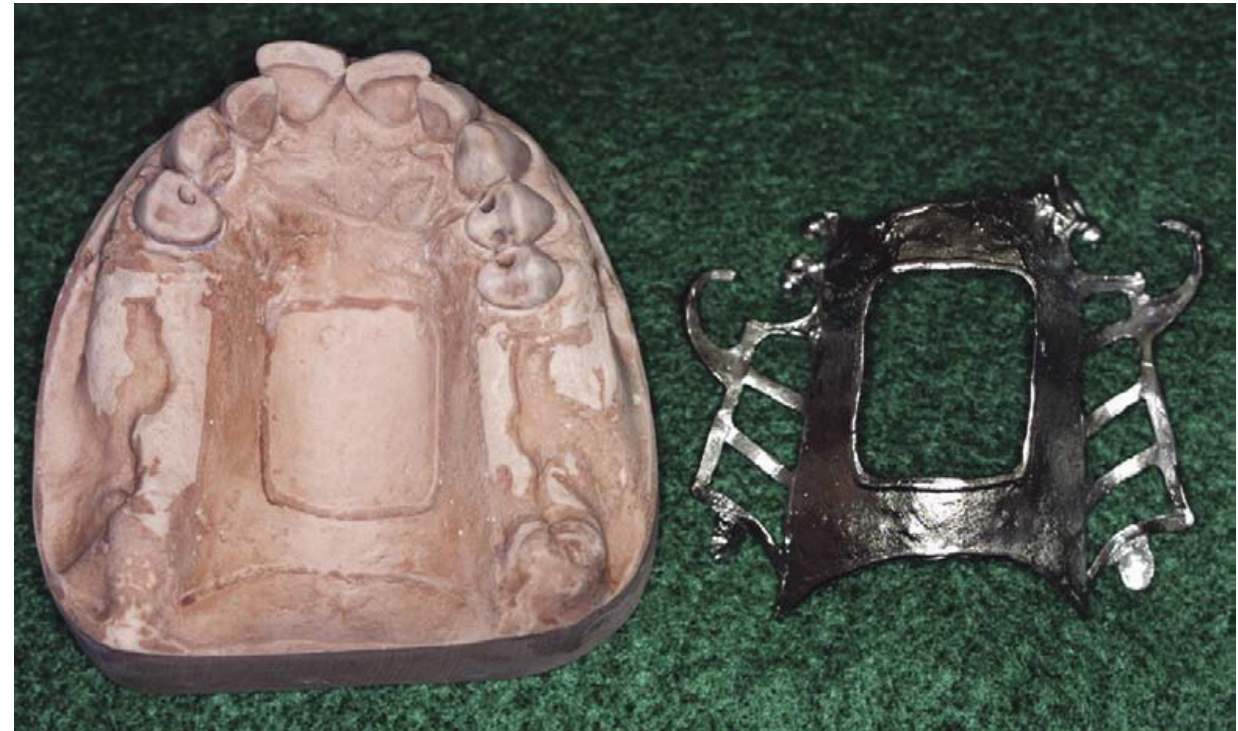

Selection considerations for maxillary major connectors

- If the periodontal support of remaining teeth are weak, more of the palate should be covered: PALATAL STRAP/COMPLETE PALATE INDICATED
- If remaining teeth have adequate periodontal support: PALATAL STRAP/ ANTEROPOSTERIOR PALATAL BAR INDICATED
- For long span distal extension where rigidity critical: ANTEROPOSTERIOR STRAP/COMPLETE PALATE
- Anterior teeth replacement: ANTEROPOSTERIOR PALATAL STRAP/HORSESHOE/ COMPLETE PALATE
- If torus present: ANTEROPOSTERIOR PALATAL STRAP/BAR/HORSESHOE
- PALATAL BAR rarely indicated – less rigid due to less bulk, less vertical support from bony palate
- HORSESHOE used sparingly due to reduced rigidity

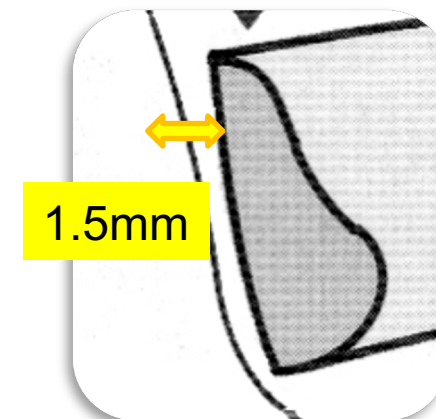
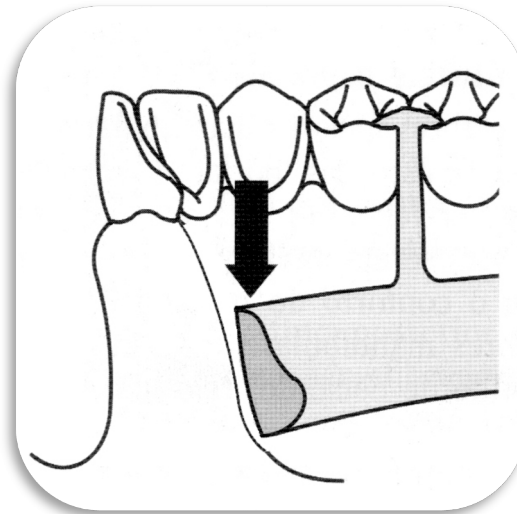
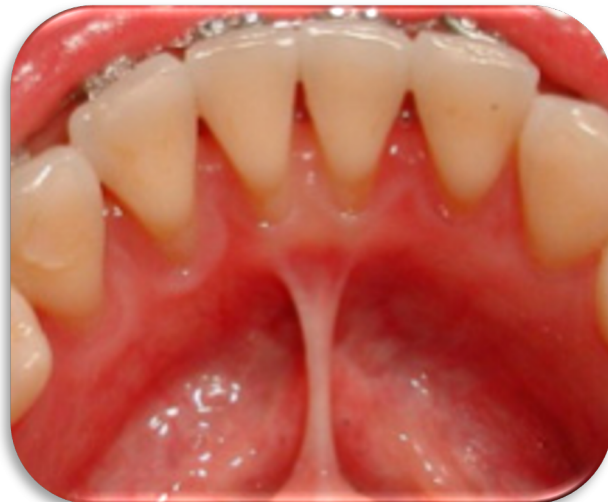Bead Lines

- At borders of maxillary major connectors
- Intend to prevent collection of food particles under the major connector
- displace adjacent soft tissues and produce mechanical seal
- Technicians: done on master cast with spoon excavator/round bur 0.5x1mm and fade out 6 mm from gingival margins



Mandibular Major Connectors

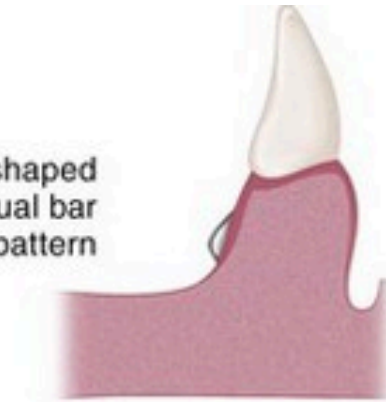
- Mandibular major connectors provide limited support but can provide indirect retention
- Not invading the floor of the mouth, lingual frenulum, and mandibular tori area
- Kennedy Class III – Teeth supported RPD – No relief or small relief is necessary
- Kennedy Class I, II, IV – moderate relief (around 1.5 mm)
- No bead lines required



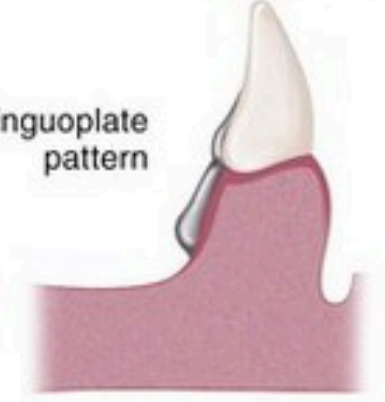
Types

- Lingual bar
- Lingual plate
- Sublingual bar
- Cingulum bar
- Double lingual bar (Kennedy bar)
- Sublingual bar

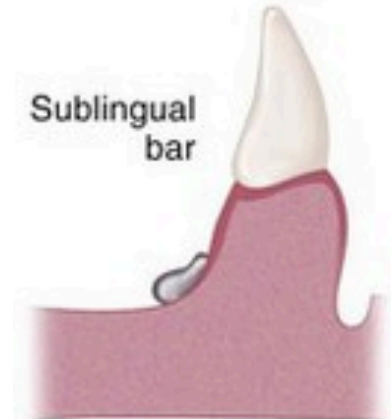
Half-pear-shaped
lingual bar
pattern



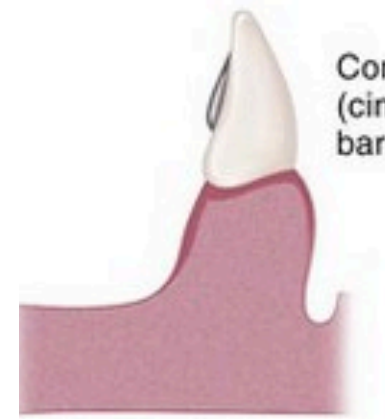Linguoplate
pattern



Sublingual
bar

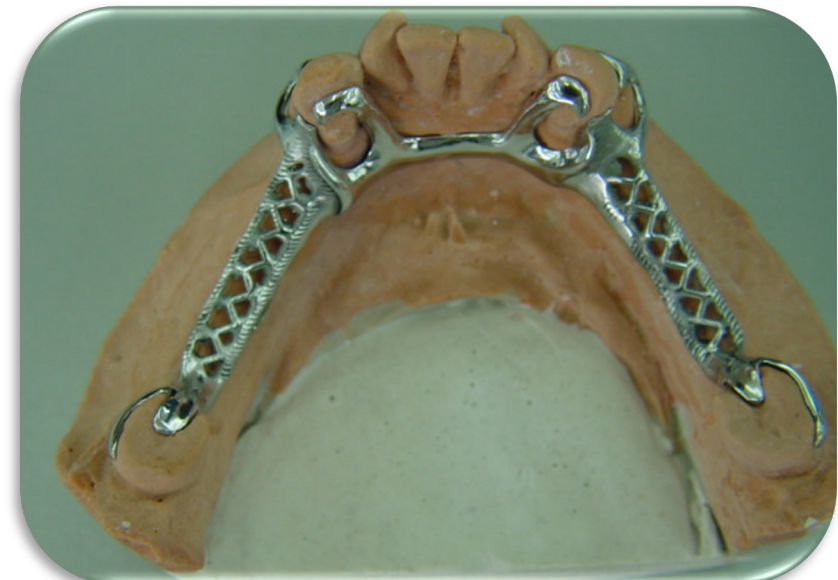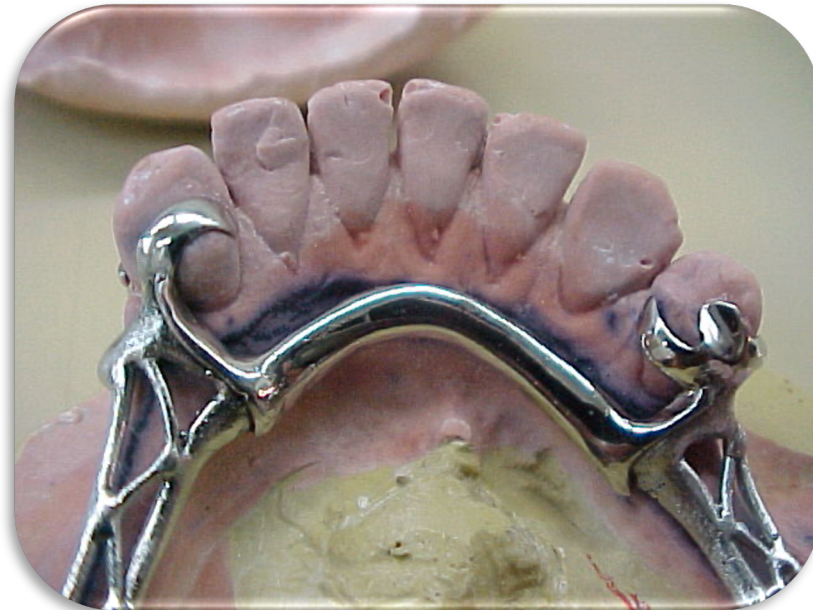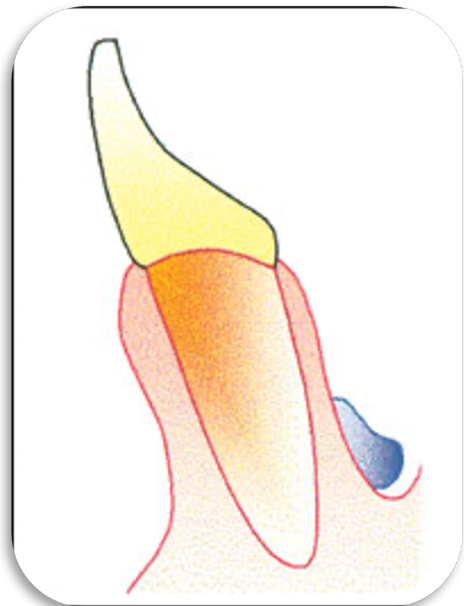


Continuous
(cingulum)
bar



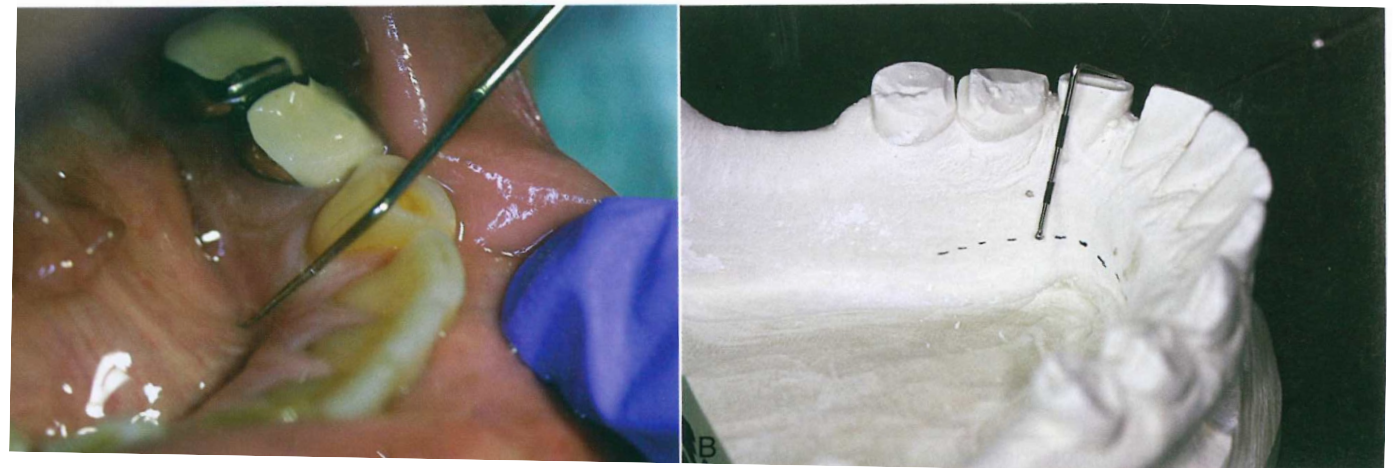
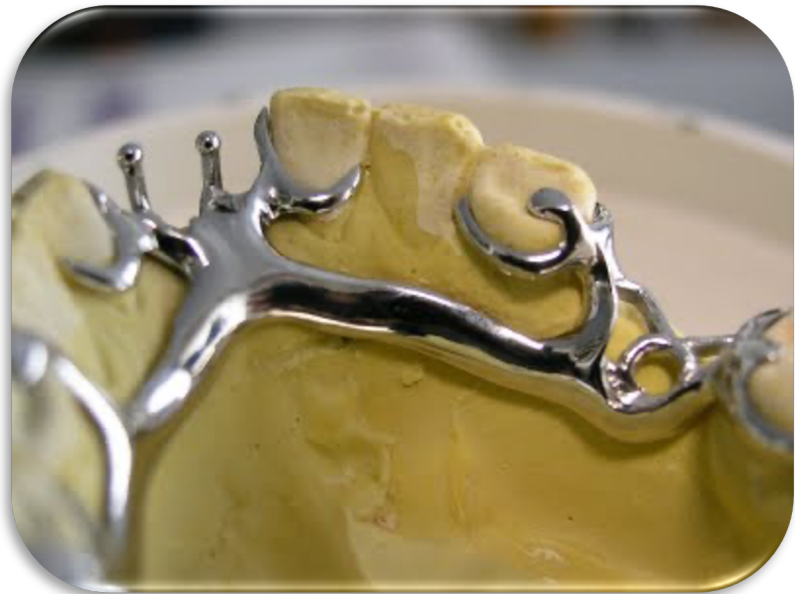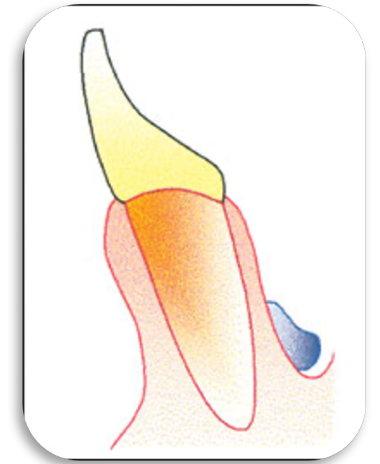
Lingual Bar

- Cross section: Half-pear shape
- Superior border tapered towards the gingival tissue superiorly
- Inferior border: broadest portion



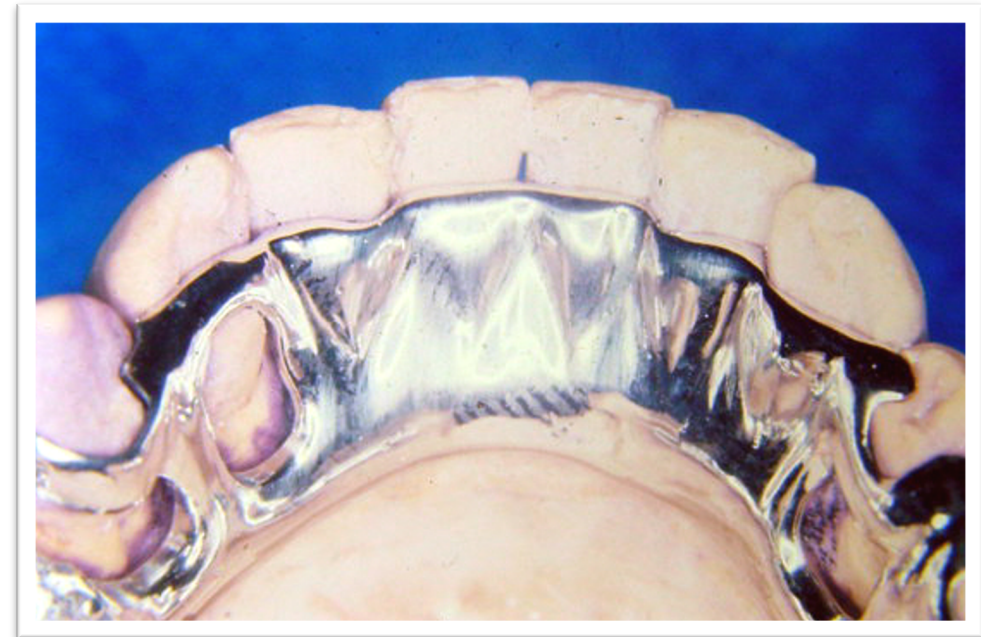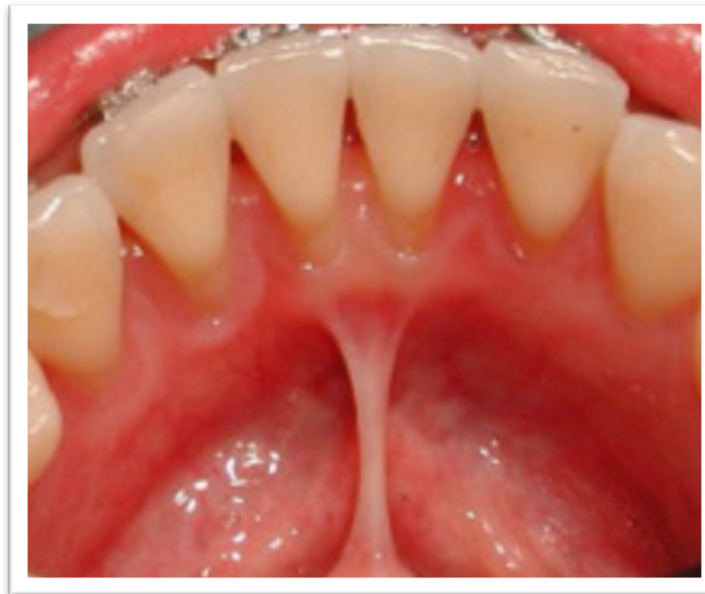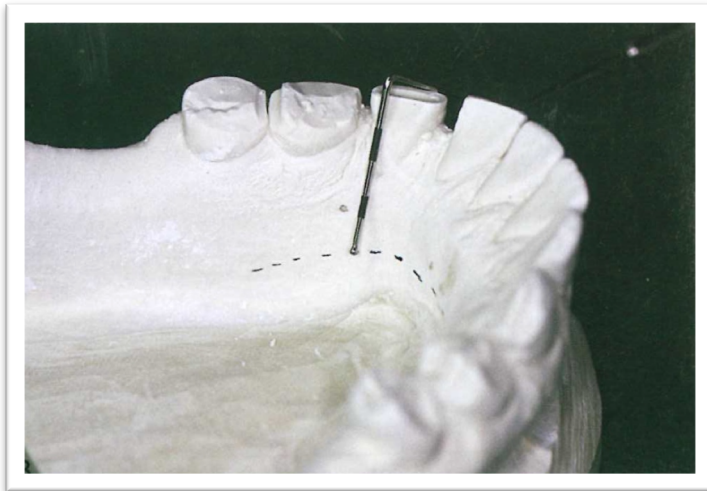
Lingual Bar

- Need at least 8 mm from free gingival margin to floor of the mouth:
Major connector – a minimum height of 5 mm and 3 mm from the gingival margin
- Any case if space is available



Lingual Plate

- A thin metal sheet adapts intimately to the cingulum
- The lingual plate is indicated where the floor of the mouth is shallow or there is an inoperable torus (no space for Lingual bar)
- High frenum attachment



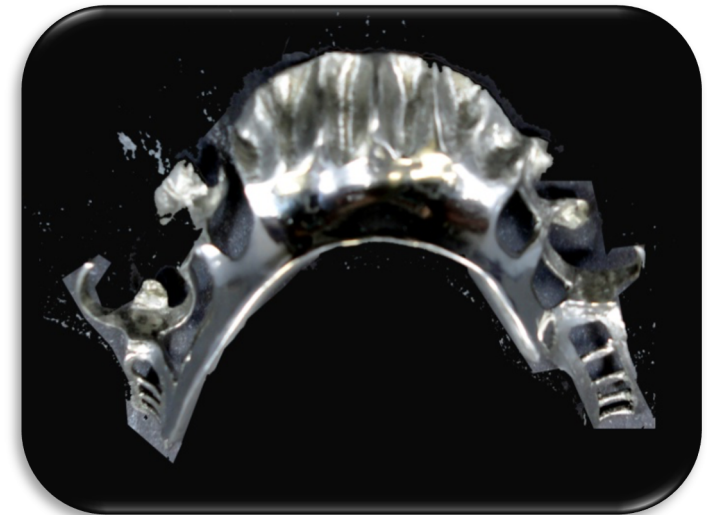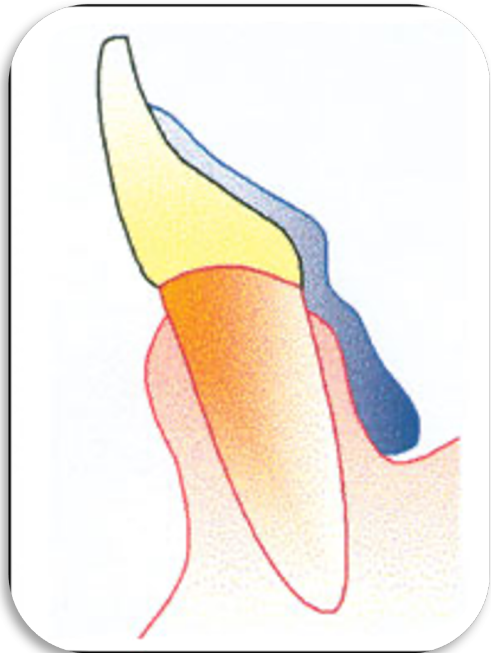Lingual Plate

Advantages:

- Good for indirect retention
- Stabilize teeth with guarded prognoses

Disadvantages:

- May irritate underlying soft tissues and caries when patient has poor oral hygiene

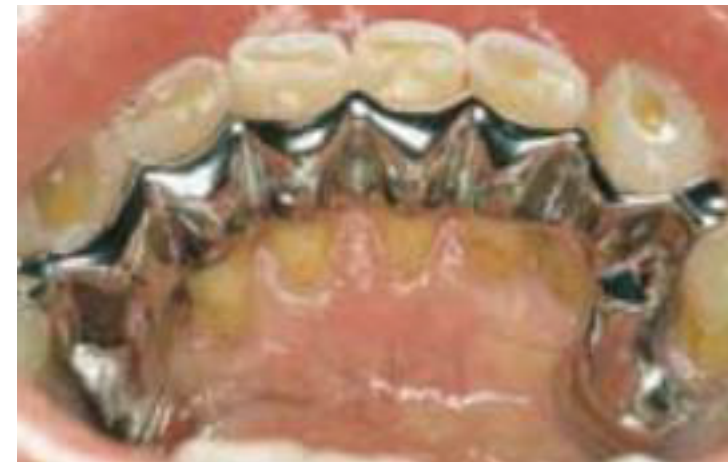
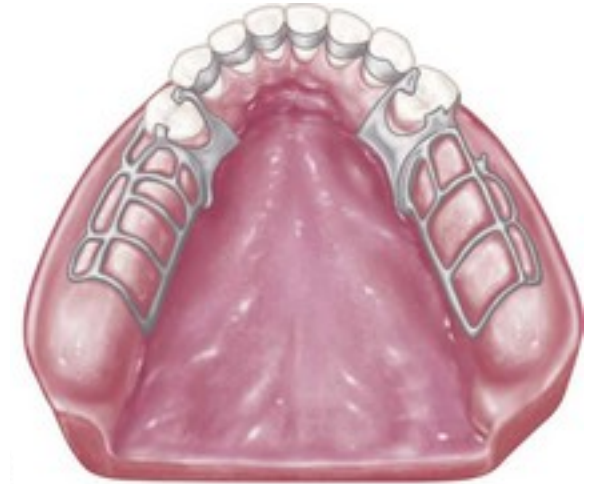

Cingulum Bar

- Can only be used if there are long enough clinical crowns and alternatives are not possible.

Contraindications:

- Retroclined anterior teeth
- Wide diastemas



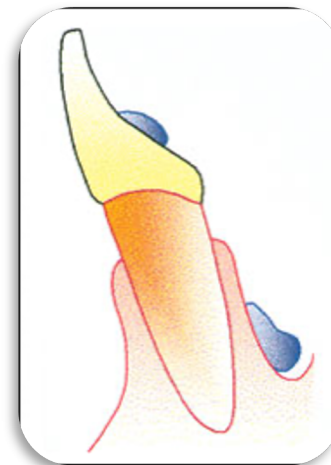
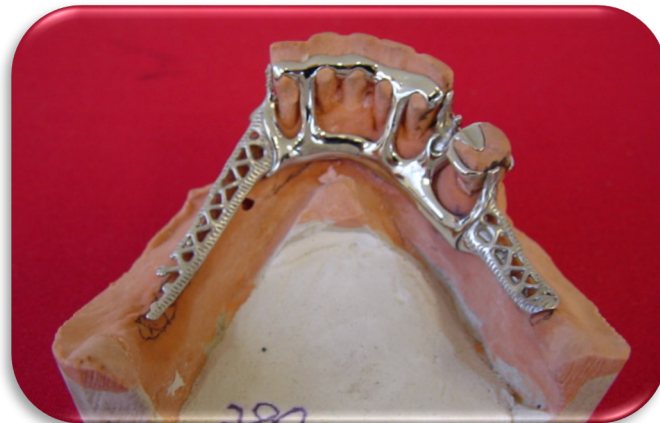Double Lingual Bar

(Kennedy bar)

- Lingual bar with a secondary bar above the cingulum
- Secondary bar acts as an indirect retention

Advantage

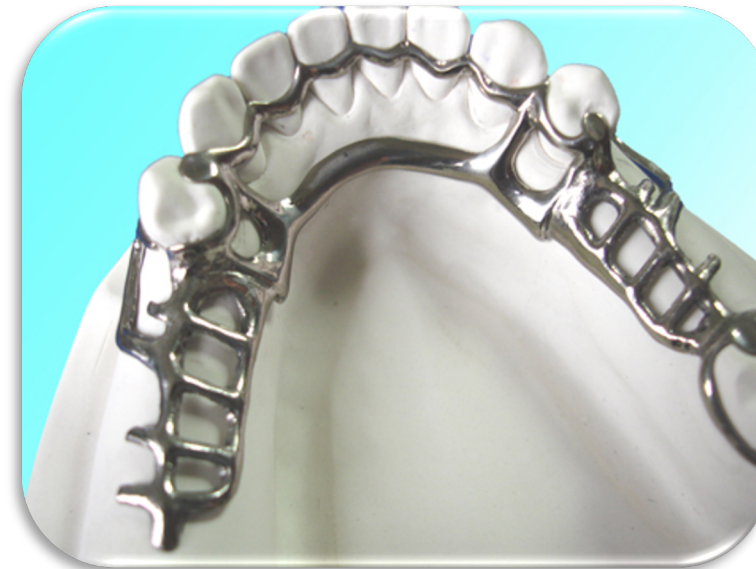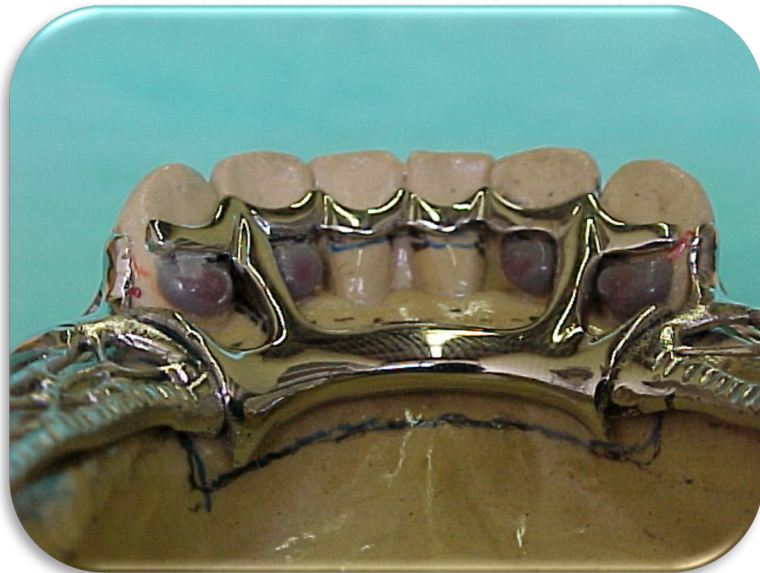- Expose most of the lingual surface of teeth and the interproximal soft tissue
- Natural stimulation of gingival margins



Double Lingual Bar (Kennedy bar)

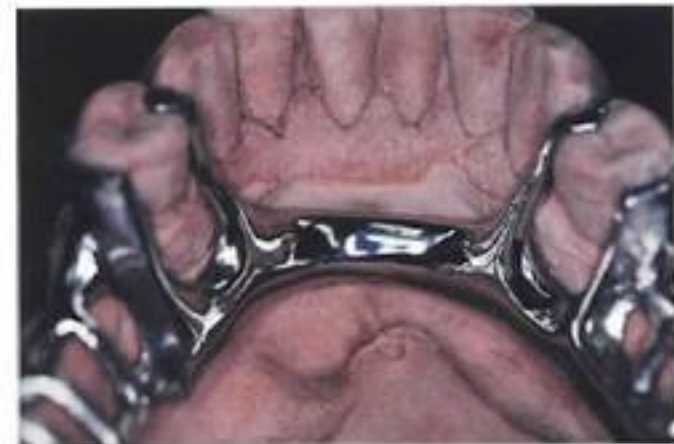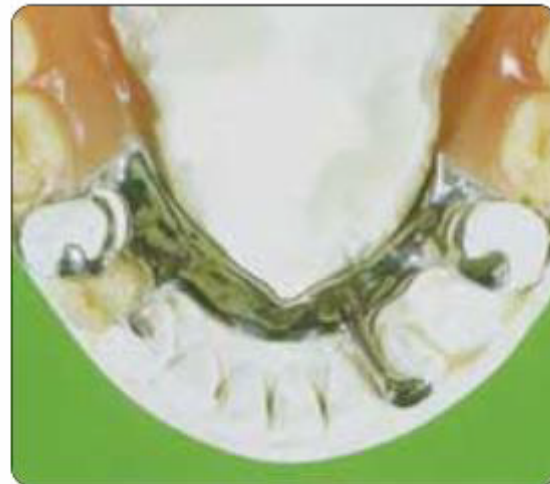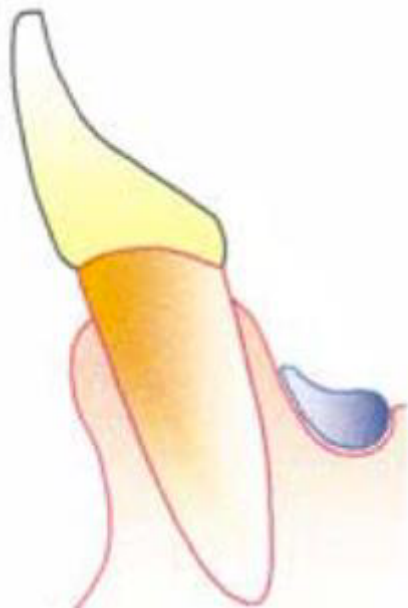
Disadvantage:

- Tendency to trap food debris (marked crowding leads to inaccurate adaptation)
- Irritation of the tongue (multiple borders)

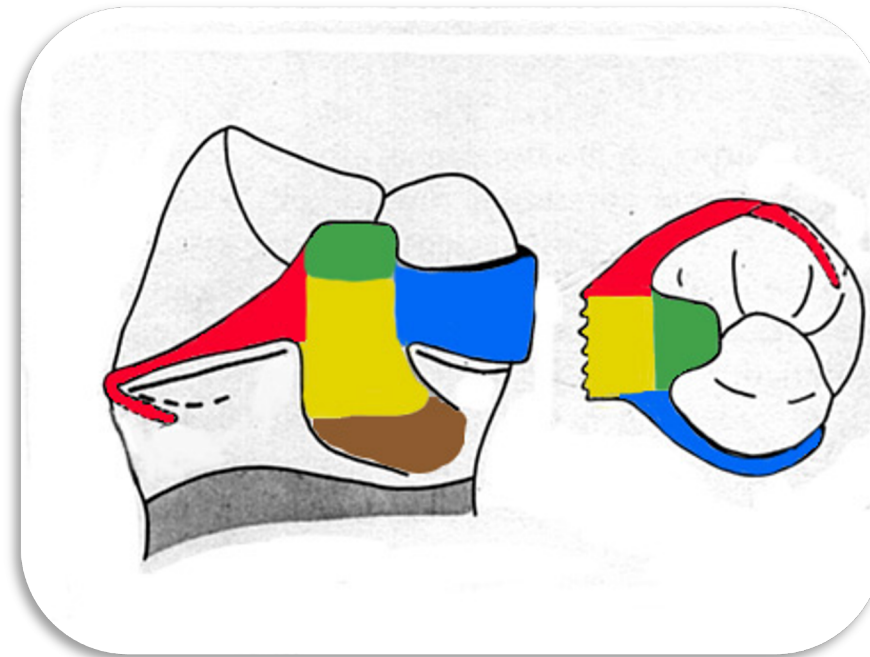


Sublingual Bar

- The sublingual bar is essentially a lingual bar by design but it is placed more posterior and inferior
- Lying over and parallel to the anterior floor of the mouth.
- Shallow floor of mouth or lingual undercuts
- Low frenulum attachment



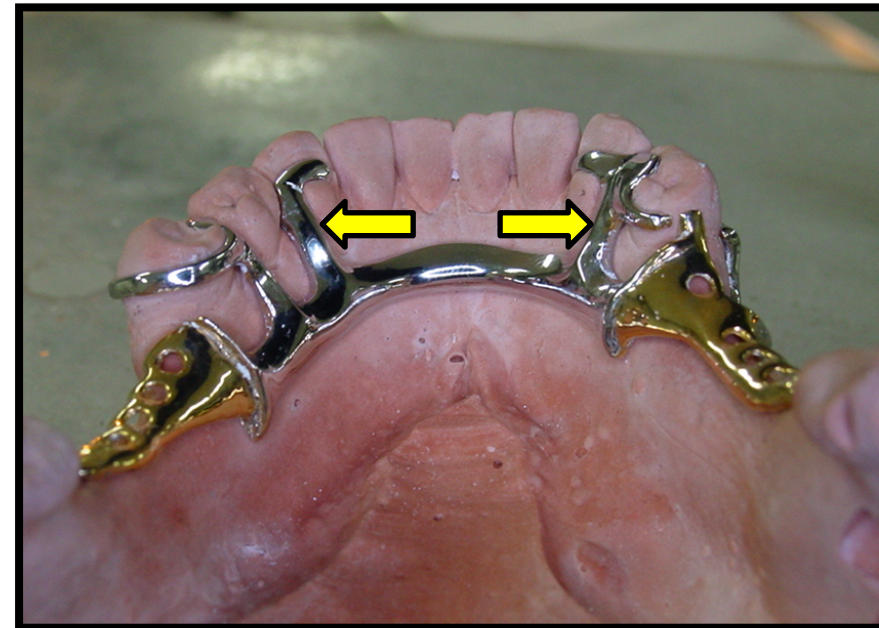
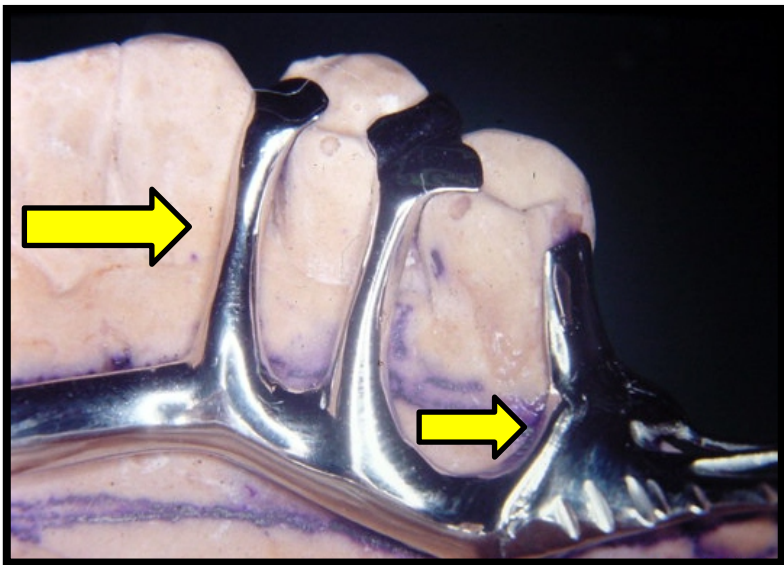
Minor Connectors



Minor Connectors

Functions

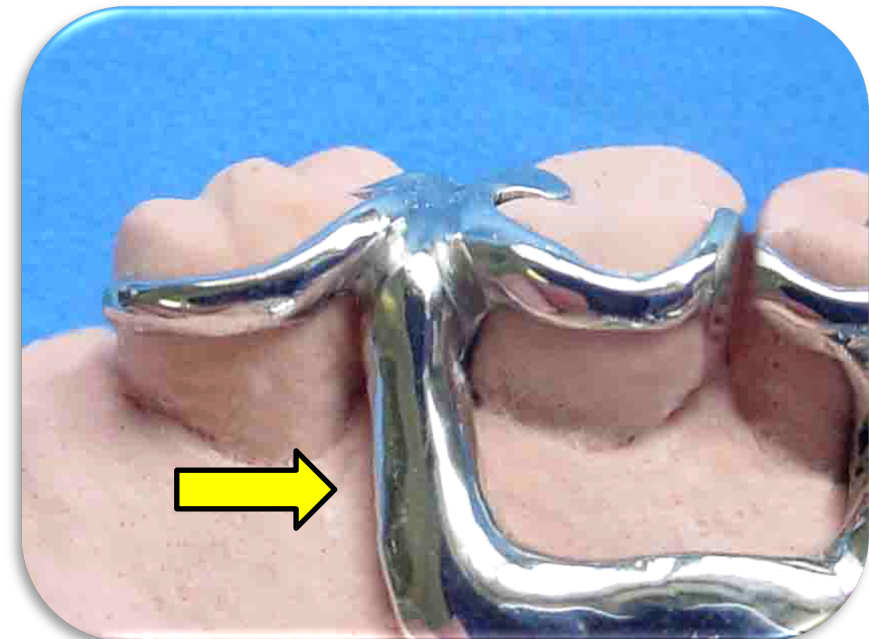
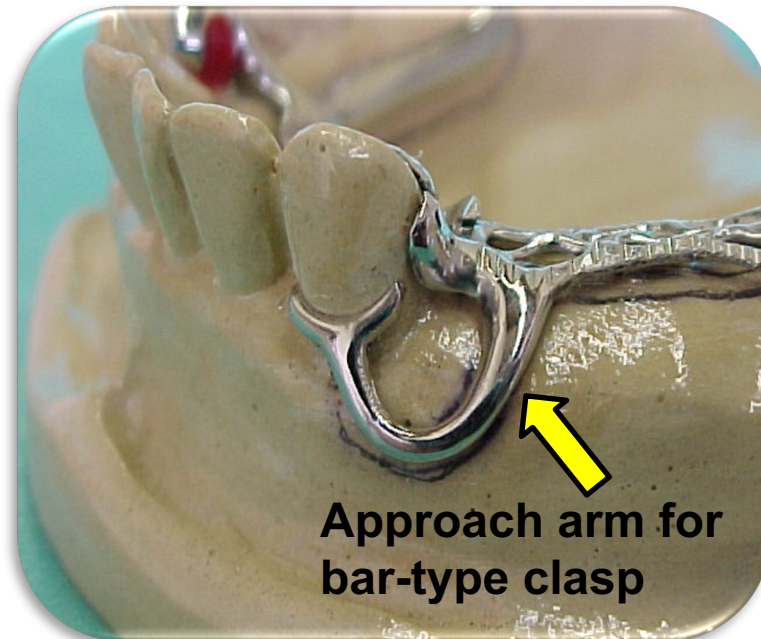
- Join the remaining components of a RPD to the major connector:
Clasp assemblies, indirect retainers (auxiliary rest)



Minor Connectors

Functions

- Join the remaining components of a RPD to the major connector:
Clasp assemblies, indirect retainers (auxiliary rest)



Minor Connectors



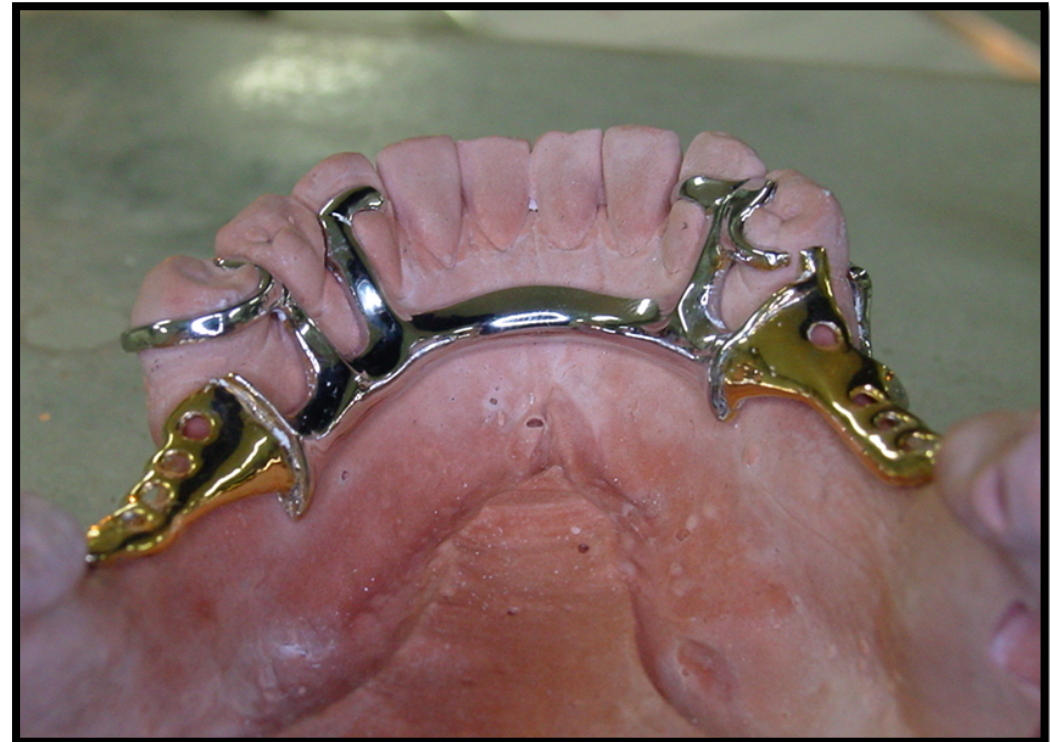
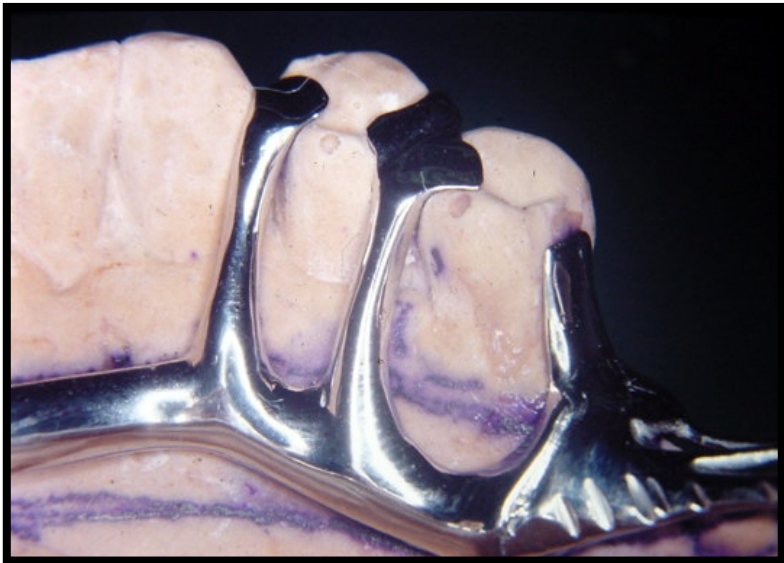THE UNIVERSITY OF
**WESTERN
AUSTRALIA**



Oral Health Centre
of Western Australia

Functions

- Distribute applied forces to the supporting teeth and oral tissues, help reciprocation



Minor Connectors



THE UNIVERSITY OF
**WESTERN
AUSTRALIA**

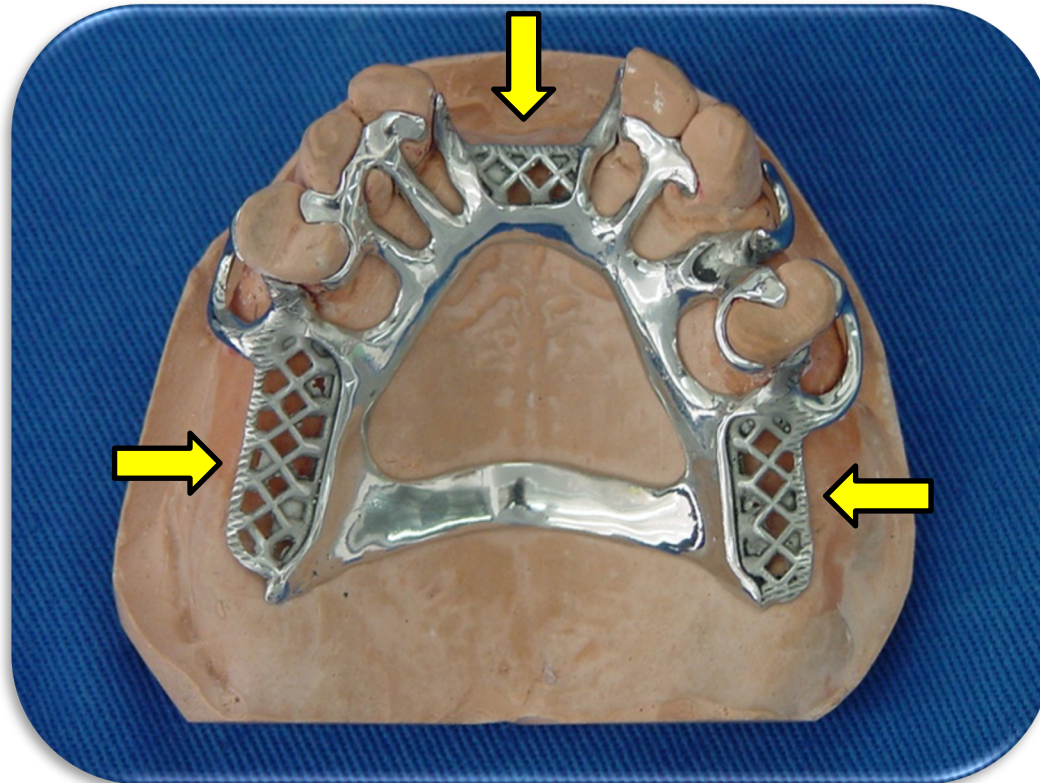


Oral Health Centre
of Western Australia

Functions

- Join denture base to major connector

Metal gridwork

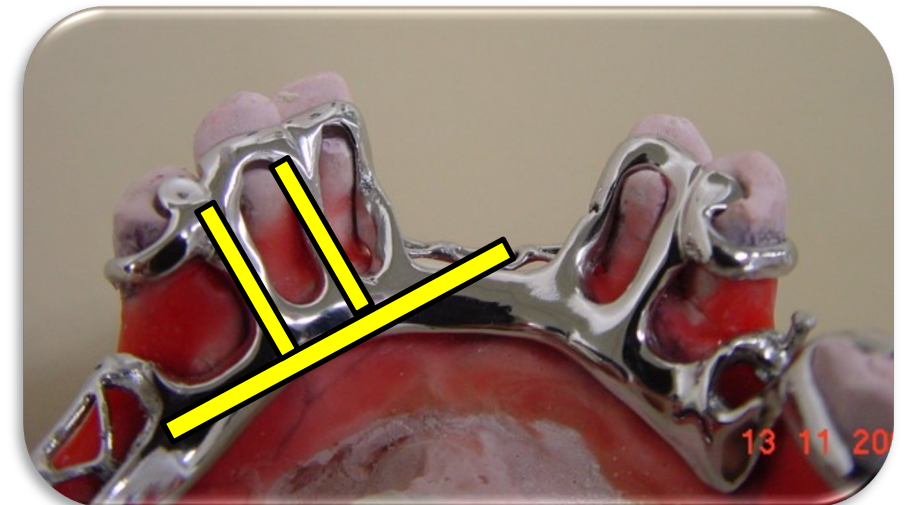
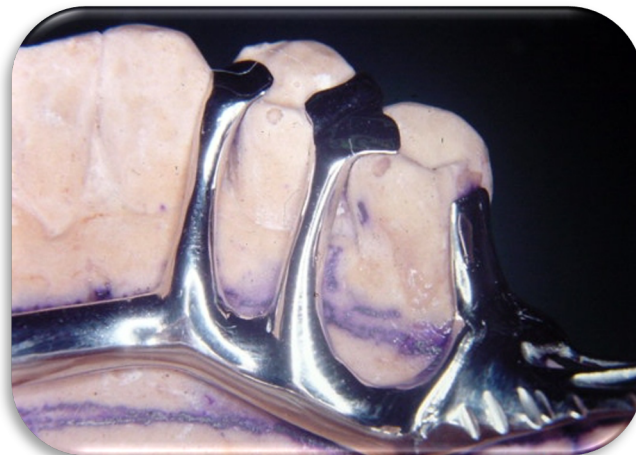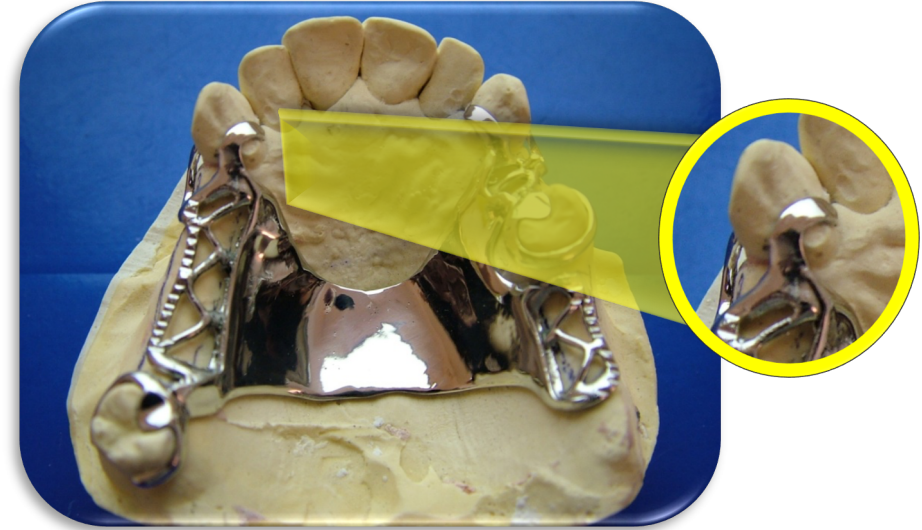


Minor Connectors



Primary attributes

- Rigid
- Form right angle with major connector
- Preferably located in interdental space
- Wider linguobuccal direction, narrow mesiodistal

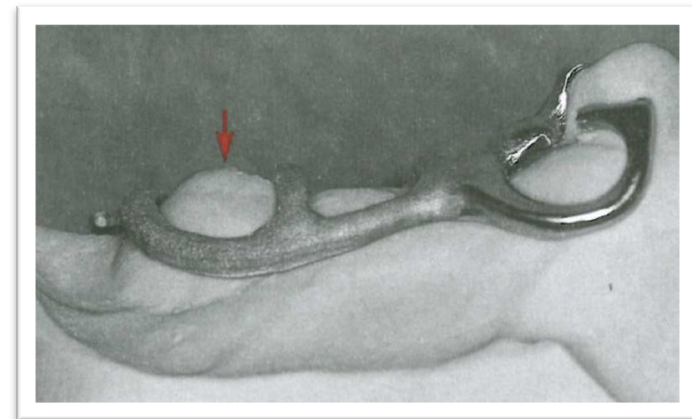
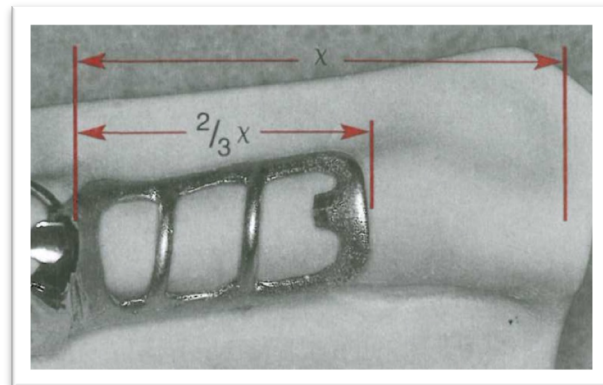
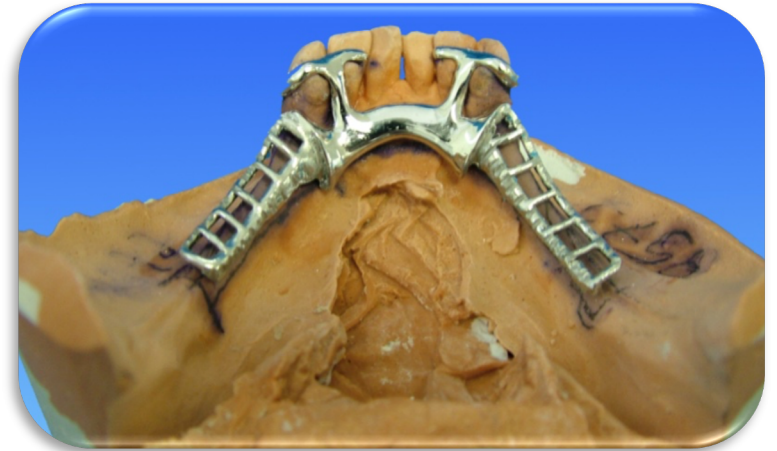


Minor Connectors



Minor connectors joining denture bases to major connector

- Gridwork
- Rigid
- No interference with artificial teeth
- Provide adequate support and retention for the resin base:
 - Maxilla: cover the tuberosity
 - Mandible: $\frac{2}{3}$ length of edentulous ridge



Minor Connectors


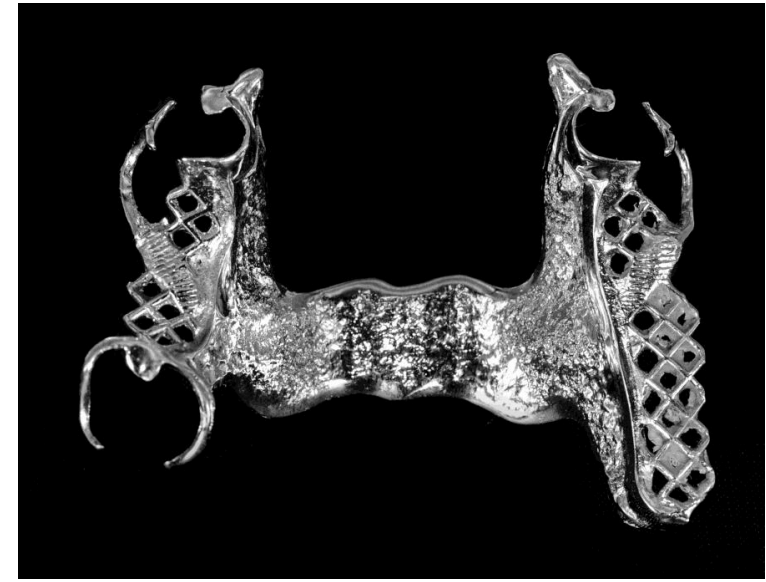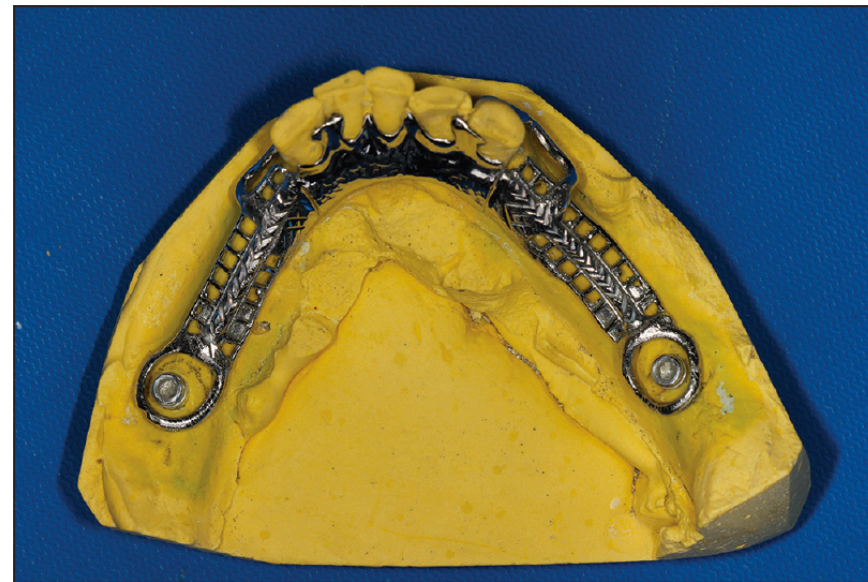
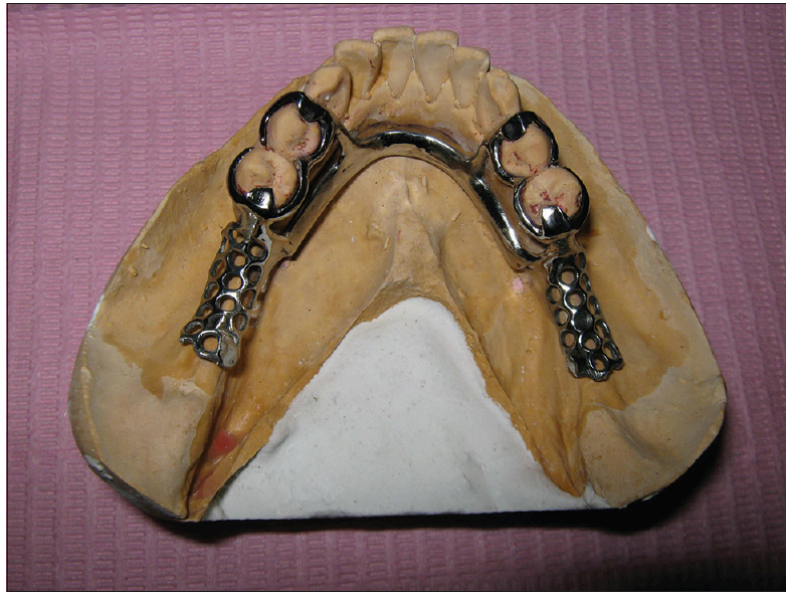

THE UNIVERSITY OF
**WESTERN
AUSTRALIA**



Oral Health Centre
of Western Australia

Minor connectors joining denture bases to major connector



Minor Connectors




THE UNIVERSITY OF
WESTERN
AUSTRALIA



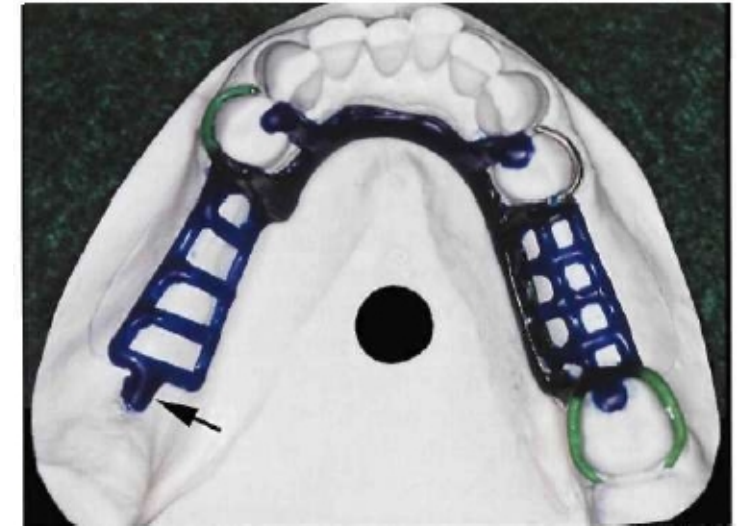

Oral Health Centre
of Western Australia

Minor connectors joining denture bases to major connector

Cast Stop



GAP



- Kennedy Class I and II: Free-end saddles
- Small area of minor connector contacting the master cast
- **Prevent displacement or deformation of the metal framework during packing** and processing of acrylic resin
- Posterior region where minor connector crosses the center of the ridge
- Made by removing wax where posterior strut of minor connector crosses center of the ridge

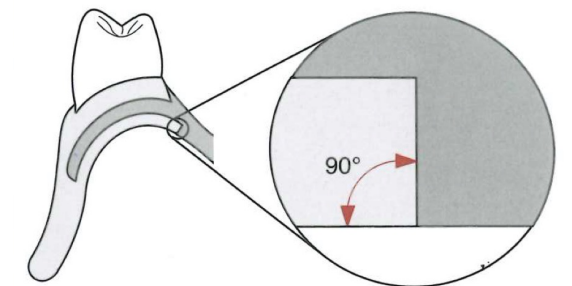
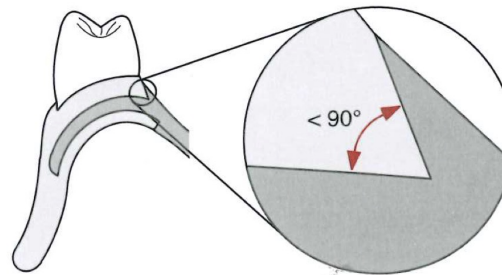
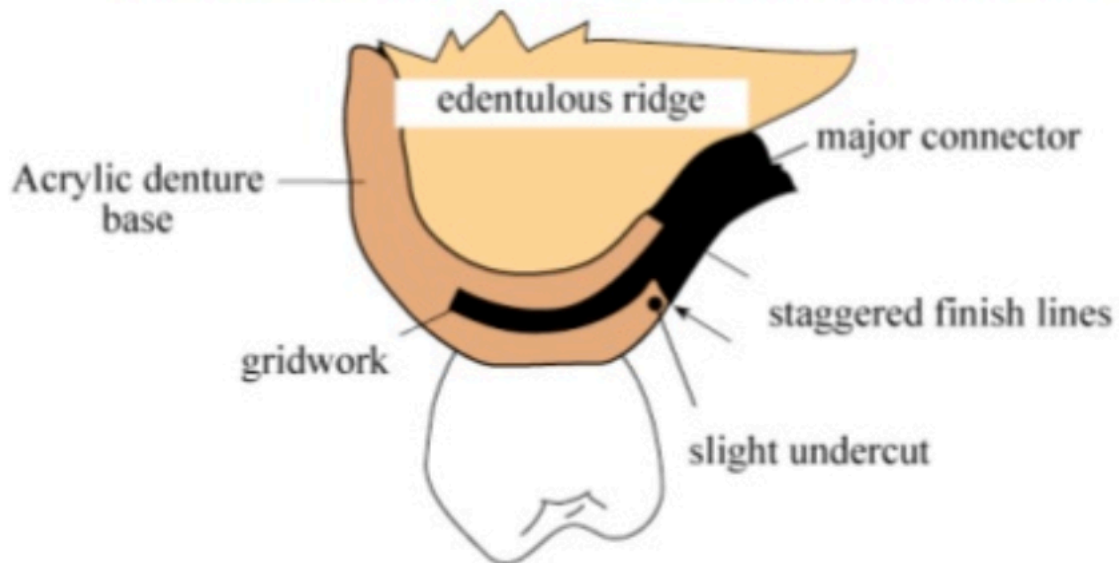
Minor Connectors



Minor connectors joining denture bases to major connector

Internal and external finish lines

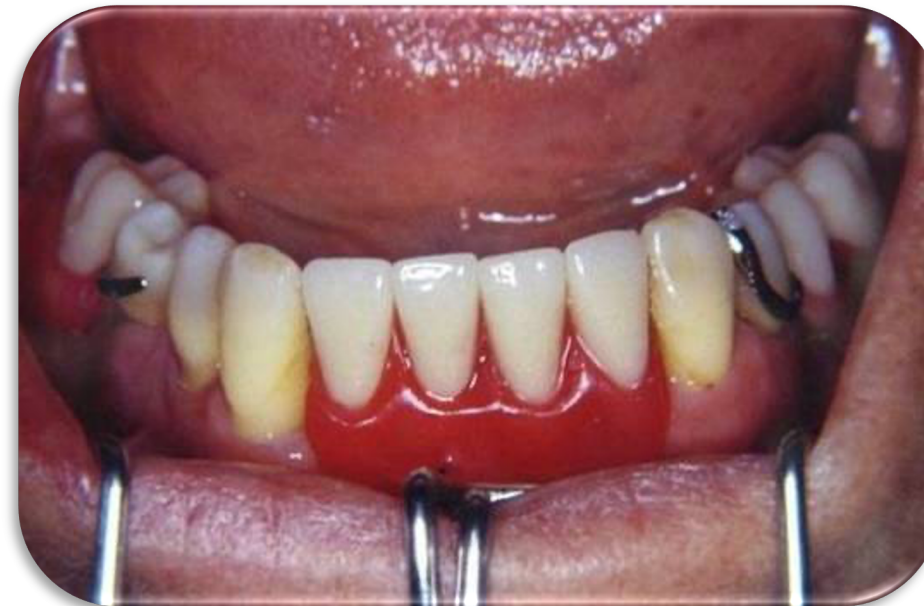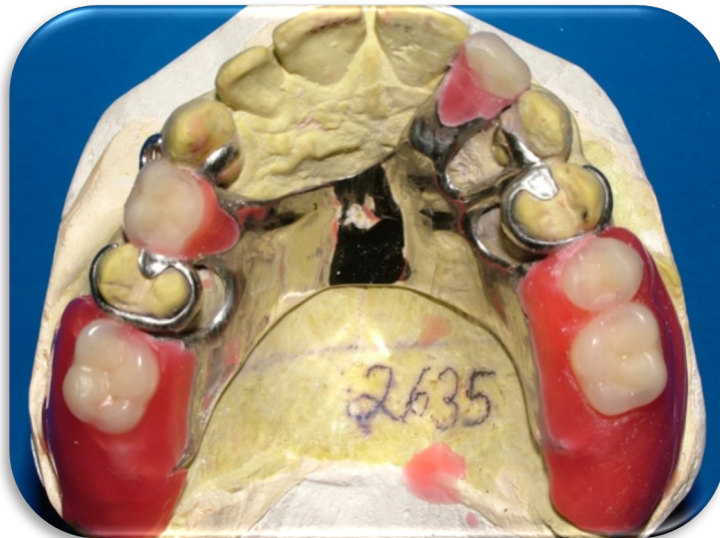- Resin-metal interfaces are referred to as finish lines
- Help lock the acrylic to the major connector
- Make the transition from the denture base and the framework.



should be sharp and well defined

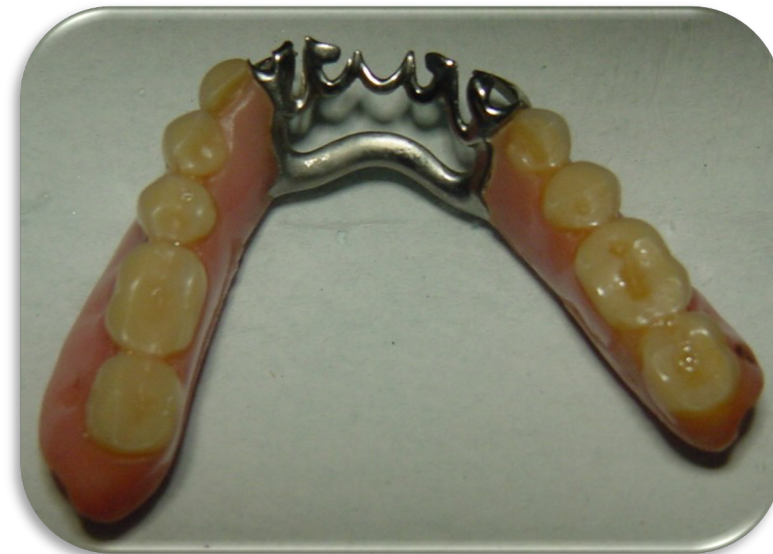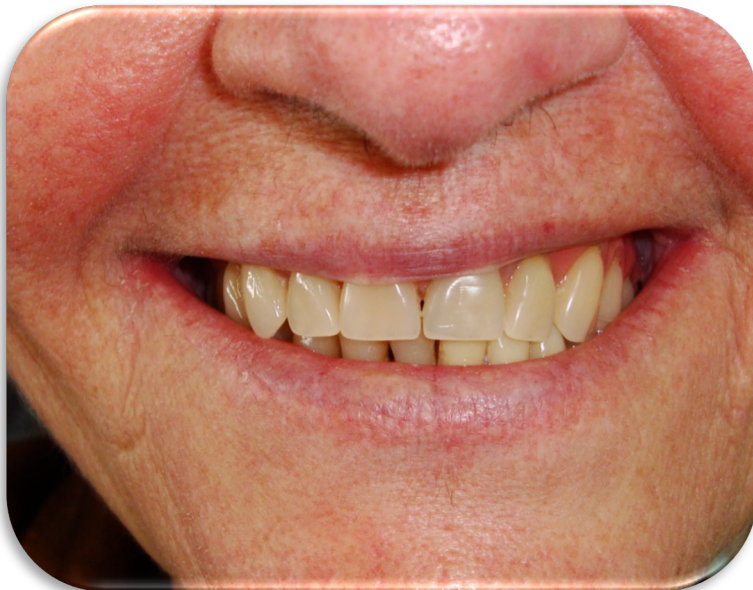Saddles

- Function:
 - Support artificial teeth and replace alveolar tissues
 - Receive and distribute occlusal forces to supporting structures (Kennedy Class I and II)
 - Aid retention: adhesion and cohesion



Saddles

- Function:
 - Stimulate the underlying tissues of the residual ridge (help to prevent alveolar ridge atrophy)
 - Prevent tooth migration
 - Add cosmetic effect



Denture Base



THE UNIVERSITY OF
**WESTERN
AUSTRALIA**



Oral Health Centre
of Western Australia

Types

- Metallic
- Acrylic

Denture Base



Types

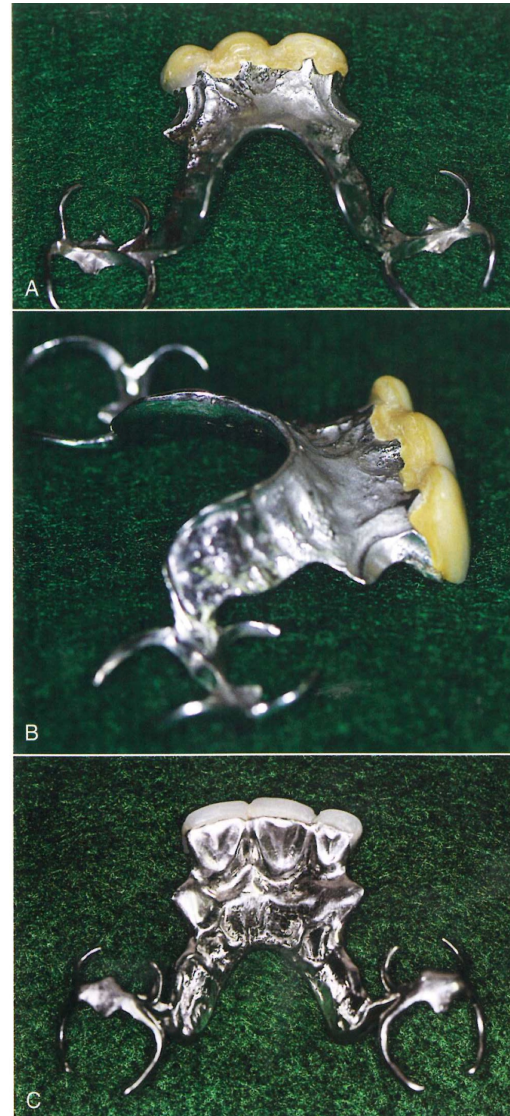
- Metallic

Advantage:

- Thermal stimulus
- Resistance
- Easy to clean
- Less volume

Disadvantages:

- Difficult to adjust
- Not able to relines
- Cost
- Weight



Denture Base



Types

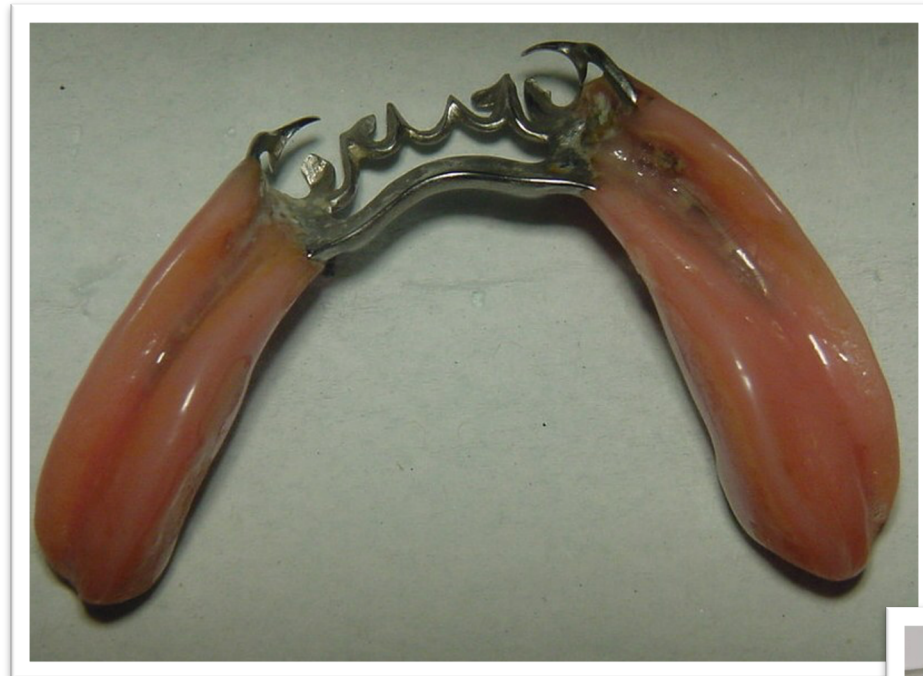- Acrylic

Advantage:

- Lighter
- Aesthetic
- Good adaptation
- Potential for future relining

Disadvantages:

- Distortion
- No thermal stimulus
- Hygiene





THE UNIVERSITY OF
**WESTERN
AUSTRALIA**



Oral Health Centre
of Western Australia

Thank you.