



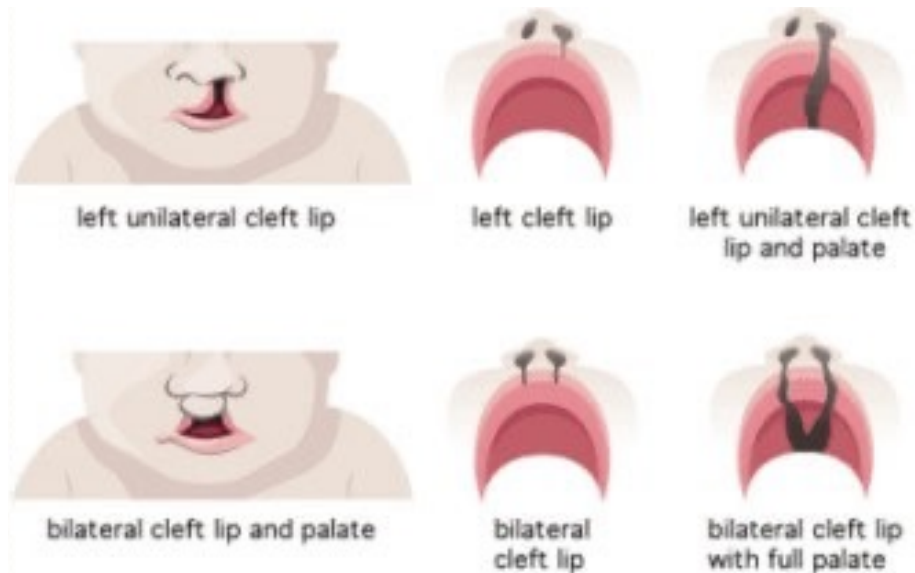
Oral Pathology

Oral Pathology

- **Developmental Conditions**
- Mucosal Lesions—Reactive
- Mucosal Lesions—Infections
- Mucosal Lesions—Immunologic Diseases
- Mucosal Lesions—Premalignant
- Mucosal Lesions—Malignant
- CT Tumors—Benign
- CT Tumors—Malignant
- Salivary Gland Diseases—Reactive
- Salivary Gland Diseases—Benign
- Salivary Gland Diseases—Malignant
- Lymphoid Neoplasms
- Odontogenic Cysts
- Odontogenic Tumors
- Bone Lesions—Fibro-Osseous
- Bone Lesions—Giant Cell
- Bone Lesions—Inflammatory
- Bone Lesions—Malignant
- Hereditary Conditions

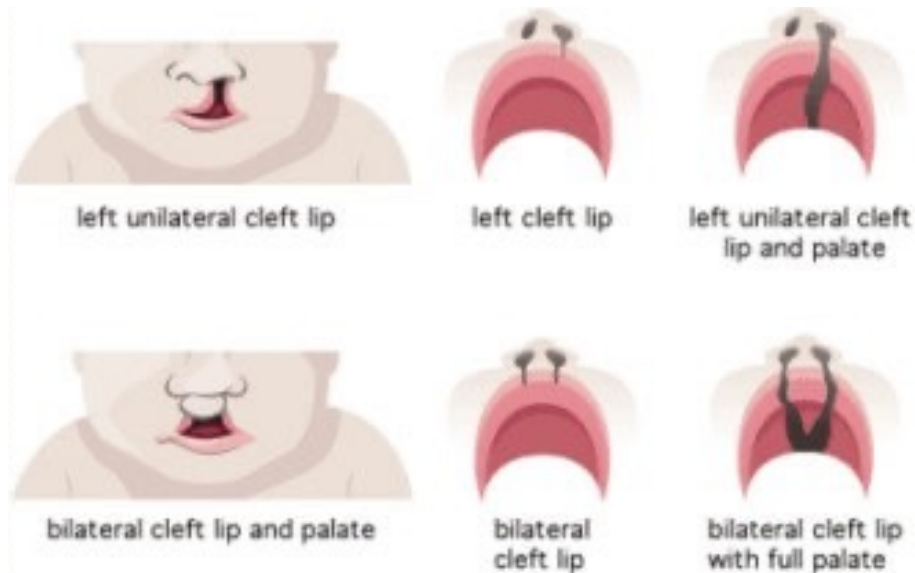
Cleft Lip

- Approximately 1 in 1000 births
- Unilateral (80%) or bilateral (20%)
- Lack of fusion between medial nasal process and maxillary process



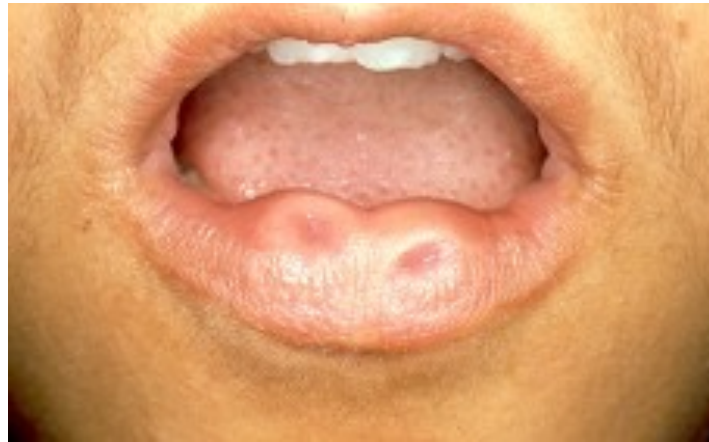Cleft Palate

- Approximately 1 in 2000 births
- Lack of fusion between palatal shelves



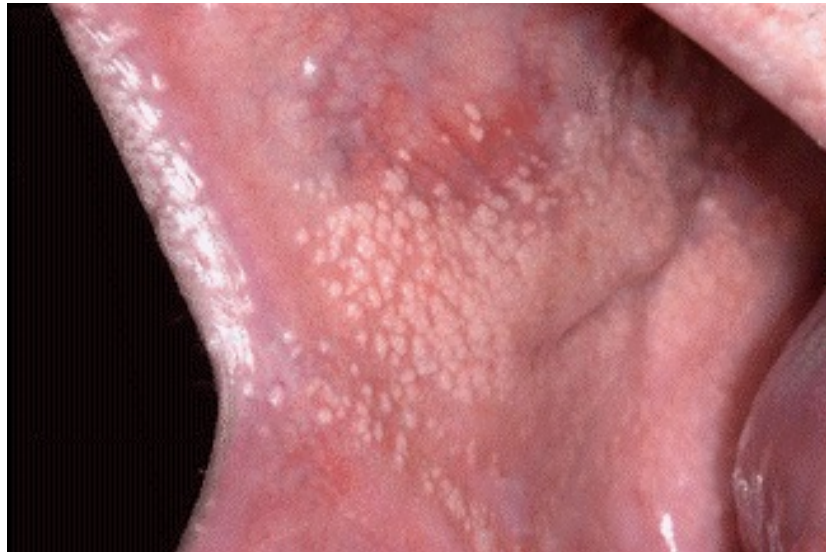Lip Pits

- Invaginations at commissures or near midline
- **Van der Woude Syndrome**= clefts + pits



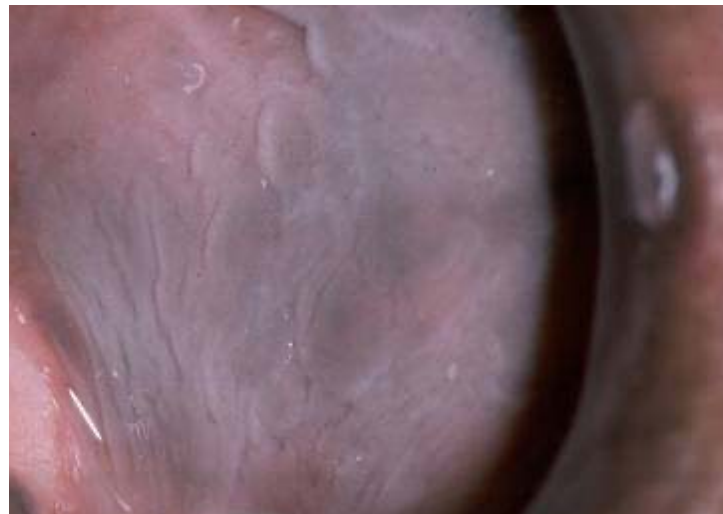
Fordyce Granules

- Ectopic sebaceous glands



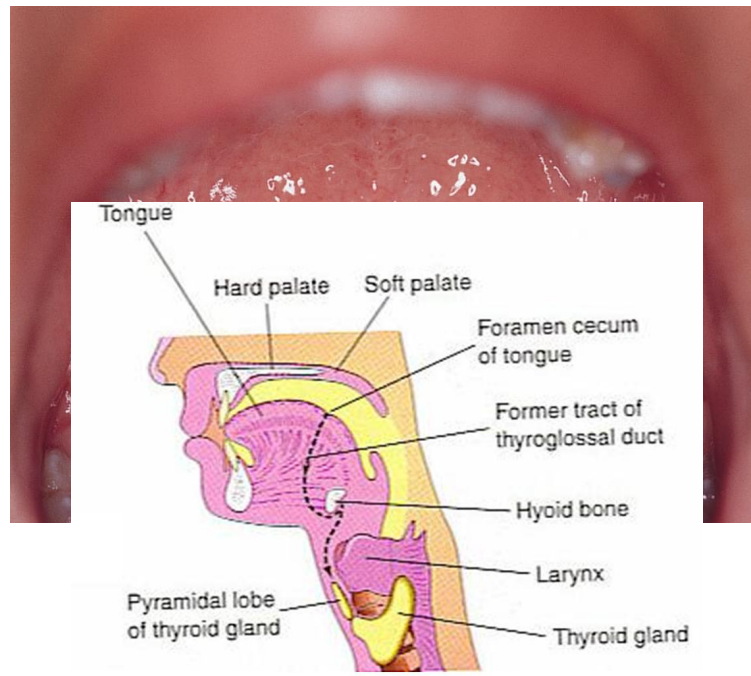
Leukoedema

- White or whitish-gray edematous lesion of buccal mucosa
- Dissipates when cheek is stretched



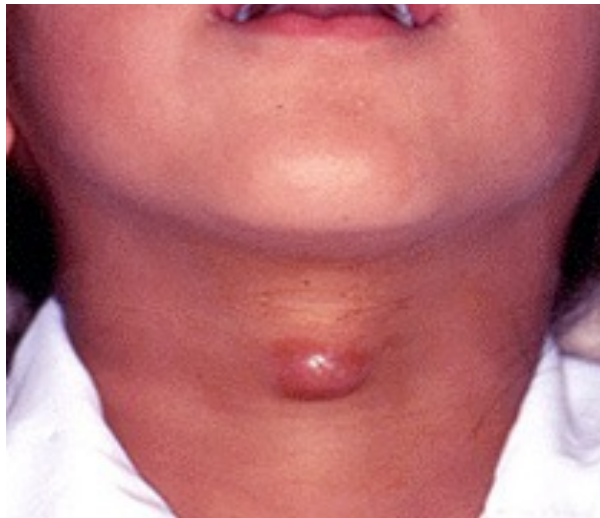Lingual Thyroid

- Thyroid tissue mass at midline base of tongue
- Located along embryonic path of thyroid descent



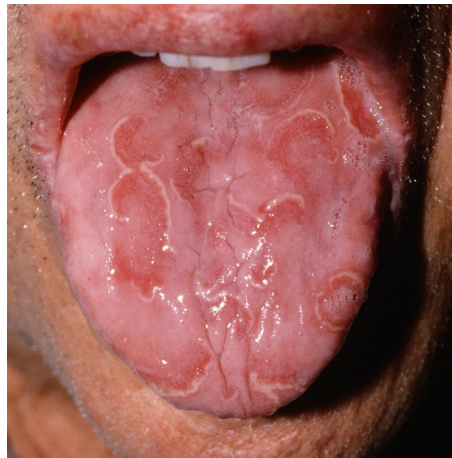Thyroglossal Duct Cyst

- **Midline** neck swelling
- Located along embryonic path of thyroid descent



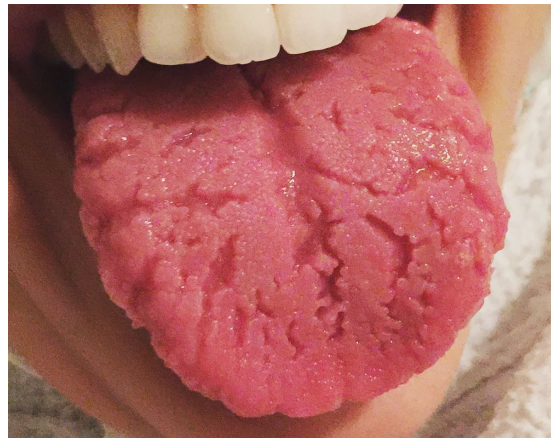
Geographic Tongue

- Also called benign migratory glossitis and erythema migrans
- White annular (ringed) lesions surrounding central red islands that migrate over time
- Occasionally hurt and burn
- Tx: none



Fissured Tongue

- Folds and furrows of tongue dorsum
- **Melkersson-Rosenthal Syndrome**= fissured tongue + granulomatous cheilitis + facial paralysis

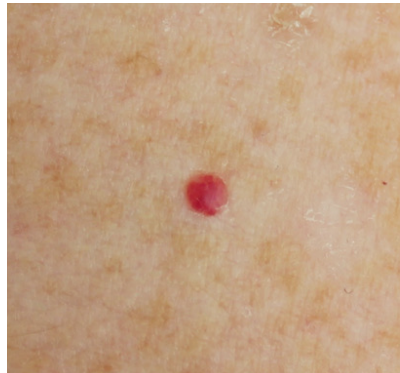

Angioma

- Tumors composed of blood vessels or lymph vessels

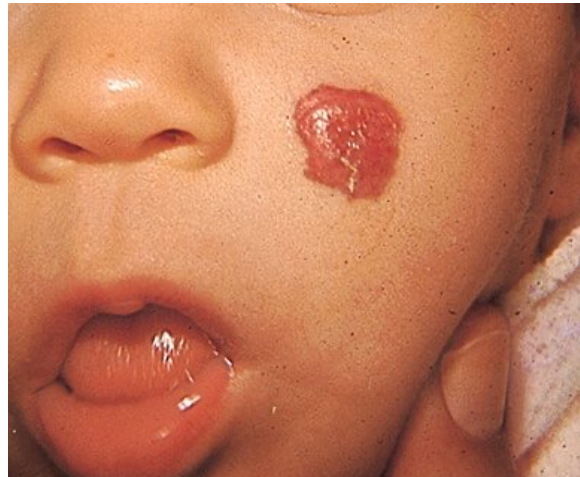Cherry Angioma

- Red mole



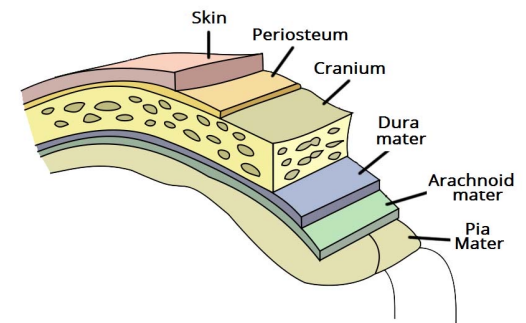
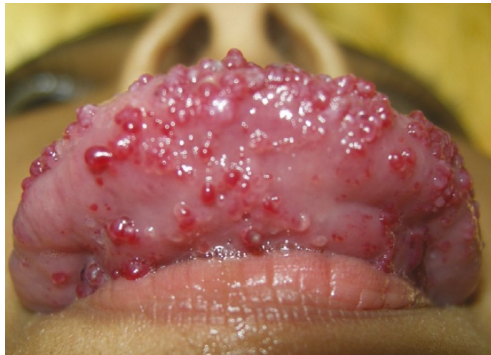Hemangioma

- Congenital focal proliferation of capillaries
- Most undergo involution, but persistent lesions are excised



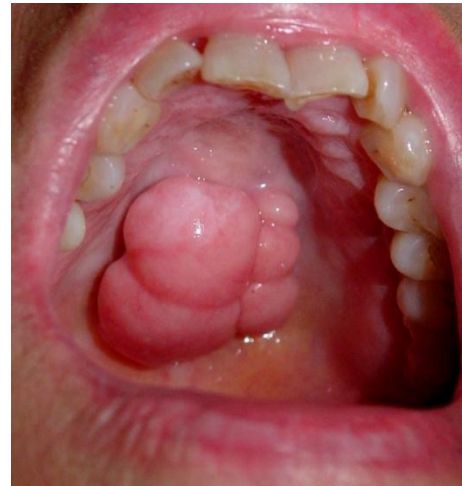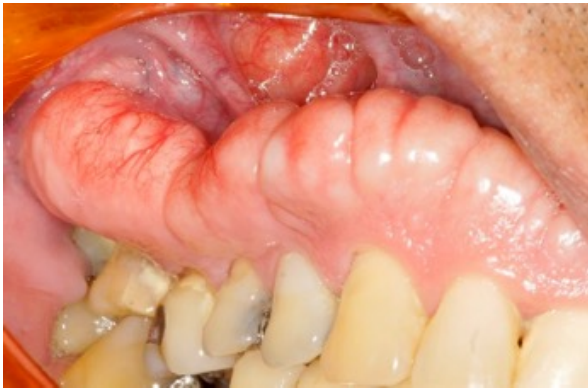Lymphangioma

- Congenital focal proliferation of lymph vessels
 - Oral lymphangiomas are very rare, purple spots on tongue
 - Called a cystic hygroma when occurs in the neck
- **Sturge-Weber Syndrome**= angiomas of leptomeninges (arachnoid and pia mater) + skin along the distribution of the trigeminal nerve



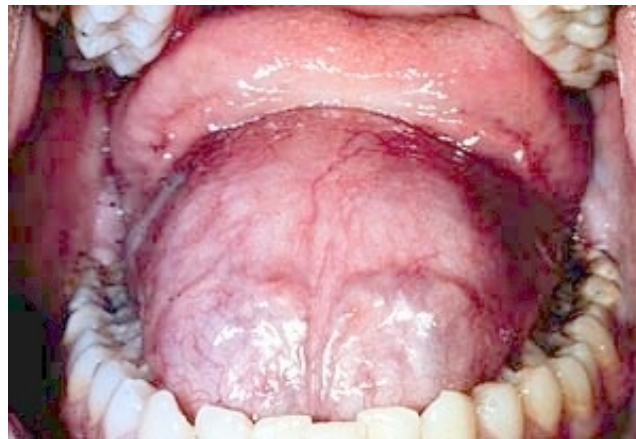
Exostoses/Tori

- Excessive cortical bone growth



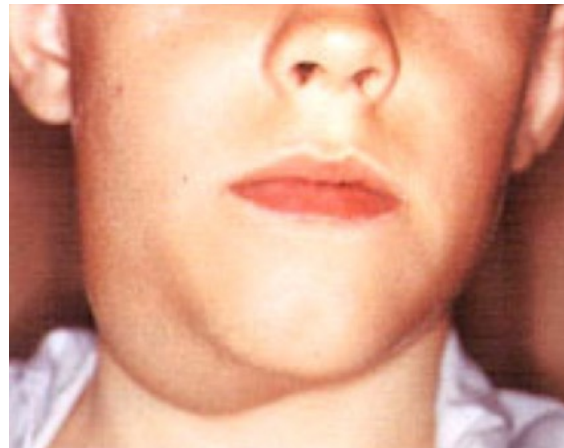Dermoid Cyst

- Mass in midline floor of mouth if above mylohyoid
- Mass in upper neck if below mylohyoid
- Contains adnexal structures like hair and sebaceous glands
- Doughy consistency



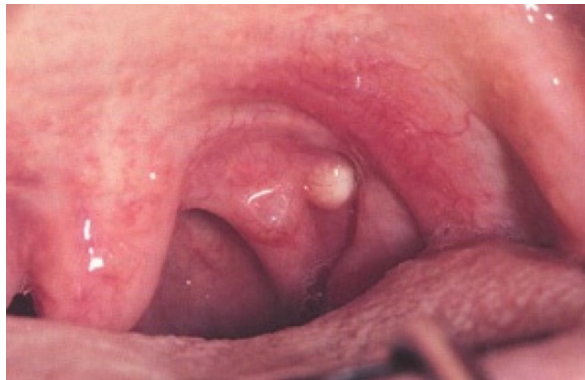Branchial Cyst

- **Lateral** neck swelling
- Epithelial cyst within lymph node of neck



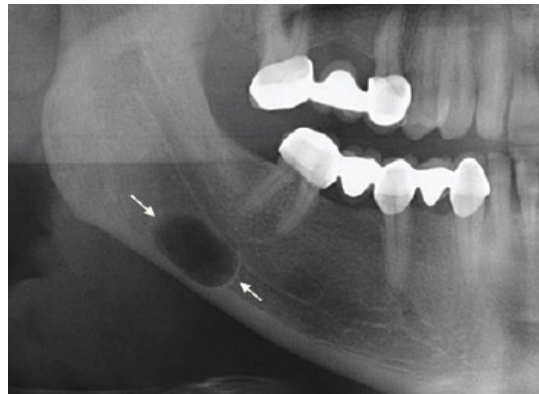
Oral Lymphoepithelial Cyst

- Epithelial cyst within lymphoid tissue of oral mucosa
- Palatine and lingual tonsils are common regions



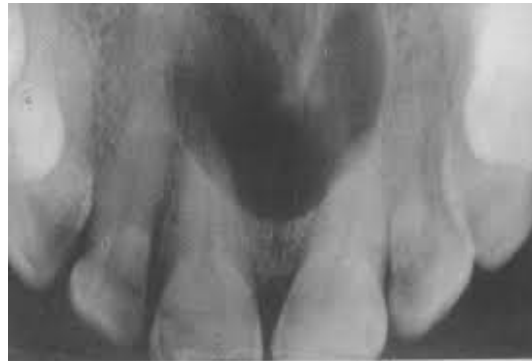Stafne Bone Defect

- Radiolucency in posterior mandible below mandibular canal
- Due to lingual concavity of jaw



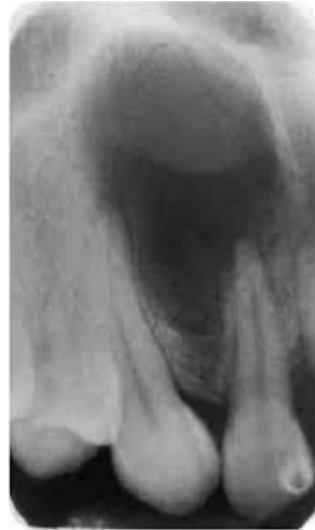Nasopalatine Duct Cyst

- Heart-shaped radiolucency in nasopalatine canal
- Caused by cystification of canal remnants
- Tx: excision



Globulomaxillary Lesion

- Clinical term denoting any radiolucency between maxillary canine and lateral incisor



Traumatic Bone Cyst

- Also called simple bone cyst and idiopathic bone cavity
- Large radiolucency scalloped around roots
- No epithelial lining (dead space) in mandible of teenagers
- Usually associated with jaw trauma
- Tx: aspirate to diagnosis, just monitor

