



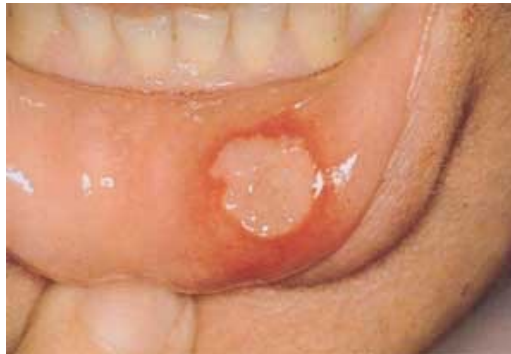Oral Pathology

Oral Pathology

- Developmental Conditions
- Mucosal Lesions—Reactive
- Mucosal Lesions—Infections
- **Mucosal Lesions—Immunologic Diseases**
- Mucosal Lesions—Premalignant
- Mucosal Lesions—Malignant
- CT Tumors—Benign
- CT Tumors—Malignant
- Salivary Gland Diseases—Reactive
- Salivary Gland Diseases—Benign
- Salivary Gland Diseases—Malignant
- Lymphoid Neoplasms
- Odontogenic Cysts
- Odontogenic Tumors
- Bone Lesions—Fibro-Osseous
- Bone Lesions—Giant Cell
- Bone Lesions—Inflammatory
- Bone Lesions—Malignant
- Hereditary Conditions

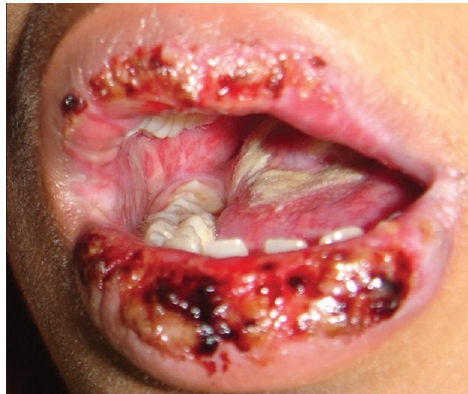Aphthous Ulcer

- “Canker sore”
- **Nonkeratinized**
- Minor → heal without scarring
- Major → heal with scarring
- **Sutton Disease**= another name for major form
- **Behcet’s Syndrome**= multisystem vasculitis that causes aphthous-type ulcers of oral and genital, and inflammation of eye
- Tx: corticosteroids for Behcet’s



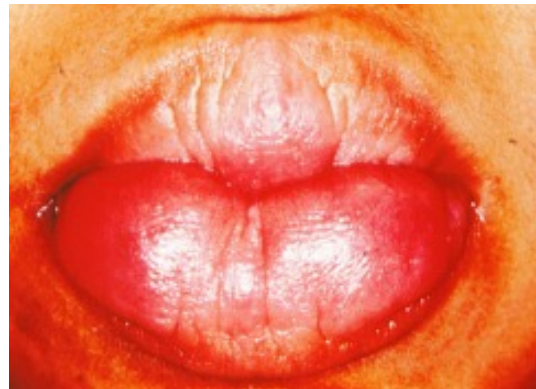Erythema Multiforme

- Often on lips but can occur anywhere on skin and mucosa
- Minor → herpes simplex hypersensitivity
- Major → drug sensitivity
- **Stevens-Johnson Syndrome**= another name for major form



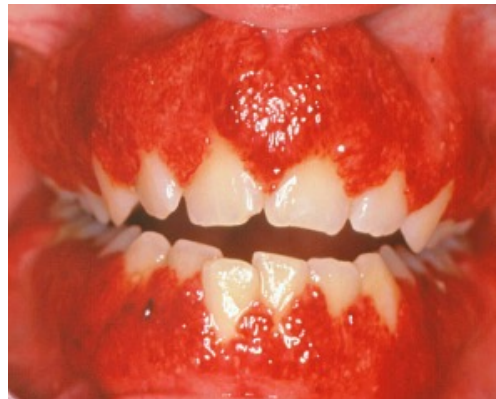Angioedema

- Allergic reaction to drug or food contact
- Diffuse swelling of lips, neck, or face
- Mediated by mast cell release of IgE and histamines
- Tx: antihistamines



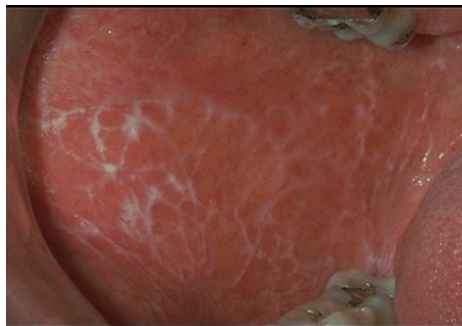Wegener's Granulomatosis

- Allergic reaction to inhaled antigen
- Strawberry gingivitis
- Tx: corticosteroids (prednisone) and cyclophosphamide



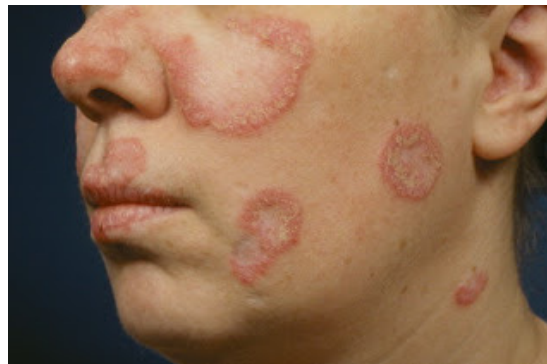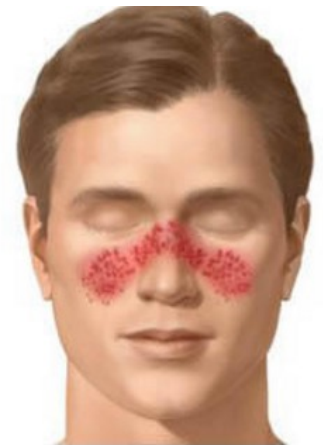Lichen Planus

- T lymphocytes target and destroy basal keratinocytes
- Basal zone vacuolization and **sawtooth rete pegs** secondary to this destruction is observed histologically
- Reticular → Wickham striae, more common
- Erosive → Wickham striae with red ulceration
- Tx: corticosteroids



Lupus Erythematosus

- Discoid chronic type
 - Disc-like lesions on facial skin
 - Oral lesions mimic erosive lichen planus
- Systemic acute type
 - Multiple organ involvement
 - Butterfly rash over bridge of nose
 - Autoantibodies (ANA test)
- Tx: corticosteroids

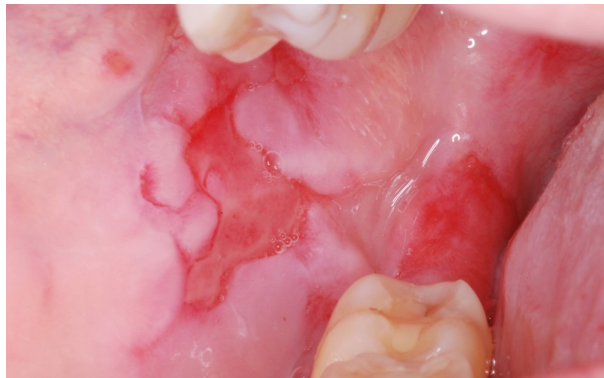

Scleroderma

- Hardening of skin and connective tissue
- Restricted opening and uniform widening of PDL space

Pemphigus Vulgaris

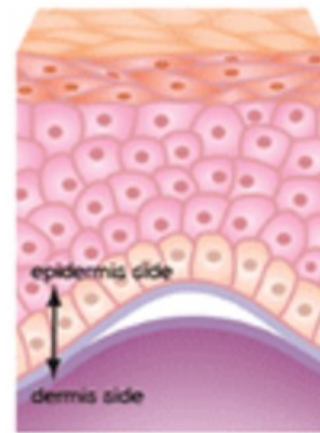
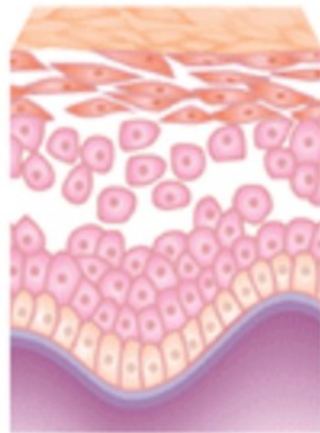
- Suprabasilar
- Autoantibodies against desmosomes
- Multiple painful ulcers preceded by bullae
- Positive Nikolsky's sign
- Tx: corticosteroids



Mucous Membrane Pemphigoid

- Subbasilar
- Autoantibodies against basement membrane
- Otherwise same as pemphigus

Pemphigus=u-bove



Pemphigoid= below