



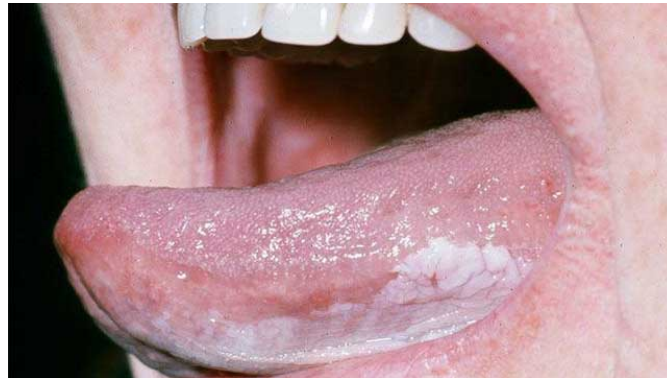Oral Pathology

Oral Pathology

- Developmental Conditions
- Mucosal Lesions—Reactive
- Mucosal Lesions—Infections
- Mucosal Lesions—Immunologic Diseases
- **Mucosal Lesions—Premalignant**
- Mucosal Lesions—Malignant
- CT Tumors—Benign
- CT Tumors—Malignant
- Salivary Gland Diseases—Reactive
- Salivary Gland Diseases—Benign
- Salivary Gland Diseases—Malignant
- Lymphoid Neoplasms
- Odontogenic Cysts
- Odontogenic Tumors
- Bone Lesions—Fibro-Osseous
- Bone Lesions—Giant Cell
- Bone Lesions—Inflammatory
- Bone Lesions—Malignant
- Hereditary Conditions

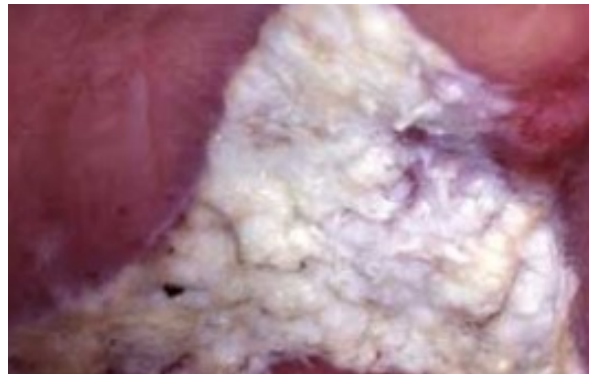
Leukoplakia

- Clinical description, not a diagnosis
- White patch that does not rub off
- Tx: biopsy mandatory



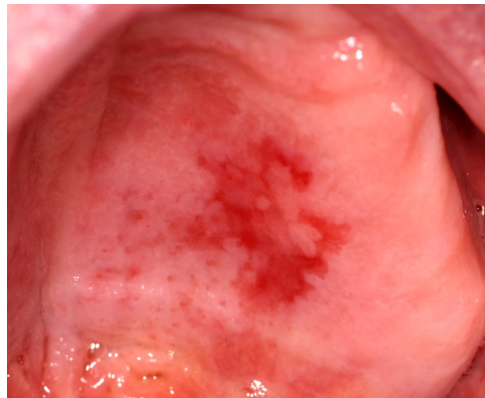
Proliferative Verrucous Leukoplakia

- Recurrent and warty
- May be associated with **HPV 16 and 18**
- High risk of malignant transformation to SCC or verrucous carcinoma



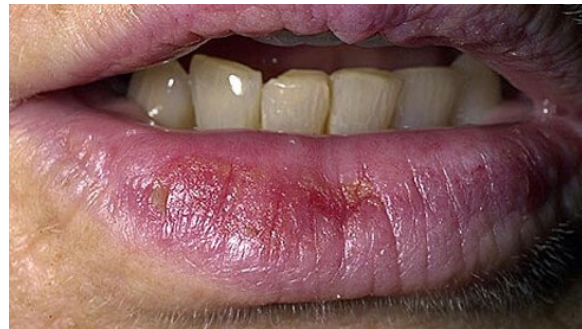Erythroplakia

- Clinical description, not a diagnosis
- Red patch
- Higher risk than leukoplakia
- Tx: biopsy mandatory



Actinic Cheilitis

- Actinic= solar
- Due to sun damage (UVB especially)



Smokeless Tobacco-Associated Lesion

- White mucosal change in vestibule due to direct effects of smokeless tobacco and additives

