



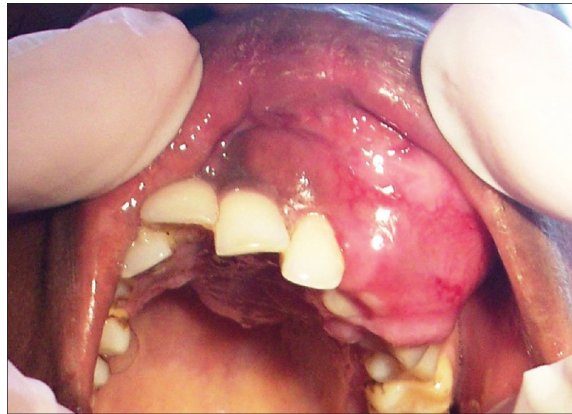# Oral Pathology

# Oral Pathology

- Developmental Conditions
- Mucosal Lesions—Reactive
- Mucosal Lesions—Infections
- Mucosal Lesions—Immunologic Diseases
- Mucosal Lesions—Premalignant
- Mucosal Lesions—Malignant
- CT Tumors—Benign
- **CT Tumors—Malignant**
- Salivary Gland Diseases—Reactive
- Salivary Gland Diseases—Benign
- Salivary Gland Diseases—Malignant
- Lymphoid Neoplasms
- Odontogenic Cysts
- Odontogenic Tumors
- Bone Lesions—Fibro-Osseous
- Bone Lesions—Giant Cell
- Bone Lesions—Inflammatory
- Bone Lesions—Malignant
- Hereditary Conditions

# Fibrosarcoma

- Malignant proliferation of **fibroblasts**

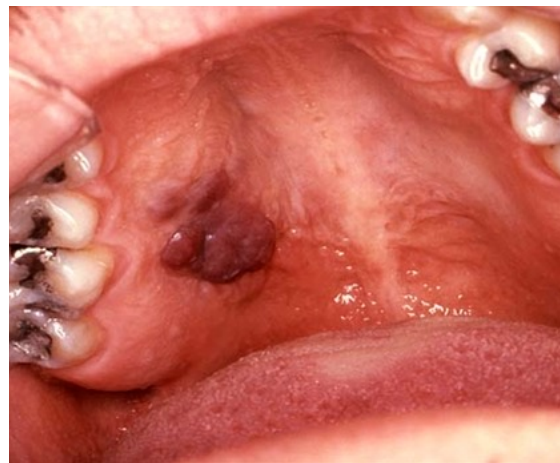


# Neurofibrosarcoma

- Also known as *malignant peripheral nerve sheath tumor*
- Malignant proliferation of **Schwann cells**

# Kaposi's Sarcoma

- Malignant proliferation of **endothelial cells**
- Caused by HHV8 and most commonly seen as a complication of AIDS
- Purple lesion



# Malignant CT Tumors

## Leiomyosarcoma

- Malignant proliferation of **smooth muscle cells**

## Benign CT Tumors

## Rhabdomyosarcoma

- Malignant proliferation of **skeletal muscle cells**

### Leiomyoma

- Neoplasm of **smooth muscle cells**

### Rhabdomyoma

- Neoplasm of **skeletal muscle cells**

### Lipoma

- Neoplasm of **fat cells**
- Most common on buccal mucosa

## Liposarcoma

- Malignant proliferation of **fat cells**

