



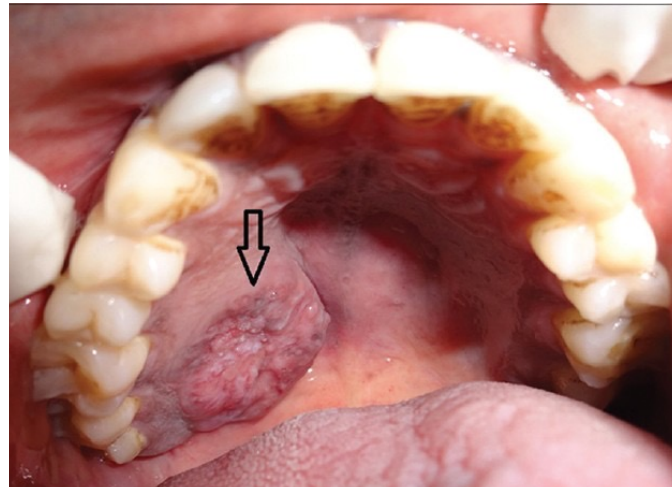
Oral Pathology

Oral Pathology

- Developmental Conditions
- Mucosal Lesions—Reactive
- Mucosal Lesions—Infections
- Mucosal Lesions—Immunologic Diseases
- Mucosal Lesions—Premalignant
- Mucosal Lesions—Malignant
- CT Tumors—Benign
- CT Tumors—Malignant
- Salivary Gland Diseases—Reactive
- Salivary Gland Diseases—Benign
- **Salivary Gland Diseases—Malignant**
- Lymphoid Neoplasms
- Odontogenic Cysts
- Odontogenic Tumors
- Bone Lesions—Fibro-Osseous
- Bone Lesions—Giant Cell
- Bone Lesions—Inflammatory
- Bone Lesions—Malignant
- Hereditary Conditions

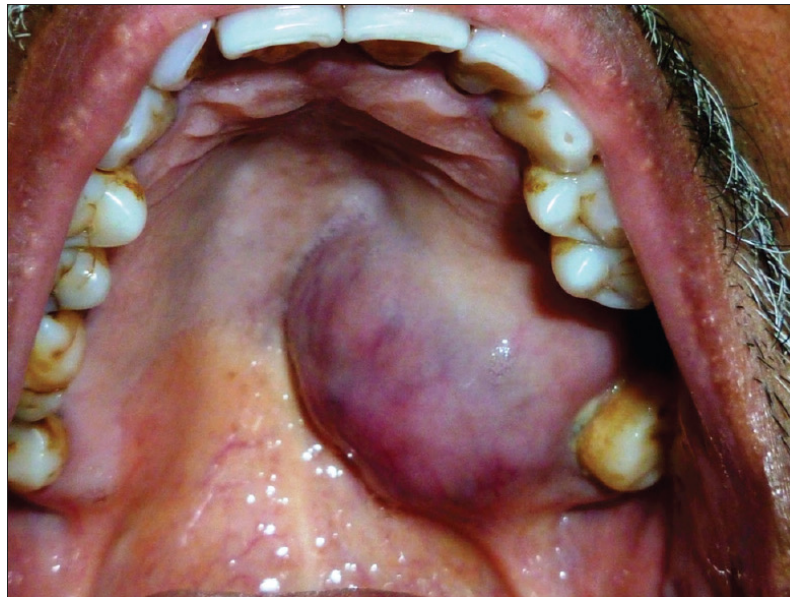Mucoepidermoid Carcinoma

- Most common salivary gland malignancy
- Composed of **mucous and epithelial cells**



Polymorphous Low-Grade Adenocarcinoma (PLGA)

- Second most common salivary gland malignancy for minor glands
- Adeno= prefix referring to gland



Adenoid Cystic Carcinoma

- Cribriform or Swiss cheese microscopic pattern
- 5-year survival is 70%, 15-year survival is 10%

