



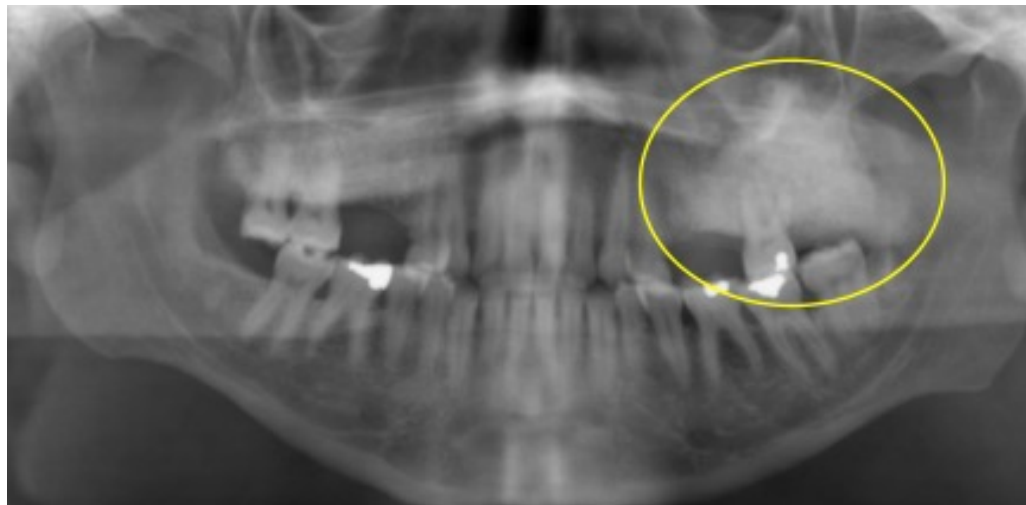
# Oral Pathology

# Oral Pathology

- Developmental Conditions
- Mucosal Lesions—Reactive
- Mucosal Lesions—Infections
- Mucosal Lesions—Immunologic Diseases
- Mucosal Lesions—Premalignant
- Mucosal Lesions—Malignant
- CT Tumors—Benign
- CT Tumors—Malignant
- Salivary Gland Diseases—Reactive
- Salivary Gland Diseases—Benign
- Salivary Gland Diseases—Malignant
- Lymphoid Neoplasms
- Odontogenic Cysts
- Odontogenic Tumors
- Bone Lesions—Fibro-Osseous
- Bone Lesions—Giant Cell
- Bone Lesions—Inflammatory
- **Bone Lesions—Malignant**
- Hereditary Conditions

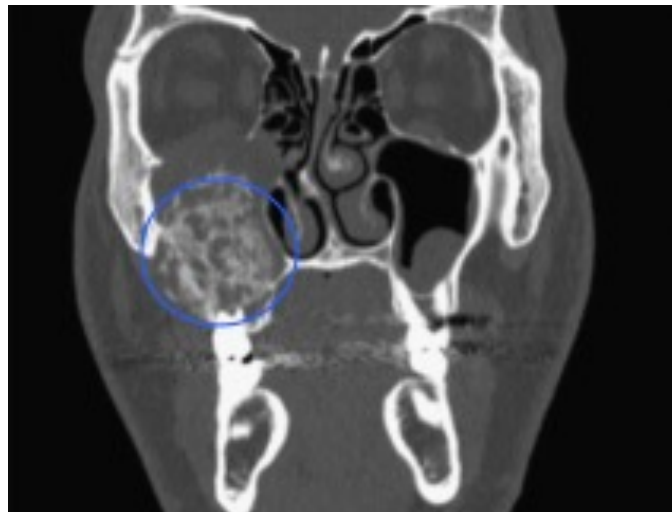# Osteosarcoma

- Sarcoma of jaws where **new bone** is produced by tumor cells
- Sunburst pattern
- 5-year survival is 25-40%
- Tx: resection and chemotherapy



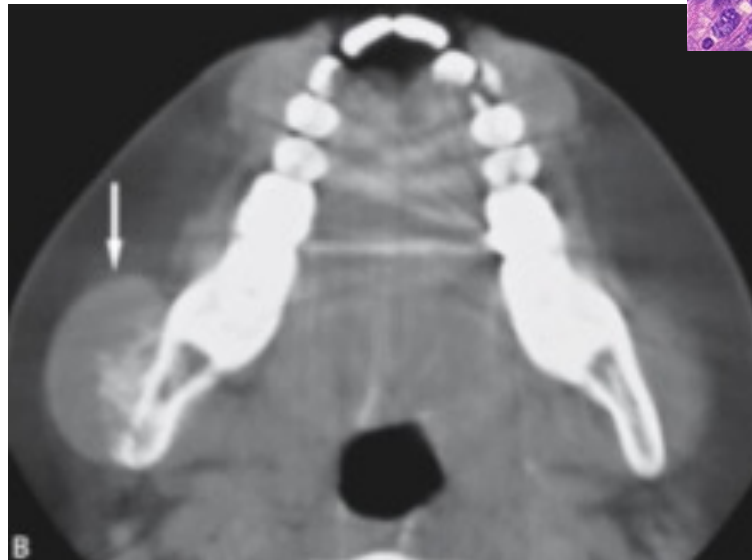
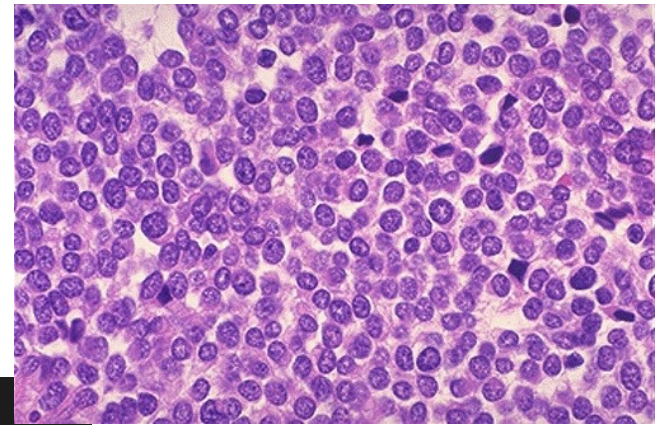
# Chondrosarcoma

- Sarcoma of jaws where **new cartilage** is produced by tumor cells
- Same presentation and treatment as previous
- More common involving condyle due to cartilaginous origin



# Ewing's Sarcoma

- Sarcoma of long bones involving “round cells”
- Seldom affects the jaws
- Affects children
- Involves swelling



# Metastatic Carcinoma

- Pain, swelling, and especially paresthesia
- Ill-defined changes are noted
- **Breast > lung > kidney > colon > prostate**

